

Long-term complications of Methiodal myelography

Author: BenchChem Technical Support Team. **Date:** December 2025

Compound of Interest

Compound Name: Methiodal

Cat. No.: B089705

[Get Quote](#)

Technical Support Center: Methiodal Myelography

This technical support center provides troubleshooting guides and frequently asked questions (FAQs) regarding the long-term complications associated with **Methiodal** myelography. The information is intended for researchers, scientists, and drug development professionals.

Frequently Asked Questions (FAQs)

Q1: What is the primary long-term complication associated with **Methiodal** myelography?

The primary and most significant long-term complication reported after myelography with **Methiodal** (**methiodal** sodium) is adhesive arachnoiditis.^{[1][2]} This condition involves inflammation and scarring of the arachnoid mater, one of the membranes that surround the brain and spinal cord, leading to the adhesion of nerve roots.

Q2: What are the symptoms of adhesive arachnoiditis?

Symptoms of adhesive arachnoiditis can be progressive and may develop years after the initial myelogram. They include:

- Chronic and severe back and limb pain
- Sensory disturbances, such as numbness or tingling

- Motor weakness in the lower limbs
- Bladder, bowel, and sexual dysfunction

Q3: How is adhesive arachnoiditis diagnosed after **Methiodal** myelography?

Diagnosis is typically made through magnetic resonance imaging (MRI), which can visualize the characteristic clumping and adhesion of nerve roots within the thecal sac.^{[3][4]}

Q4: Are there other reported long-term complications?

While adhesive arachnoiditis is the most emphasized long-term complication for older, oil-based and water-soluble ionic contrast agents like **Methiodal**, other potential long-term issues stemming from myelography in general can include chronic headaches, hydrocephalus, and syringomyelia (the formation of a fluid-filled cyst within the spinal cord).^{[5][6][7]}

Troubleshooting Guide

Issue: An experimental animal model subjected to **Methiodal** myelography is showing signs of progressive neurological deficit weeks to months after the procedure.

Possible Cause: Development of adhesive arachnoiditis.

Troubleshooting Steps:

- Behavioral Assessment: Systematically evaluate motor and sensory functions to quantify the neurological deficit.
- Imaging: Perform high-resolution MRI of the spine to look for signs of nerve root clumping, dural sac constriction, or loculations of cerebrospinal fluid (CSF), which are indicative of arachnoiditis.
- Histopathological Analysis: In terminal studies, careful dissection and histological examination of the spinal cord and meninges can confirm the presence of fibrosis and adhesive changes consistent with arachnoiditis.

Quantitative Data Summary

The following table summarizes the incidence of adhesive arachnoiditis following myelography with various contrast agents, including **Methiodal** sodium.

Contrast Agent	Number of Cases with Adhesive Arachnoiditis	Total Number of Cases	Incidence Rate
Methiodal sodium	5	46	10.9%
Iothalamate meglumine	24	96	25.0%
Iocarmate meglumine	7	12	58.3%
Iodophendylate (Myodil/Pantopaque)	7	10	70.0%
Metrizamide	0	90	0.0%

Data extracted from a study analyzing repeat myelography films for signs of meningeal changes.[\[2\]](#)

Experimental Protocols

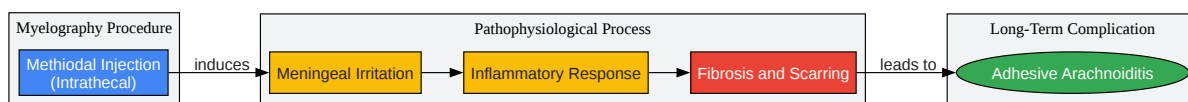
Protocol: Magnetic Resonance Imaging (MRI) for the Detection of Adhesive Arachnoiditis

This protocol outlines a general procedure for using MRI to diagnose adhesive arachnoiditis in a research setting.

- **Animal Preparation:** Anesthetize the subject according to approved institutional protocols. Position the animal on the MRI scanner bed, ensuring the spine is aligned with the imaging coil.
- **Imaging Sequences:**
 - **T2-weighted sagittal and axial sequences:** These are crucial for visualizing the cerebrospinal fluid and identifying nerve root adhesions. Look for:
 - Central clumping of nerve roots (Type 1 arachnoiditis).[\[3\]](#)

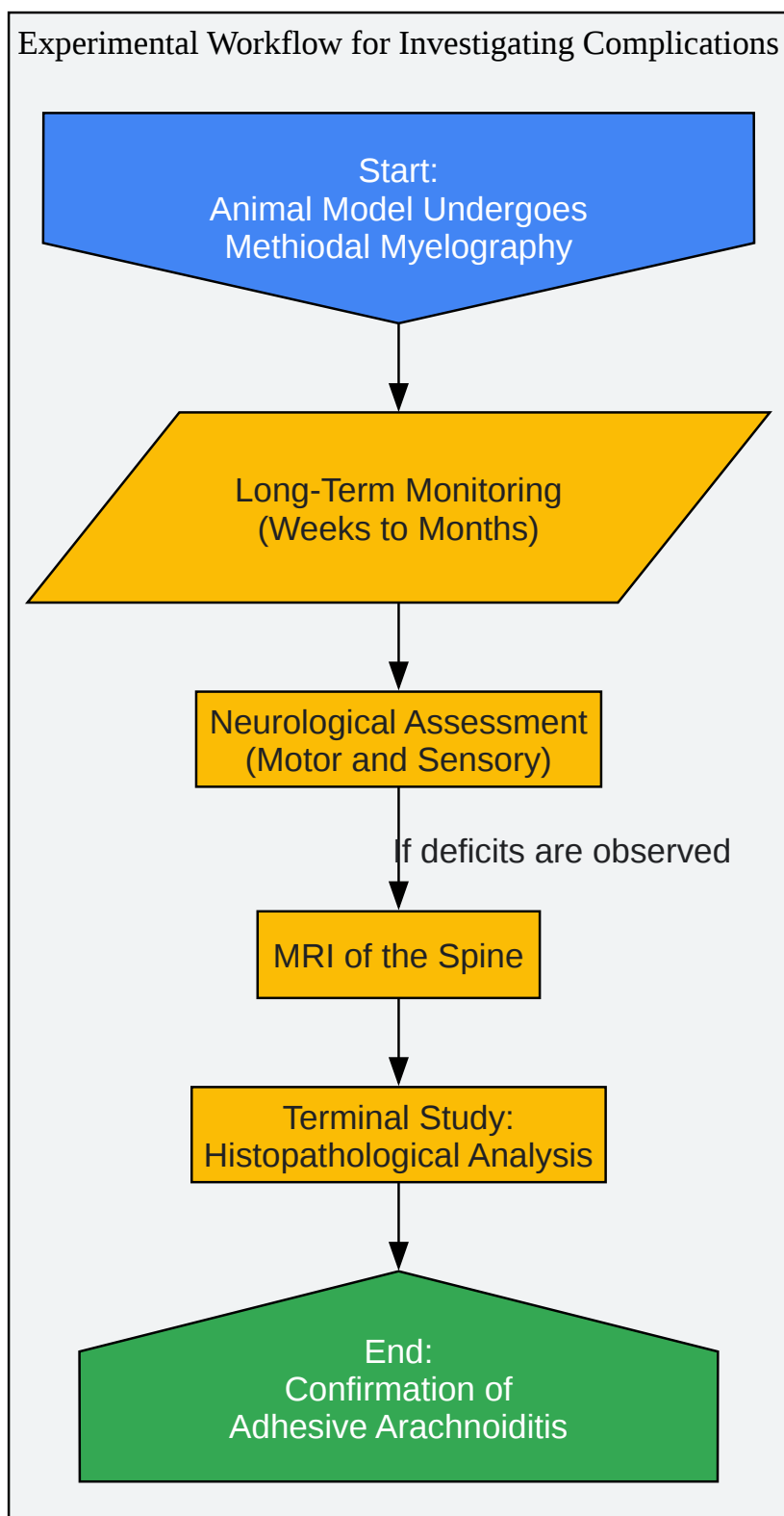
- Peripheral adhesion of nerve roots to the theca (Type 2 arachnoiditis).[3]
- Complete opacification of the thecal sac by clumped nerve roots (Type 3 arachnoiditis). [3]
- T1-weighted sagittal and axial sequences: These can provide anatomical detail and may be performed pre- and post-administration of a gadolinium-based contrast agent to assess for inflammation, although chronic arachnoiditis may not consistently show enhancement.
- Image Analysis: A radiologist experienced in neuroradiology should interpret the images, specifically looking for the displacement and clumping of nerve roots, and the obliteration of the subarachnoid space.

Visualizations



[Click to download full resolution via product page](#)

Caption: Logical pathway from **Methiodal** injection to adhesive arachnoiditis.



[Click to download full resolution via product page](#)

Caption: Experimental workflow for identifying **Methiodal**-induced arachnoiditis.

Need Custom Synthesis?

BenchChem offers custom synthesis for rare earth carbides and specific isotopic labeling.

Email: info@benchchem.com or [Request Quote Online](#).

References

- 1. Adhesive arachnoiditis following lumbar myelography - PubMed [pubmed.ncbi.nlm.nih.gov]
- 2. Late meningeal effects of myelographic contrast media with special reference to metrizamide - PubMed [pubmed.ncbi.nlm.nih.gov]
- 3. Patterns of chronic adhesive arachnoiditis following Myodil myelography: the significance of spinal canal stenosis and previous surgery - PubMed [pubmed.ncbi.nlm.nih.gov]
- 4. researchgate.net [researchgate.net]
- 5. Thoracic arachnoiditis, arachnoid cyst and syrinx formation secondary to myelography with Myodil, 30 years previously - PMC [pmc.ncbi.nlm.nih.gov]
- 6. Intraspinal arachnoiditis and hydrocephalus after lumbar myelography using methylglucamine iocarmate - PMC [pmc.ncbi.nlm.nih.gov]
- 7. Intracranial iodinated contrast medium deposits 50 years following a previous myelography: A case report and literature review - PMC [pmc.ncbi.nlm.nih.gov]
- To cite this document: BenchChem. [Long-term complications of Methiodal myelography]. BenchChem, [2025]. [Online PDF]. Available at: [https://www.benchchem.com/product/b089705#long-term-complications-of-methiodal-myelography]

Disclaimer & Data Validity:

The information provided in this document is for Research Use Only (RUO) and is strictly not intended for diagnostic or therapeutic procedures. While BenchChem strives to provide accurate protocols, we make no warranties, express or implied, regarding the fitness of this product for every specific experimental setup.

Technical Support: The protocols provided are for reference purposes. Unsure if this reagent suits your experiment? [[Contact our Ph.D. Support Team for a compatibility check](#)]

Need Industrial/Bulk Grade? [Request Custom Synthesis Quote](#)

BenchChem

Our mission is to be the trusted global source of essential and advanced chemicals, empowering scientists and researchers to drive progress in science and industry.

Contact

Address: 3281 E Guasti Rd
Ontario, CA 91761, United States
Phone: (601) 213-4426
Email: info@benchchem.com