

Technical Support Center: Troubleshooting EDTA-Induced Changes in Cell Morphology

Author: BenchChem Technical Support Team. **Date:** December 2025

Compound of Interest

Compound Name: Ethylenediaminetetraacetate

Cat. No.: B8759487

[Get Quote](#)

Welcome to the Technical Support Center. This resource is designed for researchers, scientists, and drug development professionals to address common issues related to the use of Ethylenediaminetetraacetic acid (EDTA) as an anticoagulant and its effects on cell morphology during analysis.

Frequently Asked Questions (FAQs)

Q1: Why is EDTA a preferred anticoagulant for hematological analysis?

A1: EDTA is favored for hematological testing because it effectively prevents blood clotting by chelating calcium ions (Ca^{2+}), which are essential for the coagulation cascade.[1][2] This method of anticoagulation helps in preserving the cellular components and morphology of blood cells better than some other anticoagulants.[2]

Q2: What are the most common morphological changes observed in blood cells due to EDTA?

A2: The most frequently reported changes include:

- Platelets: EDTA can induce in-vitro aggregation or clumping, a phenomenon known as pseudothrombocytopenia.[1][3] This can lead to a falsely low platelet count by automated analyzers.
- Red Blood Cells (Erythrocytes): Changes such as crenation (the formation of echinocytes) and an increase in spherocytes can be observed, particularly with prolonged storage.

- White Blood Cells (Leukocytes): Neutrophils may exhibit cytoplasmic vacuolization, fragmentation, and degranulation. Monocytes can also show vacuolization.

Q3: How quickly do these morphological changes appear in an EDTA-anticoagulated sample?

A3: Morphological alterations can begin within 30 minutes of blood collection in EDTA tubes. For comprehensive morphological assessment of leukocytes, it is recommended to prepare blood smears within 8 hours of sampling. A manual differential leukocyte count can be reliably performed on smears from EDTA blood for up to 12 hours.[\[4\]](#)

Q4: Can the concentration of EDTA affect cell morphology?

A4: Yes, an inappropriate concentration of EDTA can lead to more pronounced morphological artifacts. It is crucial to ensure the correct blood-to-anticoagulant ratio as specified by the collection tube manufacturer.

Q5: Are there any alternatives to EDTA that have less impact on cell morphology?

A5: Yes, other anticoagulants can be used, each with its own set of advantages and disadvantages:

- Sodium Citrate: Often used as an alternative, especially when EDTA-induced platelet clumping is suspected.
- Heparin: This anticoagulant works by inhibiting thrombin and is another common alternative. However, it may not be ideal for preserving leukocyte morphology for differential counts.

Troubleshooting Guides

Issue 1: Falsely Low Platelet Count (Pseudothrombocytopenia)

Symptoms:

- Automated hematology analyzer reports a low platelet count.
- Microscopic examination of a peripheral blood smear reveals platelet clumps or aggregates.

[\[3\]](#)

- The patient's clinical condition does not correlate with the reported thrombocytopenia.

Possible Causes:

- EDTA-dependent anti-platelet autoantibodies in the patient's plasma that cause platelet agglutination in vitro.[3]

Troubleshooting Steps:

- **Visual Inspection:** Prepare and examine a peripheral blood smear from the EDTA-anticoagulated sample. Look for platelet clumps, especially at the feathered edge of the smear.
- **Recollection with a Different Anticoagulant:** Collect a new blood sample in a tube containing an alternative anticoagulant such as sodium citrate (blue top tube) or heparin (green top tube).
- **Immediate Analysis:** If recollection is not immediately possible, warming the EDTA tube to 37°C for a short period might help in disaggregating the platelets before analysis.
- **Manual Platelet Count:** If platelet clumping is observed, a manual platelet count from a freshly prepared smear can provide a more accurate estimation.

Issue 2: Artifactual Changes in Red and White Blood Cell Morphology

Symptoms:

- Observation of echinocytes (crenated RBCs), spherocytes, or RBC swelling.[5][6]
- Neutrophils show cytoplasmic vacuoles, degranulation, or nuclear changes.
- Monocyte vacuolization.

Possible Causes:

- Prolonged storage of the blood sample in EDTA.

- Incorrect blood-to-anticoagulant ratio.
- Suboptimal storage temperature.

Troubleshooting Steps:

- **Check Sample Age:** Whenever possible, analyze blood samples as soon as possible after collection. For morphological studies, preparing smears within a few hours is ideal.
- **Ensure Proper Tube Filling:** Always fill blood collection tubes to the indicated level to maintain the correct anticoagulant concentration.
- **Use Fresh Smears:** For critical morphological evaluations, preparing a smear from a fresh capillary blood sample (finger prick) without any anticoagulant can serve as a baseline.
- **Consider Alternative Anticoagulants:** If consistent artifacts are observed, collecting samples in sodium citrate or heparin might be beneficial for specific analyses, keeping in mind their own potential interferences.

Data Presentation

Table 1: Comparison of Leukocyte Parameters in Dromedary Camels with Different Anticoagulants

Parameter	EDTA	Lithium Heparin	p-value
Total White Blood Cells (x10 ³ /μL)	13.8 ± 0.3	11.4 ± 1.7	< 0.05
Neutrophils (%)	66.5 ± 1.1	59.7 ± 2.0	< 0.05
Lymphocytes (%)	27.0 ± 1.0	34.9 ± 2.0	< 0.05
Monocytes (%)	5.2 ± 0.4	4.0 ± 0.5	> 0.05
Eosinophils (%)	1.3 ± 0.2	1.4 ± 0.2	> 0.05
Neutrophil to Lymphocyte Ratio	2.6 ± 0.2	1.8 ± 0.2	< 0.05
Necrotic Neutrophils (%)	Lower	Higher	< 0.05

Data adapted from a study on dromedary camels.^[7] Values are presented as mean ± standard deviation.

Table 2: Time-Dependent Morphological Changes in Blood Cells Stored in EDTA at Room Temperature

Time after Collection	Red Blood Cell Changes	White Blood Cell Changes	Platelet Changes
0 hours	Normal morphology	Normal morphology	Normal morphology
~1-2 hours	Significant increase in crenated cells, acanthocytes, and bite cells.[6]	Significant nuclear degeneration and cytoplasmic changes. [6]	Swelling begins.[1]
>8 hours	Progressive changes	Significant increase in morphological changes, making comprehensive assessment unreliable.[4]	Aggregation may occur.[1]
24 hours	Maximum cellular distortion.[6]	Widespread artifacts	Significant changes

Experimental Protocols

Protocol 1: Preparation of a Peripheral Blood Smear

This protocol is essential for the microscopic evaluation of cell morphology.

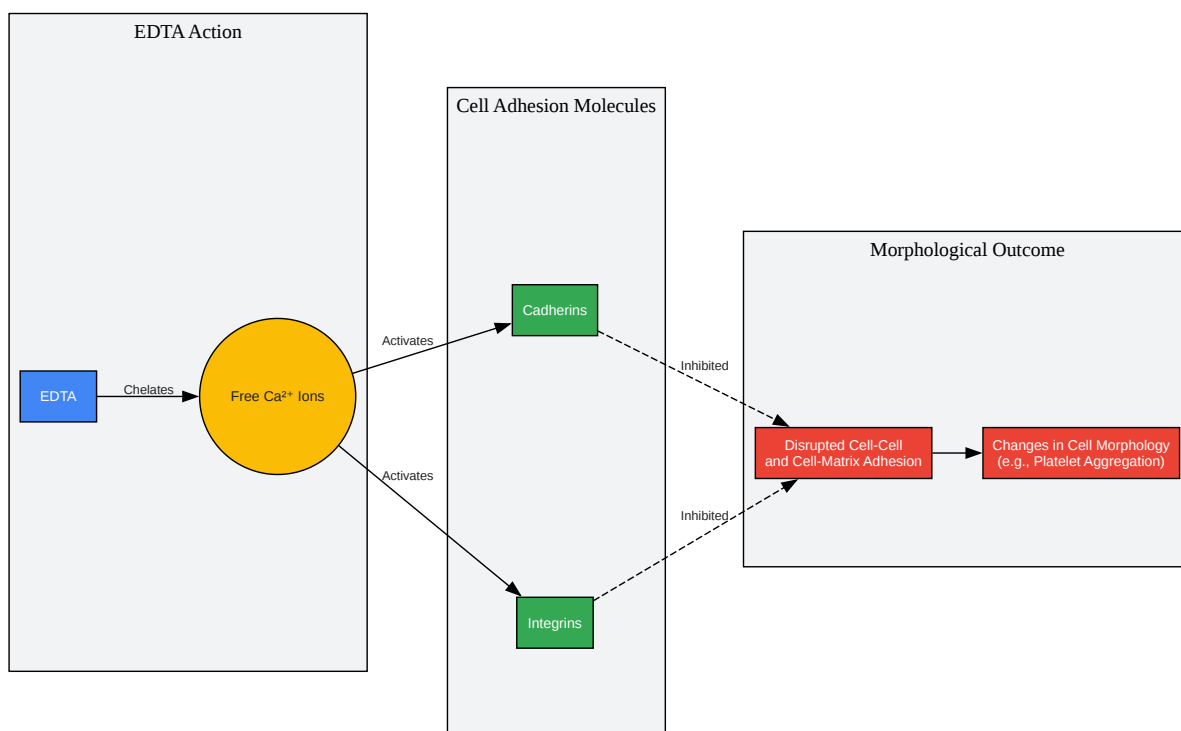
Materials:

- Glass microscope slides
- Spreader slide
- Whole blood sample (anticoagulated or fresh)
- Pipette or capillary tube
- Staining reagents (e.g., Wright-Giemsa stain)
- Microscope

Procedure:

- Place a small drop of blood (approximately 2-3 μL) onto a clean glass slide, about 1-2 cm from one end.
- Hold a spreader slide at a 30-45 degree angle and bring it back to make contact with the blood drop.
- Allow the blood to spread along the edge of the spreader slide.
- In a smooth and rapid motion, push the spreader slide forward to the other end of the slide, creating a thin, even smear with a feathered edge.
- Allow the blood smear to air dry completely.
- Fix the smear with methanol for 1-2 minutes and allow it to air dry.
- Stain the smear according to the desired staining protocol (e.g., Wright-Giemsa).
- Rinse the slide gently with buffered water and allow it to air dry before microscopic examination.

Mandatory Visualizations



[Click to download full resolution via product page](#)

Caption: Mechanism of EDTA-induced changes in cell morphology.

Caption: Troubleshooting workflow for EDTA-related cell morphology issues.

Need Custom Synthesis?

BenchChem offers custom synthesis for rare earth carbides and specific isotopic labeling.

Email: info@benchchem.com or [Request Quote Online](#).

References

- 1. academicmed.org [academicmed.org]
- 2. bcsrj.com [bcsrj.com]

- 3. researchgate.net [researchgate.net]
- 4. Frontiers | Comparison Between K3EDTA and Lithium Heparin as Anticoagulant to Isolate Bovine Granulocytes From Blood [frontiersin.org]
- 5. fisheriesjournal.com [fisheriesjournal.com]
- 6. The effects of anticoagulants on hematological indices and blood cell morphology of common carp (Cyprinus carpio L.) - PubMed [pubmed.ncbi.nlm.nih.gov]
- 7. The Impact of Anticoagulation Agent on the Composition and Phenotype of Blood Leukocytes in Dromedary Camels - PMC [pmc.ncbi.nlm.nih.gov]
- To cite this document: BenchChem. [Technical Support Center: Troubleshooting EDTA-Induced Changes in Cell Morphology]. BenchChem, [2025]. [Online PDF]. Available at: [https://www.benchchem.com/product/b8759487#issues-with-edta-causing-changes-in-cell-morphology-during-analysis]

Disclaimer & Data Validity:

The information provided in this document is for Research Use Only (RUO) and is strictly not intended for diagnostic or therapeutic procedures. While BenchChem strives to provide accurate protocols, we make no warranties, express or implied, regarding the fitness of this product for every specific experimental setup.

Technical Support: The protocols provided are for reference purposes. Unsure if this reagent suits your experiment? [[Contact our Ph.D. Support Team for a compatibility check](#)]

Need Industrial/Bulk Grade? [Request Custom Synthesis Quote](#)

BenchChem

Our mission is to be the trusted global source of essential and advanced chemicals, empowering scientists and researchers to drive progress in science and industry.

Contact

Address: 3281 E Guasti Rd
Ontario, CA 91761, United States
Phone: (601) 213-4426
Email: info@benchchem.com