

# Common artifacts in Diatrizoate sodium I 131 imaging and solutions

**Author:** BenchChem Technical Support Team. **Date:** December 2025

## Compound of Interest

Compound Name: Diatrizoate sodium I 131

Cat. No.: B085109

[Get Quote](#)

## Technical Support Center: Diatrizoate Sodium and I-131 Imaging

Disclaimer: The combination of Diatrizoate Sodium and Iodine-131 (I-131) for imaging is not a standard clinical procedure. Diatrizoate sodium is a high-osmolar iodinated contrast medium used for X-ray-based imaging (like CT scans), while I-131 is a radioisotope used in nuclear medicine for thyroid imaging and therapy.<sup>[1][2]</sup> This guide addresses common artifacts in I-131 imaging and potential complications arising from prior administration of iodinated contrast agents like Diatrizoate Sodium.

## Frequently Asked Questions (FAQs)

Q1: What is the primary interference of Diatrizoate Sodium with I-131 imaging?

A1: The fundamental issue is iodine competition. Diatrizoate Sodium contains a large amount of stable (non-radioactive) iodine.<sup>[3][4][5][6]</sup> If administered prior to an I-131 scan, this stable iodine will flood the body's iodine pool. Tissues that normally take up iodine, such as the thyroid gland or thyroid cancer cells, will become saturated with the stable iodine from the contrast agent. This saturation competitively blocks the uptake of the radioactive I-131 tracer, potentially leading to a false-negative scan or an underestimation of disease extent.<sup>[3][7]</sup>

Q2: How long should a patient wait for an I-131 scan after receiving Diatrizoate Sodium?

A2: The waiting period can be substantial, as it takes time for the excess stable iodine to clear from the body. Guidelines often recommend a waiting period of at least 2 to 3 months.<sup>[3][4][5][6][7]</sup> However, the exact duration can vary depending on patient-specific factors like renal function. Monitoring urinary iodine levels can be a useful tool to determine when the body's iodine pool has returned to a baseline level suitable for I-131 imaging.<sup>[3][5]</sup>

Q3: Can Diatrizoate Sodium directly cause artifacts on a gamma camera image?

A3: Diatrizoate Sodium itself is not radioactive and will not be directly visualized by a gamma camera. However, its high density can cause attenuation artifacts if a SPECT/CT is performed. In this hybrid imaging technique, the CT portion of the scan would show the contrast agent, and this high-density area could lead to overcorrection during the attenuation correction process of the SPECT images, potentially creating false "cold spots" (areas of artificially decreased tracer uptake).

Q4: What are the most common artifacts in I-131 imaging, unrelated to contrast media?

A4: The most common artifacts are typically related to contamination, patient motion, and physiological uptake variations.<sup>[8][9][10]</sup> Contamination artifacts from radioactive sweat, saliva, or urine on the patient's skin or clothing are frequent and can be mistaken for metastatic disease.<sup>[8][9][11][12]</sup> Patient motion can cause blurring and loss of resolution. Physiological uptake in organs like the salivary glands, stomach, and bladder is normal but can sometimes obscure nearby pathological uptake.<sup>[10][13]</sup>

## Troubleshooting Guide: Common Artifacts & Solutions

Artifact / Issue	Question	Potential Cause(s)	Solution(s)
Reduced I-131 Uptake	Why is there globally poor uptake of I-131 in the thyroid bed or known metastatic sites?	<ul style="list-style-type: none"> <li>- Recent administration of iodinated contrast media (e.g., Diatrizoate Sodium).-</li> <li>High dietary iodine intake.-</li> <li>Patient not following a low-iodine diet.</li> </ul>	<ul style="list-style-type: none"> <li>- Postpone I-131 imaging for at least 2-3 months after contrast administration.<a href="#">[3]</a><a href="#">[7]</a>-</li> <li>Confirm patient adherence to a low-iodine diet for 1-2 weeks prior to the scan.<a href="#">[14]</a>-</li> <li>Measure urinary iodine levels to ensure they are within an acceptable range.<a href="#">[3]</a></li> </ul>
Focal "Hot Spots" on Skin/Clothing	There are unexpected areas of intense I-131 activity that do not correspond to anatomical structures. What are they?	<ul style="list-style-type: none"> <li>- Contamination from radioactive saliva (drooling), sweat, or urine on the patient's skin or clothing.<a href="#">[8]</a><a href="#">[9]</a><a href="#">[12]</a>-</li> <li>Contaminated personal items like handkerchiefs or jewelry.<a href="#">[8]</a><a href="#">[11]</a></li> </ul>	<ul style="list-style-type: none"> <li>- Carefully question the patient about potential sources of contamination.-</li> <li>Have the patient shower and change into a clean gown.-</li> <li>Remove all personal items from the imaging field.-</li> <li>Re-image the patient to see if the artifact persists.<a href="#">[8]</a><a href="#">[12]</a></li> </ul>
Blurry or Distorted Lesions	The images appear blurry and the outlines of lesions are indistinct. Why is this happening?	<ul style="list-style-type: none"> <li>- Patient motion during the long acquisition times required for I-131 imaging.</li> </ul>	<ul style="list-style-type: none"> <li>- Use immobilization devices (e.g., straps, cushions) to help the patient remain still.-</li> <li>Clearly instruct the patient on the importance of not moving during the scan.-</li> <li>Consider</li> </ul>

motion correction  
software if available.

#### Intense Bladder Activity

A very bright spot in the pelvic region is obscuring the view of potential lesions. What can be done?

- This is physiological accumulation of excreted I-131 in the urinary bladder.

- Have the patient void immediately before imaging the pelvic area.[15]- If necessary, catheterization can be considered to drain the bladder.[9]- Acquire SPECT/CT to better localize any equivocal uptake in the pelvis.

#### Gastrointestinal (GI) Tract Activity

There is diffuse or focal uptake in the abdomen that seems to follow the bowel. Is this metastatic disease?

- This is typically normal physiological excretion of I-131 through the GI tract. [10]

- Review delayed imaging (e.g., at 48 or 72 hours) to see if the activity moves with the bowel, which confirms physiological excretion.- Correlate with other imaging modalities like CT or MRI if suspicion remains high.

#### Attenuation Artifacts (SPECT/CT)

On SPECT/CT images, there are areas of artificially low uptake corresponding to high-density areas on the CT. What causes this?

- High-density materials like metallic implants, dental fillings, or residual oral/IV contrast (like Diatrizoate Sodium) can cause overcorrection during attenuation correction. [16]

- Review the non-attenuation-corrected images to see if uptake is present in those areas.- Use advanced reconstruction algorithms designed to minimize metal artifacts if available.- Be aware of the

patient's history of implants or recent contrast-enhanced studies when interpreting the images.

---

## Experimental Protocols

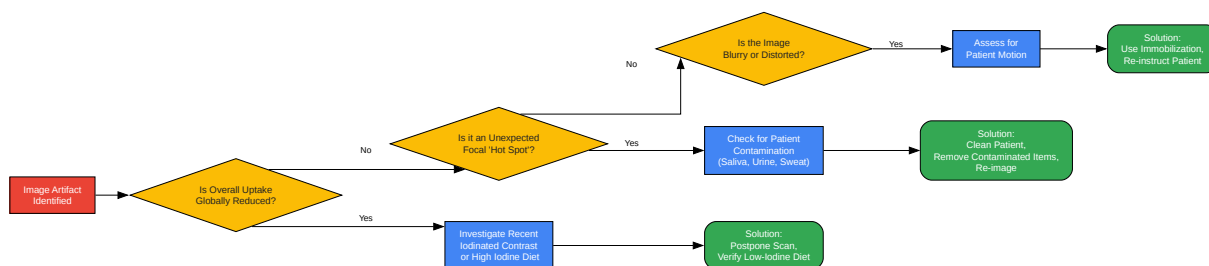
### Protocol: Quality Control for I-131 Imaging

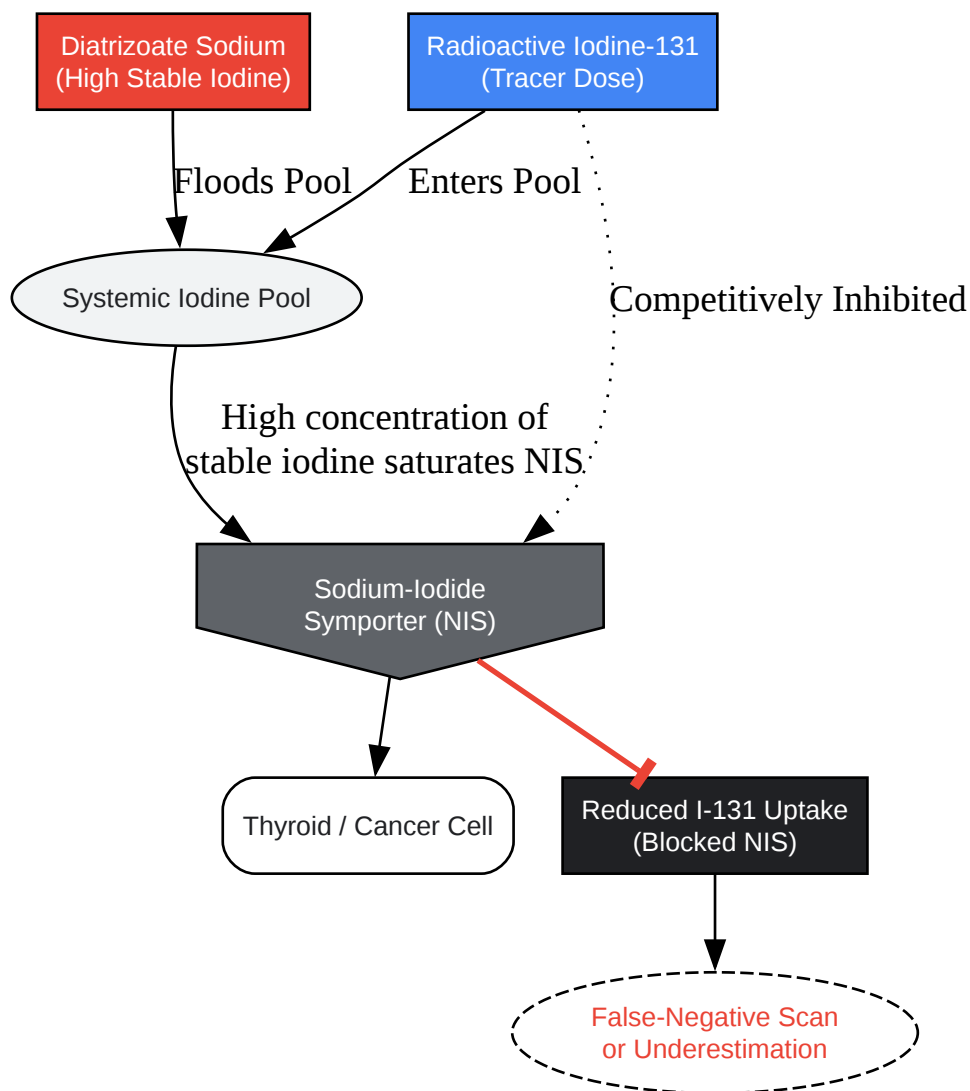
A crucial step to minimize artifacts is to ensure the imaging equipment is functioning correctly.

- Daily Quality Control:
  - Intrinsic Flood Uniformity: Before the first patient scan of the day, remove the collimator and acquire a high-count flood image using a Tc-99m or Co-57 source. This checks the uniformity of the gamma camera detector. Any non-uniformities can propagate as artifacts in patient images.
  - Photopeak Centering: Ensure the energy window is correctly centered on the 364 keV photopeak of I-131. A misaligned peak can lead to a significant loss of counts and image quality.[\[17\]](#)
- Regular Quality Control:
  - Extrinsic Flood Uniformity: Performed weekly or monthly with the collimator in place to check the combined uniformity of the detector and collimator.
  - Spatial Resolution and Linearity: Checked quarterly using a bar phantom to ensure the camera can accurately distinguish between small objects and is not producing spatial distortions.
  - SPECT/CT System Alignment: For hybrid systems, regular checks (e.g., quarterly) are essential to ensure the SPECT and CT coordinate systems are accurately aligned. Misalignment can lead to incorrect localization of uptake.[\[18\]](#)

## Visualizations

### Logical Workflow for Artifact Troubleshooting





[Click to download full resolution via product page](#)

#### Need Custom Synthesis?

BenchChem offers custom synthesis for rare earth carbides and specific isotopic labeling.

Email: [info@benchchem.com](mailto:info@benchchem.com) or [Request Quote Online](#).

## References

- 1. What is the mechanism of Diatrizoate Sodium? [synapse.patsnap.com]
- 2. radiopaedia.org [radiopaedia.org]



- 3. Effects of Iodinated Contrast-enhanced CT on Urinary Iodine Levels in Postoperative Patients with Differentiated Thyroid Cancer - PubMed [pubmed.ncbi.nlm.nih.gov]
- 4. researchgate.net [researchgate.net]
- 5. The impact of iodinated contrast agent administered during preoperative computed tomography scan on body iodine pool in patients with differentiated thyroid cancer preparing for radioactive iodine treatment - PubMed [pubmed.ncbi.nlm.nih.gov]
- 6. pure.skku.edu [pure.skku.edu]
- 7. droracle.ai [droracle.ai]
- 8. Radioiodine Contamination Artifacts and Unusual Patterns of Accumulation in Whole-body I-131 Imaging: A Case Series - PMC [pmc.ncbi.nlm.nih.gov]
- 9. Nuclear Medicine Artifacts - StatPearls - NCBI Bookshelf [ncbi.nlm.nih.gov]
- 10. researchgate.net [researchgate.net]
- 11. The radioactive handkerchief sign. A contamination artifact in I-131 imaging for metastatic thyroid carcinoma - PubMed [pubmed.ncbi.nlm.nih.gov]
- 12. apbseski.mersin.edu.tr [apbseski.mersin.edu.tr]
- 13. researchgate.net [researchgate.net]
- 14. jnm.snmjournals.org [jnm.snmjournals.org]
- 15. scholarscompass.vcu.edu [scholarscompass.vcu.edu]
- 16. Multi-modality nuclear medicine imaging: artefacts, pitfalls and recommendations - PMC [pmc.ncbi.nlm.nih.gov]
- 17. unmlf1.cuni.cz [unmlf1.cuni.cz]
- 18. Documents download module [ec.europa.eu]
- To cite this document: BenchChem. [Common artifacts in Diatrizoate sodium I 131 imaging and solutions]. BenchChem, [2025]. [Online PDF]. Available at: [https://www.benchchem.com/product/b085109#common-artifacts-in-diatrizoate-sodium-i-131-imaging-and-solutions]

---

### Disclaimer & Data Validity:

The information provided in this document is for Research Use Only (RUO) and is strictly not intended for diagnostic or therapeutic procedures. While BenchChem strives to provide

accurate protocols, we make no warranties, express or implied, regarding the fitness of this product for every specific experimental setup.

**Technical Support:** The protocols provided are for reference purposes. Unsure if this reagent suits your experiment? [[Contact our Ph.D. Support Team for a compatibility check](#)]

**Need Industrial/Bulk Grade?** [Request Custom Synthesis Quote](#)

## BenchChem

Our mission is to be the trusted global source of essential and advanced chemicals, empowering scientists and researchers to drive progress in science and industry.

### Contact

Address: 3281 E Guasti Rd  
Ontario, CA 91761, United States  
Phone: (601) 213-4426  
Email: [info@benchchem.com](mailto:info@benchchem.com)