

Technical Support Center: Myocardial Perfusion Imaging in Obese Patients

Author: BenchChem Technical Support Team. **Date:** December 2025

Compound of Interest

Compound Name: *Thallium-201*

Cat. No.: *B079191*

[Get Quote](#)

This technical support center provides troubleshooting guides and frequently asked questions (FAQs) for researchers, scientists, and drug development professionals encountering challenges with **Thallium-201** single-photon emission computed tomography (SPECT) in obese patient populations.

Frequently Asked Questions (FAQs)

Q1: Why is the accuracy of our **Thallium-201** SPECT scans reduced in obese subjects?

A1: The reduced accuracy of **Thallium-201** SPECT in obese patients is primarily due to photon attenuation and scatter.^[1] Adipose tissue absorbs and scatters the low-energy gamma photons emitted by **Thallium-201** before they can reach the gamma camera. This can lead to an underestimation of tracer uptake in the myocardial wall, potentially creating artificial perfusion defects and leading to false-positive results.^{[2][3]} Specifically, breast and diaphragmatic attenuation are well-recognized factors that diminish the accuracy of myocardial perfusion imaging.^{[1][4]}

Q2: We are observing a high number of equivocal or false-positive results in our obese cohort. What are the likely causes and how can we mitigate this?

A2: High rates of equivocal or false-positive results in obese patients undergoing **Thallium-201** SPECT are commonly due to attenuation artifacts.^[3] To mitigate this, consider the following troubleshooting steps:

- **Imaging Position:** Acquire images in both supine and prone positions. A perfusion defect that is present in one position but resolves in the other is likely an attenuation artifact.
- **Attenuation Correction:** Implement attenuation correction techniques. CT-based attenuation correction (CTAC) has been shown to significantly improve the specificity and prognostic value of SPECT imaging in obese patients.[4][5][6]
- **Alternative Radiotracers:** Consider using Technetium-99m (Tc-99m) based agents, which have higher energy photons that are less susceptible to attenuation.[7]

Q3: Can we simply increase the dose of **Thallium-201** to improve image quality in obese patients?

A3: While increasing the radiotracer dose can help to improve photon statistics, it also increases the radiation exposure to the patient.[8] A common practice is to calculate the activity based on patient weight, for instance, 1.48 MBq (0.04 mCi)/kg for **Thallium-201**. [8] However, this may not be sufficient for severely obese individuals. A more effective approach is to consider alternative radiotracers with better imaging characteristics, such as Technetium-99m sestamibi or tetrofosmin, which allow for higher administered doses with a more favorable radiation dosimetry.

Q4: Our obese subjects often cannot achieve the target heart rate with exercise stress. What are the recommended alternatives?

A4: For obese patients who cannot undergo adequate exercise stress, pharmacological stress testing is the recommended alternative.[9] Commonly used agents include:

- **Vasodilators:** Adenosine, dipyridamole, and regadenoson. Regadenoson is a selective A2A adenosine receptor agonist that can be administered as a single bolus, making it a convenient option.[9]
- **Inotropic Agents:** Dobutamine, which increases myocardial oxygen demand.

The choice of agent depends on the patient's clinical condition and institutional protocols.[9]

Troubleshooting Guides

Issue 1: Poor Image Quality and High Noise Levels

- Problem: The resulting SPECT images are noisy and difficult to interpret, with low count density.
- Potential Cause: Insufficient photon counts due to soft-tissue attenuation.
- Solutions:
 - Increase Acquisition Time: Lengthening the scan time can help to acquire more counts and improve the signal-to-noise ratio.[8]
 - Use a Multi-detector System: If available, a system with more detectors can enhance count statistics.[8]
 - Switch to a Higher Energy Radiotracer: Technetium-99m labeled agents are superior to **Thallium-201** in this regard due to their higher photon energy (140 keV vs. 68-80 keV).[7]

Issue 2: Apparent Perfusion Defects in the Inferior or Anterior Wall

- Problem: Consistent perfusion defects are observed in the inferior or anterior walls, which may not correlate with clinical findings.
- Potential Cause: These are common locations for attenuation artifacts from the diaphragm and breast tissue, respectively.[1][4]
- Solutions:
 - Prone Imaging: Acquiring an additional set of images with the patient in the prone position can help differentiate true defects from diaphragmatic attenuation.
 - Gated SPECT: Gating the acquisition to the patient's electrocardiogram (ECG) allows for the assessment of myocardial wall motion and thickening. An area with reduced perfusion but normal wall motion is more likely to be an artifact.
 - CT-Based Attenuation Correction (CTAC): This is a highly effective method for correcting attenuation artifacts and has been shown to improve diagnostic accuracy in obese

patients.[4][5][6]

Data Presentation: Comparison of Radiotracers

Feature	Thallium-201 (Tl-201)	Technetium-99m (Tc-99m) Sestamibi/Tetrofosmin
Photon Energy	68-80 keV (X-rays)	140 keV (gamma rays)
Physical Half-life	73 hours	6 hours
Image Quality	Fair to Good; Prone to attenuation	Good to Excellent; Less attenuation
Radiation Dosimetry	Higher radiation dose to the patient	Lower radiation dose to the patient
Myocardial Redistribution	Yes	Minimal (Sestamibi) / None (Tetrofosmin)

Experimental Protocols

Protocol 1: Technetium-99m Sestamibi Myocardial Perfusion Imaging

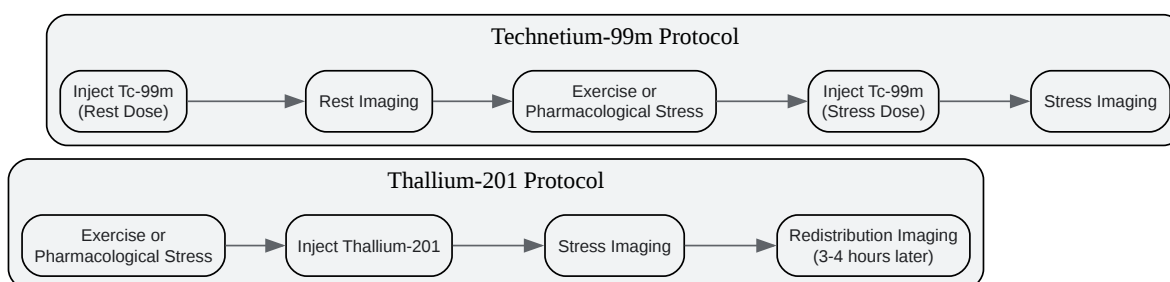
- Patient Preparation: Patients should fast for at least 4 hours prior to the study.
- Radiotracer Administration (Rest): Administer 8-12 mCi (296-444 MBq) of Tc-99m sestamibi intravenously at rest.
- Rest Imaging: Wait 60-90 minutes after injection to allow for hepatobiliary clearance. Acquire SPECT images.
- Stress Testing: Perform either exercise or pharmacological stress testing.
- Radiotracer Administration (Stress): At peak stress, administer 25-35 mCi (925-1295 MBq) of Tc-99m sestamibi intravenously.
- Stress Imaging: Begin SPECT imaging 15-60 minutes after the stress injection.

- Image Acquisition: Use a dual-head gamma camera with a 180-degree acquisition arc for each detector. Acquire 64 projections for 20-25 seconds per projection.
- Image Processing: Reconstruct the images using filtered back-projection or iterative reconstruction algorithms. Apply attenuation and scatter correction if available.

Protocol 2: CT-Based Attenuation Correction (CTAC) SPECT

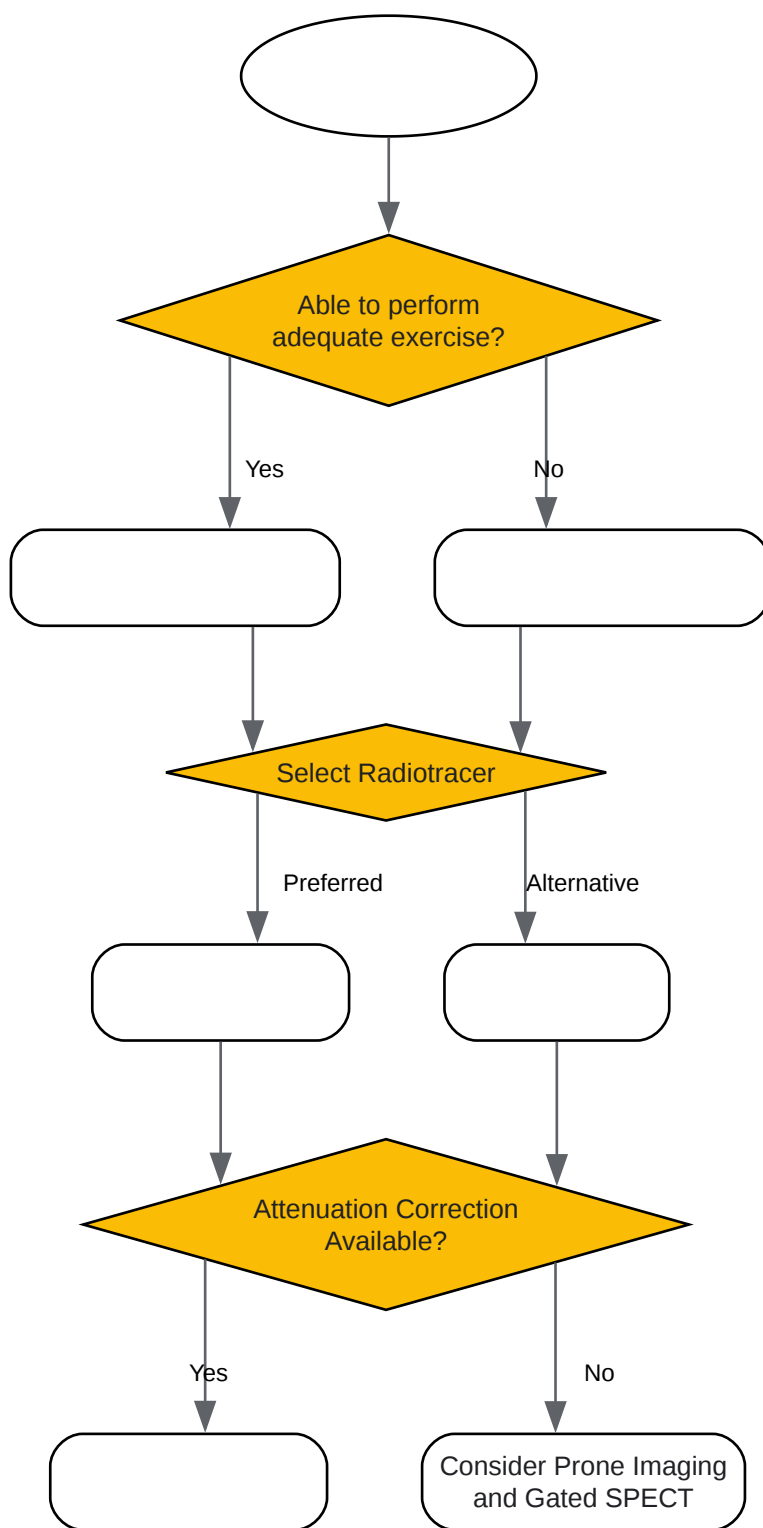
- SPECT Acquisition: Perform the standard SPECT image acquisition as described above.
- CT Acquisition: Immediately following the SPECT acquisition, without moving the patient, acquire a low-dose CT scan of the thorax.
- Attenuation Map Generation: The CT data is used to generate an attenuation map of the patient's chest.
- Image Reconstruction: The attenuation map is used during the SPECT image reconstruction process to correct for photon attenuation on a patient-specific basis.

Visualizations



[Click to download full resolution via product page](#)

Caption: Comparison of **Thallium-201** and Technetium-99m SPECT protocols.



[Click to download full resolution via product page](#)

Caption: Decision workflow for myocardial perfusion imaging in obese patients.

Need Custom Synthesis?

BenchChem offers custom synthesis for rare earth carbides and specific isotopic labeling.

Email: info@benchchem.com or [Request Quote Online](#).

References

- 1. Effect of patient obesity on the accuracy of thallium-201 myocardial perfusion imaging - PubMed [pubmed.ncbi.nlm.nih.gov]
- 2. Stress echocardiography in patients with morbid obesity - PMC [pmc.ncbi.nlm.nih.gov]
- 3. Diagnostic accuracy of thallium-201 myocardial perfusion imaging - PubMed [pubmed.ncbi.nlm.nih.gov]
- 4. The Value of Attenuation Correction in Hybrid Cardiac SPECT/CT on Inferior Wall According to Body Mass Index - PMC [pmc.ncbi.nlm.nih.gov]
- 5. CT attenuation correction improves quantitative risk prediction by cardiac SPECT in obese patients - PMC [pmc.ncbi.nlm.nih.gov]
- 6. CT attenuation correction improves quantitative risk prediction by cardiac SPECT in obese patients - PubMed [pubmed.ncbi.nlm.nih.gov]
- 7. researchgate.net [researchgate.net]
- 8. tech.snmjournals.org [tech.snmjournals.org]
- 9. emedicine.medscape.com [emedicine.medscape.com]
- To cite this document: BenchChem. [Technical Support Center: Myocardial Perfusion Imaging in Obese Patients]. BenchChem, [2025]. [Online PDF]. Available at: [https://www.benchchem.com/product/b079191#overcoming-limitations-of-thallium-201-in-obese-patients]

Disclaimer & Data Validity:

The information provided in this document is for Research Use Only (RUO) and is strictly not intended for diagnostic or therapeutic procedures. While BenchChem strives to provide accurate protocols, we make no warranties, express or implied, regarding the fitness of this product for every specific experimental setup.

Technical Support: The protocols provided are for reference purposes. Unsure if this reagent suits your experiment? [[Contact our Ph.D. Support Team for a compatibility check](#)]

Need Industrial/Bulk Grade? [Request Custom Synthesis Quote](#)

BenchChem

Our mission is to be the trusted global source of essential and advanced chemicals, empowering scientists and researchers to drive progress in science and industry.

Contact

Address: 3281 E Guasti Rd
Ontario, CA 91761, United States
Phone: (601) 213-4426
Email: info@benchchem.com