

# Navigating Gallbladder Visualization: A Comparative Guide to Modern Imaging Techniques

**Author:** BenchChem Technical Support Team. **Date:** December 2025

## Compound of Interest

Compound Name: *Iodophthalein*

Cat. No.: *B7799380*

[Get Quote](#)

The era of **iodophthalein** for gallbladder visualization has been largely superseded by advanced, non-invasive imaging modalities. This guide offers a comprehensive comparison of the current alternatives, providing researchers, scientists, and drug development professionals with the objective data and detailed methodologies necessary to make informed decisions in preclinical and clinical settings.

Historically, oral cholecystography with agents like **iodophthalein** was a cornerstone in diagnosing gallbladder pathologies. However, these methods have been rendered largely obsolete by modern techniques that offer superior safety, accuracy, and a more comprehensive diagnostic picture.<sup>[1][2]</sup> Today, the primary alternatives include ultrasonography, hepatobiliary scintigraphy (HIDA scan), computed tomography (CT), and magnetic resonance cholangiopancreatography (MRCP). While oral cholecystography is rarely performed, this guide also includes a comparative analysis of later-generation oral contrast agents for historical and research context.

## Modern Imaging Modalities: A Performance Comparison

The choice of imaging modality for gallbladder assessment is dictated by the clinical question, with each technique offering distinct advantages in sensitivity, specificity, and the type of information provided.

Imaging Modality	Primary Indication	Sensitivity	Specificity	Key Advantages	Key Limitations
Ultrasound (US)	Gallstones (Cholelithiasis)	84-98% <a href="#">[3]</a>	90-95% <a href="#">[3]</a>	Non-invasive, real-time, cost-effective, no ionizing radiation. <a href="#">[4]</a>	Operator dependent, limited by bowel gas and patient body habitus. <a href="#">[3]</a>
Acute Cholecystitis	54-73% <a href="#">[5]</a>	80-93% <a href="#">[5]</a>	Widely available, can detect ancillary findings (e.g., wall thickening, pericholecystic fluid). <a href="#">[6]</a>	Lower sensitivity compared to HIDA scan. <a href="#">[7]</a> <a href="#">[8]</a>	
HIDA Scan	Acute Cholecystitis	86-96% <a href="#">[7]</a> <a href="#">[9]</a>	79-92% <a href="#">[7]</a> <a href="#">[10]</a>	High sensitivity and specificity for cystic duct obstruction, functional assessment of gallbladder emptying. <a href="#">[8]</a> <a href="#">[11]</a>	Use of ionizing radiation, longer examination time, less anatomical detail. <a href="#">[10]</a>
CT Scan	Complicated Cholecystitis, Alternative Diagnoses	85% (for acute cholecystitis) <a href="#">[12]</a> <a href="#">[13]</a>	100% (for acute cholecystitis) <a href="#">[12]</a> <a href="#">[13]</a>	Excellent for detecting complications (e.g., perforation, abscesses),	Use of ionizing radiation, lower sensitivity for gallstones

				evaluating adjacent structures.[9][14]	compared to ultrasound. [15]
MRCP	Biliary			Non-invasive, no ionizing radiation, excellent visualization of the biliary tree.[9][17]	Higher cost, limited availability, contraindications for some patients (e.g., pacemakers).
	Obstruction (Choledocholithiasis)	85-100%[9][16]	90-94%[9][17]		

## Historical Perspective: Oral Cholecystographic Agents

For several decades, oral cholecystography was the standard for gallbladder imaging.[2] This technique relies on the oral administration of an iodine-based contrast agent that is absorbed from the intestine, excreted by the liver into the bile, and concentrated in the gallbladder, rendering it radiopaque on X-ray.[1][18] While **iodophthalein** was an early agent, subsequent developments led to compounds with improved tolerability and efficacy.

Oral Contrast Agent	Typical Dose	Gallbladder Opacification	Noteworthy Findings
Iopanoic Acid	3.0 g[4]	Good to excellent in 42% after a single dose, and an additional 34% after a second dose.[16]	Considered a highly effective agent.[19]
Iopronic Acid	4.5 g[4]	Good to excellent in 44% after a single dose, and an additional 29% after a second dose.[16]	Similar opacification to iopanoic acid with significantly fewer mild adverse reactions.[4]
Sodium Tyropanoate	-	-	Used in combination with iopanoic acid, showing improved opacification over single-agent regimens.[20]
Iocetamic Acid	-	No significant difference in cholecystographic quality compared to iopanoic acid.[21]	Lower incidence of diarrhea compared to iopanoic acid.[21]

## Experimental Protocols

Detailed methodologies are crucial for reproducible research and accurate clinical assessment. The following sections outline standardized protocols for the primary imaging modalities.

### Abdominal Ultrasound for Gallbladder Evaluation

Patient Preparation:

- Fasting for a minimum of 6-8 hours is recommended to ensure gallbladder distension and reduce bowel gas.[22]

**Equipment:**

- Curvilinear transducer (typically 2-5 MHz). A phased array probe may be used for intercostal views.[6]

**Procedure:**

- The patient is positioned supine. The left lateral decubitus position can be used to assess gallstone mobility and displace bowel gas.[23]
- The transducer is placed in the right upper quadrant, typically along the subcostal margin.
- Systematic scanning of the gallbladder in both longitudinal and transverse planes is performed.
- Key assessments include the presence of gallstones (echogenic foci with posterior acoustic shadowing), gallbladder wall thickness (normal <3 mm), the presence of pericholecystic fluid, and the sonographic Murphy's sign (maximal tenderness over the gallbladder).[6][9]
- The common bile duct should also be visualized and its diameter measured.

## Hepatobiliary Scintigraphy (HIDA Scan)

**Patient Preparation:**

- Fasting for 4-6 hours is required. Prolonged fasting (>24 hours) can lead to a false-positive result and may require pre-treatment with a cholecystokin analog like sincalide.[24][25]
- Opiate analgesics should be withheld for at least 6 hours as they can interfere with sphincter of Oddi function.[25]

**Radiopharmaceutical and Dosage:**

- Technetium-99m (99mTc) labeled mebrofenin or disofenin is administered intravenously.[25]
- The typical adult dose is 3-6 mCi (111-222 MBq).[24]

**Procedure:**

- The patient is positioned supine under a gamma camera.
- Dynamic imaging is initiated immediately after intravenous injection of the radiopharmaceutical.
- Images are acquired for at least 60 minutes.
- Normal imaging demonstrates radiotracer uptake by the liver, followed by visualization of the common bile duct, gallbladder, and small intestine within 60 minutes.[\[26\]](#)
- Non-visualization of the gallbladder at 60 minutes, with tracer activity in the small intestine, is suggestive of cystic duct obstruction and acute cholecystitis. Delayed imaging up to 4 hours or the administration of morphine can increase specificity.[\[24\]](#)

## Computed Tomography (CT) of the Gallbladder

### Patient Preparation:

- Fasting for 4-6 hours may be required, especially if intravenous contrast is to be administered.

### Equipment:

- Multidetector CT (MDCT) scanner.

### Procedure:

- The patient is positioned supine on the CT table.
- An initial non-contrast scan of the abdomen may be performed to detect calcified gallstones.
- For suspected inflammatory conditions or tumors, an intravenous iodinated contrast agent is administered.
- Imaging is typically performed in the portal venous phase (60-70 seconds after contrast injection).

- Axial images are acquired, with coronal and sagittal reconstructions providing additional anatomical detail.
- CT is particularly useful for identifying gallbladder wall thickening, pericholecystic inflammation, and complications such as perforation or abscess formation.[\[13\]](#)[\[14\]](#)

## Magnetic Resonance Cholangiopancreatography (MRCP)

### Patient Preparation:

- Fasting for at least 4 hours is required to reduce gastrointestinal secretions and promote gallbladder distension.[\[27\]](#)[\[28\]](#)

### Equipment:

- 1.5T or 3T MRI scanner with a phased-array body coil.[\[28\]](#)

### Procedure:

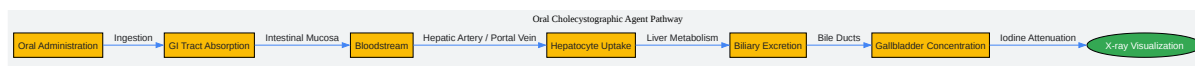- The patient is positioned supine in the MRI scanner.
- MRCP utilizes heavily T2-weighted sequences, which highlight static or slow-moving fluids, such as bile, making the biliary tree and pancreatic duct appear bright.[\[28\]](#)
- Common sequences include single-shot fast spin-echo (SSFSE) and 3D fast spin-echo with respiratory triggering.[\[29\]](#)[\[30\]](#)
- Thin-slice images are acquired and can be reconstructed into a three-dimensional representation of the biliary system using maximum intensity projection (MIP).[\[28\]](#)
- No exogenous contrast agent is required for the visualization of the ducts.[\[28\]](#)

## Mechanism of Action and Physiological Pathways

The efficacy of contrast-enhanced and radiopharmaceutical-based imaging hinges on the physiological handling of these agents.

## Oral Cholecystographic Agents (e.g., Iopanoic Acid)

Iopanoic acid is absorbed from the gastrointestinal tract, enters the bloodstream, and is taken up by hepatocytes.[18][31] The liver then excretes it into the bile, leading to its concentration in the gallbladder. The high iodine content of the molecule attenuates X-rays, allowing for radiographic visualization of the gallbladder.[18]

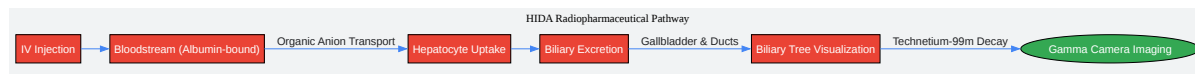


[Click to download full resolution via product page](#)

Physiological pathway of an oral cholecystographic agent.

## HIDA Scan Radiopharmaceuticals (e.g., <sup>99m</sup>Tc-Mebrofenin)

Technetium-99m labeled IDA derivatives are administered intravenously, where they bind to albumin in the blood.[11] This complex is transported to the liver and taken up by hepatocytes via a carrier-mediated organic anion transport pathway, similar to bilirubin.[11][32] The radiopharmaceutical is then excreted unchanged into the bile, allowing for dynamic imaging of the biliary system.[11]



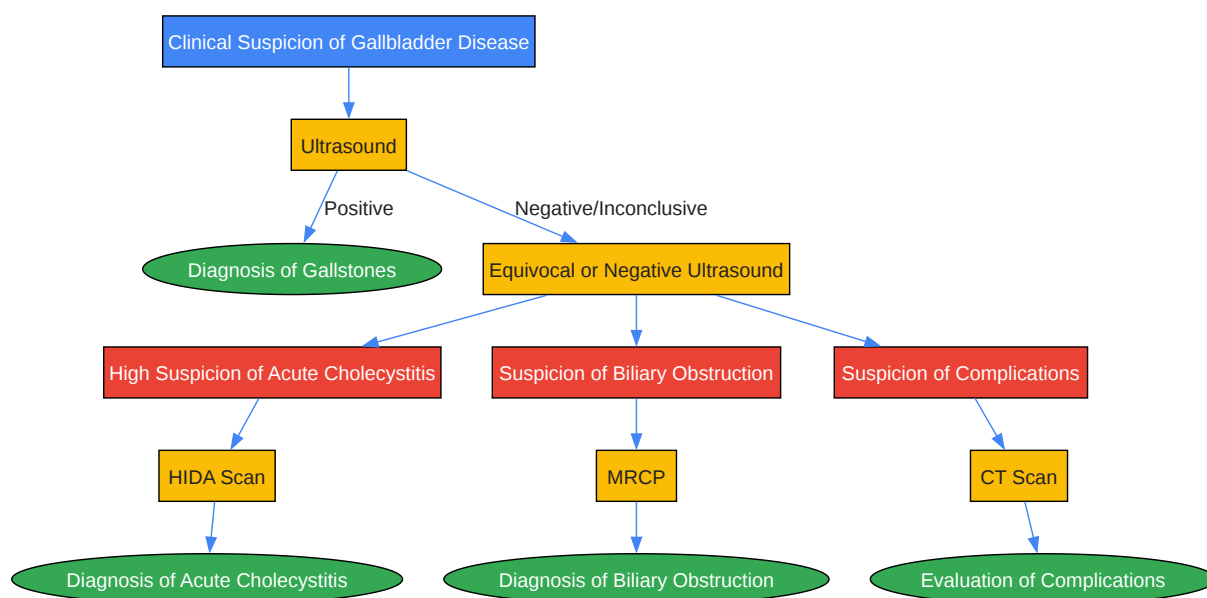
[Click to download full resolution via product page](#)



Physiological pathway of a HIDA scan radiopharmaceutical.

## Diagnostic Workflow

The selection of an imaging modality generally follows a stepwise approach based on clinical suspicion and initial findings.



[Click to download full resolution via product page](#)

Typical diagnostic workflow for gallbladder disease.

**Need Custom Synthesis?**

BenchChem offers custom synthesis for rare earth carbides and specific isotopic labeling.

Email: [info@benchchem.com](mailto:info@benchchem.com) or [Request Quote Online](#).

## References

- 1. Diagnostic Accuracy of Magnetic Resonance Cholangiopancreatography in Comparison With Endoscopic Retrograde Cholangiopancreatography for Detection of the Etiology of Obstructive Jaundice - ProQuest [proquest.com]
- 2. radiology.wisc.edu [radiology.wisc.edu]
- 3. ijbamr.com [ijbamr.com]
- 4. Comparison of oral cholecystopaques: iopronic acid vs. iopanoic acid - PubMed [pubmed.ncbi.nlm.nih.gov]
- 5. Does ultrasonography accurately diagnose acute cholecystitis? Improving diagnostic accuracy based on a review at a regional hospital - PMC [pmc.ncbi.nlm.nih.gov]
- 6. edus.ucsf.edu [edus.ucsf.edu]
- 7. Clinical implications of hepatobiliary scintigraphy and ultrasound in the diagnosis of acute cholecystitis - PubMed [pubmed.ncbi.nlm.nih.gov]
- 8. Is HIDA Scan Necessary for Sonographically Suspicious Cholecystitis? | Bernescu | Journal of Current Surgery [currentsurgery.org]
- 9. droracle.ai [droracle.ai]
- 10. consensus.app [consensus.app]
- 11. Hepatobiliary Scintigraphy - StatPearls - NCBI Bookshelf [ncbi.nlm.nih.gov]
- 12. auntminnie.com [auntminnie.com]
- 13. Comparing the Diagnostic Accuracy of Ultrasound and CT in Evaluating Acute Cholecystitis - PMC [pmc.ncbi.nlm.nih.gov]
- 14. Tests used to diagnose gallbladder problems - Envision Radiology [envrad.com]
- 15. Can CT Show Gallstones? Accuracy and Detection - Liv Hospital [int.livhospital.com]
- 16. Diagnostic Accuracy of Magnetic Resonance Cholangiopancreatography in Comparison With Endoscopic Retrograde Cholangiopancreatography for Detection of the Etiology of Obstructive Jaundice - PubMed [pubmed.ncbi.nlm.nih.gov]

- 17. droracle.ai [droracle.ai]
- 18. What is Iopanoic Acid used for? [synapse.patsnap.com]
- 19. Gallbladder density and iodine concentration in humans during oral cholecystography. A comparison of iopanoic acid and iopronic acid - PubMed [pubmed.ncbi.nlm.nih.gov]
- 20. A clinical trial of oral cholecystography using combinations of contrast agents and two consecutive doses - PubMed [pubmed.ncbi.nlm.nih.gov]
- 21. A comparative trial of two oral cholecystographic contrast media--iocetamic acid (Cholebrin) and iopanoic acid (Telepaque) - PubMed [pubmed.ncbi.nlm.nih.gov]
- 22. Abdominal Ultrasound Made Easy: Step-By-Step Guide - POCUS 101 [pocus101.com]
- 23. Gallbladder | Sonoguide [acep.org]
- 24. apps.ausrad.com [apps.ausrad.com]
- 25. medfordradiology.com [medfordradiology.com]
- 26. droracle.ai [droracle.ai]
- 27. Magnetic resonance cholangiopancreatography: the ABC of MRCP - PMC [pmc.ncbi.nlm.nih.gov]
- 28. radiopaedia.org [radiopaedia.org]
- 29. MRCP Protocol [pre.weill.cornell.edu]
- 30. mrimaster.com [mrimaster.com]
- 31. What is the mechanism of Iopanoic Acid? [synapse.patsnap.com]
- 32. Hepatic clearance mechanism of Tc-99m-HIDA and its effect on quantitation of hepatobiliary function: Concise communication - PubMed [pubmed.ncbi.nlm.nih.gov]
- To cite this document: BenchChem. [Navigating Gallbladder Visualization: A Comparative Guide to Modern Imaging Techniques]. BenchChem, [2025]. [Online PDF]. Available at: [https://www.benchchem.com/product/b7799380#alternatives-to-iodophthalein-for-gallbladder-visualization]

---

### Disclaimer & Data Validity:

The information provided in this document is for Research Use Only (RUO) and is strictly not intended for diagnostic or therapeutic procedures. While BenchChem strives to provide accurate protocols, we make no warranties, express or implied, regarding the fitness of this product for every specific experimental setup.

**Technical Support:** The protocols provided are for reference purposes. Unsure if this reagent suits your experiment? [[Contact our Ph.D. Support Team for a compatibility check](#)]

**Need Industrial/Bulk Grade?** [Request Custom Synthesis Quote](#)

## BenchChem

Our mission is to be the trusted global source of essential and advanced chemicals, empowering scientists and researchers to drive progress in science and industry.

### Contact

Address: 3281 E Guasti Rd  
Ontario, CA 91761, United States  
Phone: (601) 213-4426  
Email: [info@benchchem.com](mailto:info@benchchem.com)