

# Technical Support Center: Histological Analysis of ANIT-Treated Livers

**Author:** BenchChem Technical Support Team. **Date:** December 2025

## Compound of Interest

Compound Name: 1-Naphthyl isothiocyanate

Cat. No.: B7722655

[Get Quote](#)

This technical support center provides troubleshooting guidance and frequently asked questions (FAQs) for researchers, scientists, and drug development professionals working with histological sections of alpha-naphthylisothiocyanate (ANIT)-treated livers. Our aim is to help you identify and overcome common challenges to ensure accurate and reliable experimental results.

## Frequently Asked Questions (FAQs)

Q1: What are the expected key histopathological features in an ANIT-treated liver section?

A1: ANIT administration in rodents induces intrahepatic cholestasis, leading to a cascade of observable liver injuries. Key features include:

- **Bile Duct Injury and Proliferation:** ANIT is toxic to cholangiocytes (bile duct epithelial cells), causing damage and subsequent proliferation of bile ductules.<sup>[1]</sup>
- **Hepatocellular Necrosis:** The blockage of bile flow leads to an accumulation of toxic bile acids, causing the death of hepatocytes, often seen as focal necrosis.
- **Inflammation:** An inflammatory response is triggered by the initial injury, characterized by the infiltration of neutrophils and other inflammatory cells, particularly in the portal tracts.
- **Edema:** Swelling in the portal tracts is a common finding.

- Cholestasis: This is characterized by the presence of bile plugs (bile thrombi) within canaliculi, and in severe cases, in bile ductules. Hepatocytes may also contain bile pigment. [\[2\]](#)[\[3\]](#)

Q2: I see yellowish-brown pigment in my H&E stained liver sections. Is this an artifact or a real finding?

A2: This is likely a real finding characteristic of cholestasis, but it can be mistaken for other pigments. In the context of ANIT-induced injury, this pigment is often bilirubin. However, it's crucial to differentiate it from:

- Hemosiderin: A golden-brown pigment from red blood cell breakdown, which can be confirmed with a Perls' Prussian blue stain.
- Lipofuscin: A wear-and-tear pigment that can have a similar appearance. Special stains, such as the Hall's bilirubin stain, can be used to specifically identify bile pigments.[\[2\]](#)

Q3: My tissue sections appear brittle and are difficult to section. What could be the cause?

A3: Brittleness in liver tissue, especially after ANIT treatment, can be due to several factors:

- Over-fixation: Prolonged fixation in formalin can harden the tissue.
- Over-dehydration: Excessive time in high-concentration ethanol during processing can make the tissue brittle.
- ANIT-induced Fibrosis: In chronic models, ANIT can cause fibrosis, which increases the collagen content and makes the tissue harder to section.

To troubleshoot, ensure your fixation and processing schedules are optimized for liver tissue and consider using a decalcifying solution for a very brief period if the tissue is exceptionally hard, though this is not standard practice for non-calcified tissues.

## Troubleshooting Common Artifacts in ANIT-Treated Liver Sections

The following table summarizes common artifacts that may be encountered during the histological preparation of ANIT-treated liver tissues, their potential causes, and recommended solutions.

Artifact	Appearance	Potential Causes in ANIT Models	Recommended Solutions
Bile Pigment Mimics	Yellowish-brown granular deposits.	Can be confused with formalin pigment (acid hematin), hemosiderin, or lipofuscin. Formalin pigment can form if the formalin is not buffered.	Use 10% neutral buffered formalin. Confirm bile with Hall's stain and rule out hemosiderin with Perls' Prussian blue.
"Streaming" Artifact of Glycogen	Wispy, pale areas within hepatocytes.	ANIT can alter hepatocyte metabolism. Glycogen can be lost or redistributed during fixation.	For optimal glycogen preservation, fix in alcohol-based fixatives like Carnoy's solution immediately after tissue collection.
Tissue Folds and Wrinkles	Darkly stained lines or overlapping tissue.	Increased fibrosis in chronic ANIT models can make sections prone to folding during mounting.	Ensure the water bath temperature is optimal. Use charged slides and carefully flatten the section on the slide.
Cracks and Tears	Spaces or fractures within the tissue.	Inadequate or delayed fixation can lead to autolysis and tissue cracking. Over-dehydration can make the tissue brittle.	Ensure rapid and adequate fixation with a sufficient volume of fixative (10:1 ratio of fixative to tissue). Optimize the dehydration schedule.
Uneven Staining	Patchy or inconsistent staining intensity.	Residual wax due to incomplete deparaffinization. Inadequate penetration of stains in areas of dense	Extend the time in xylene before staining. Ensure proper timing and agitation during the staining steps.

inflammation or  
fibrosis.

---

Nuclear Bubbling	"Soap bubble" appearance in nuclei.	Overheating of slides during drying can cause this artifact.	Dry slides at a lower temperature (e.g., 37-50°C) or allow them to air dry partially before placing them in an oven.
------------------	-------------------------------------	--	--

---

## Detailed Experimental Protocol: Histological Processing of ANIT-Treated Mouse Liver

This protocol is a general guideline and may require optimization based on your specific experimental conditions.

### 1. Tissue Collection and Fixation:

- Immediately following euthanasia, perfuse the mouse with phosphate-buffered saline (PBS) to remove blood.
- Excise the liver and place it in a cassette.
- Fix in 10% neutral buffered formalin for 24-48 hours at room temperature. The volume of fixative should be at least 10 times the volume of the tissue. Note: Avoid prolonged fixation to prevent tissue hardening.

### 2. Tissue Processing (Dehydration, Clearing, and Infiltration):

- This can be performed manually or using an automated tissue processor. A sample schedule is as follows:
  - 70% Ethanol: 2 hours
  - 80% Ethanol: 2 hours
  - 95% Ethanol (2 changes): 2 hours each

- 100% Ethanol (3 changes): 2 hours each
- Xylene (2 changes): 2 hours each
- Paraffin wax (2 changes): 2 hours each at 60°C

### 3. Embedding:

- Orient the tissue in a mold filled with molten paraffin wax. Ensure the tissue surface to be sectioned is facing down and is flat.
- Cool the block on a cold plate.

### 4. Sectioning:

- Trim the paraffin block.
- Section the tissue at 4-5  $\mu\text{m}$  thickness using a microtome.
- Float the sections on a warm water bath (40-45°C) to remove wrinkles.
- Mount the sections onto charged glass slides.
- Dry the slides in an oven at 37-50°C overnight or at 60°C for 1 hour.

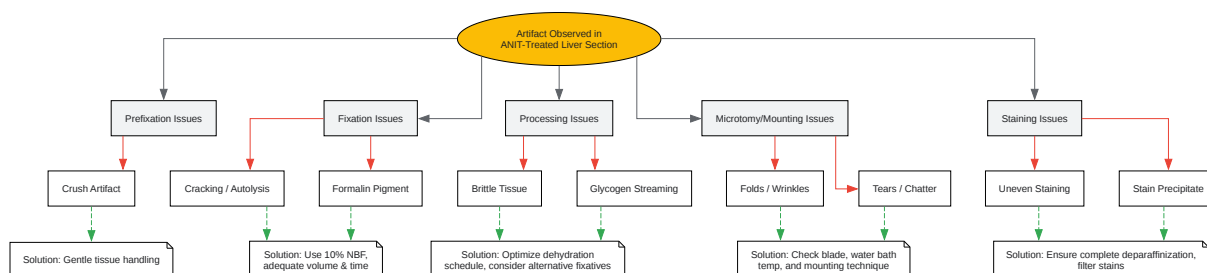
### 5. Staining (Hematoxylin and Eosin - H&E):

- Deparaffinize and rehydrate the sections:
  - Xylene (2 changes): 5 minutes each
  - 100% Ethanol (2 changes): 3 minutes each
  - 95% Ethanol: 3 minutes
  - 70% Ethanol: 3 minutes
  - Running tap water: 5 minutes

- Stain in Hematoxylin: 3-5 minutes.
- Rinse in running tap water.
- Differentiate in 0.5% acid alcohol: 1-5 seconds.
- Rinse in running tap water.
- "Blue" the sections in Scott's tap water substitute or running tap water: 1-2 minutes.
- Rinse in running tap water.
- Stain in Eosin: 1-3 minutes.
- Dehydrate, clear, and mount:
  - 95% Ethanol: 2 minutes
  - 100% Ethanol (2 changes): 2 minutes each
  - Xylene (2 changes): 2 minutes each
  - Mount with a permanent mounting medium and coverslip.

## Visual Guides

## Troubleshooting Workflow for Histological Artifacts

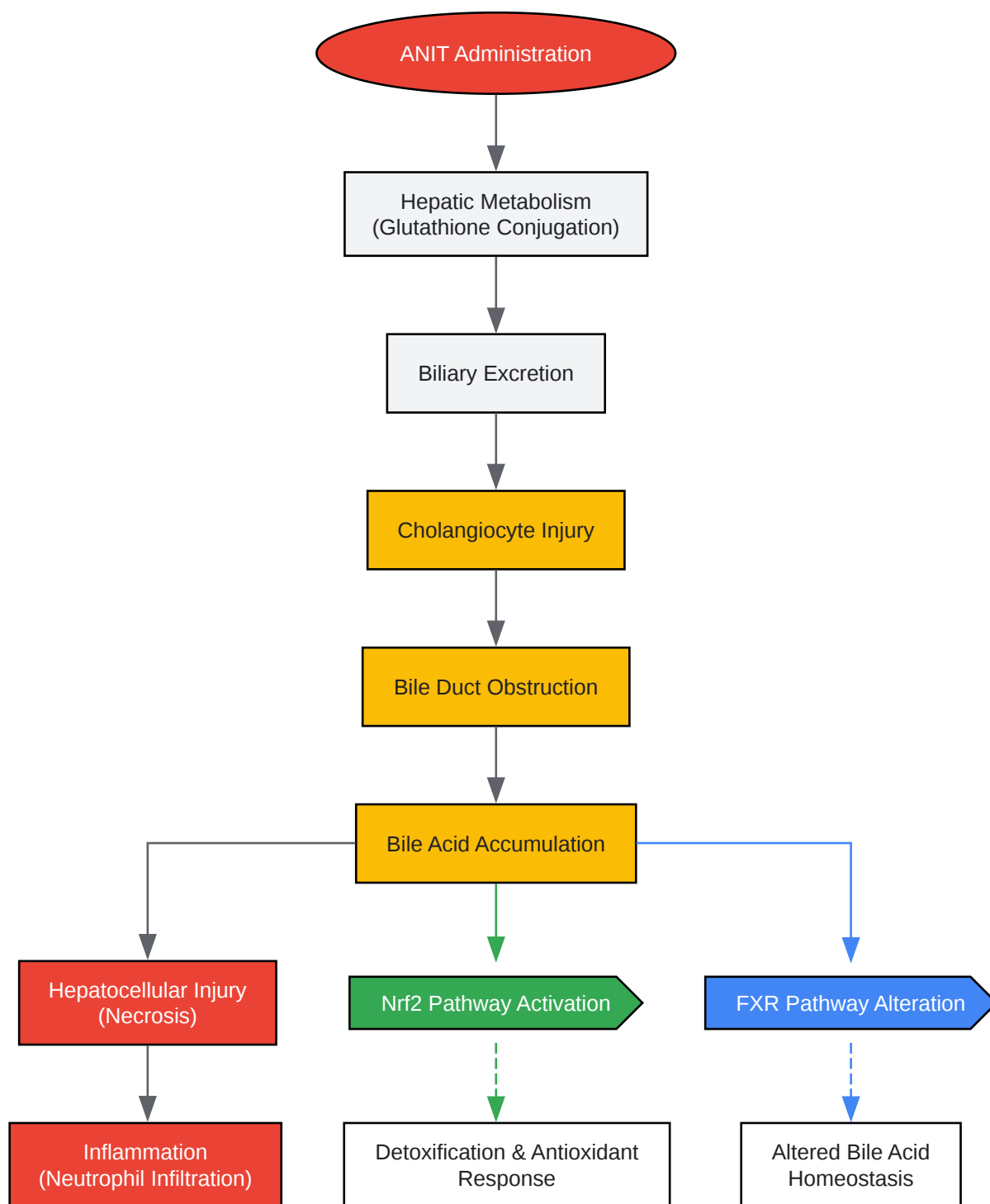

[Click to download full resolution via product page](#)

Caption: A workflow for troubleshooting common histological artifacts.

## Key Signaling Pathways in ANIT-Induced Liver Injury





[Click to download full resolution via product page](#)

Caption: Signaling pathways in ANIT-induced liver injury.

**Need Custom Synthesis?**

BenchChem offers custom synthesis for rare earth carbides and specific isotopic labeling.

Email: [info@benchchem.com](mailto:info@benchchem.com) or [Request Quote Online](#).

## References

- 1. researchgate.net [researchgate.net]
- 2. Cholestasis - Histopathology [meddean.luc.edu]
- 3. [Histological changes in liver tissue in cholestasis] - PubMed [pubmed.ncbi.nlm.nih.gov]
- To cite this document: BenchChem. [Technical Support Center: Histological Analysis of ANIT-Treated Livers]. BenchChem, [2025]. [Online PDF]. Available at: [https://www.benchchem.com/product/b7722655#common-artifacts-in-histological-sections-of-anit-treated-livers]

---

**Disclaimer & Data Validity:**

The information provided in this document is for Research Use Only (RUO) and is strictly not intended for diagnostic or therapeutic procedures. While BenchChem strives to provide accurate protocols, we make no warranties, express or implied, regarding the fitness of this product for every specific experimental setup.

**Technical Support:** The protocols provided are for reference purposes. Unsure if this reagent suits your experiment? [[Contact our Ph.D. Support Team for a compatibility check](#)]

**Need Industrial/Bulk Grade?** [Request Custom Synthesis Quote](#)

## BenchChem

Our mission is to be the trusted global source of essential and advanced chemicals, empowering scientists and researchers to drive progress in science and industry.

### Contact

Address: 3281 E Guasti Rd  
Ontario, CA 91761, United States  
Phone: (601) 213-4426  
Email: [info@benchchem.com](mailto:info@benchchem.com)

