

Managing adverse events associated with subretinal injection of FT001

Author: BenchChem Technical Support Team. **Date:** December 2025

Compound of Interest

Compound Name: FT001

Cat. No.: B607558

[Get Quote](#)

Technical Support Center: Subretinal Injection of FT001

This technical support center provides troubleshooting guides and frequently asked questions (FAQs) for managing adverse events associated with the subretinal injection of **FT001**. The information is intended for researchers, scientists, and drug development professionals.

Troubleshooting Guides

This section provides a systematic approach to identifying and managing potential adverse events that may be encountered during or after the subretinal injection of **FT001**.

Issue 1: Difficulty in Forming a Subretinal Bleb

- Symptom: Resistance felt during injection, or the therapeutic agent refluxing into the vitreous cavity instead of forming a distinct bleb in the subretinal space.
- Possible Causes:
 - Incorrect needle placement (too shallow or too deep).
 - Obstruction of the cannula tip.
 - High infusion pressure causing retinal damage.^[1]

- Retinal atrophy at the injection site.[2][3]
- Immediate Action:
 - Pause the injection immediately.
 - Visualize the needle tip's position using intraoperative optical coherence tomography (OCT) if available.[3][4]
 - If the needle is not in the subretinal space, carefully reposition it.
 - Check the cannula for any blockage.
- Preventative Measures:
 - Ensure proper visualization of the posterior hyaloid.[5]
 - Consider creating a "pre-bleb" with a balanced salt solution (BSS) to create a space for the therapeutic agent.[1][3]
 - Use a slow and controlled injection speed.[1]

Issue 2: Intraoperative Retinal Hemorrhage

- Symptom: Bleeding at the injection site during the procedure.
- Possible Causes:
 - Damage to retinal or choroidal blood vessels.
 - Inadvertent injury to scleral blood vessels during needle insertion.[6]
- Immediate Action:
 - Temporarily increase intraocular pressure (IOP) to tamponade the bleeding.
 - If bleeding persists, cautery may be necessary.
- Preventative Measures:

- Careful selection of the retinotomy site, avoiding major blood vessels.
- Meticulous surgical technique with precise needle placement.

Issue 3: Post-injection Inflammation (Uveitis)

- Symptom: Signs of inflammation in the eye, such as redness, pain, and cells in the anterior chamber or vitreous, observed in the days following the procedure.
- Possible Causes:
 - Immune response to the viral vector or **FT001** itself.[\[1\]](#)
 - Surgical trauma.
 - Reflux of the vector into the vitreous cavity.[\[1\]](#)
- Management:
 - Topical or systemic corticosteroids are typically administered to control inflammation.[\[4\]](#)
 - Close monitoring of intraocular pressure is necessary as corticosteroids can cause it to elevate.
- Preventative Measures:
 - A course of perioperative steroids can help mitigate the inflammatory response.[\[1\]](#)[\[4\]](#)
 - Minimizing reflux of the therapeutic agent into the vitreous cavity through careful surgical technique.[\[7\]](#)

Issue 4: Retinal Detachment

- Symptom: Separation of the neurosensory retina from the retinal pigment epithelium (RPE) beyond the initial bleb.
- Possible Causes:
 - Retinal tears occurring at the injection site.

- Excessive volume of injected fluid.
- Management:
 - Small, localized detachments may resolve on their own as the subretinal fluid is absorbed.
 - Larger or progressive detachments may require further surgical intervention, such as vitrectomy and gas tamponade.
- Preventative Measures:
 - Creating a small, well-controlled retinotomy.
 - Injecting the therapeutic agent slowly and in a controlled manner to avoid overstretching the retina.^[1]

Frequently Asked Questions (FAQs)

Q1: What are the most common adverse events associated with subretinal injection?

A1: The most frequently reported adverse events are generally mild and can include intraocular inflammation, retinal hemorrhage, and increased intraocular pressure.^{[4][8]} More severe, though less common, complications include retinal detachment and cataract formation.^{[4][8]}

Q2: How can the risk of vector reflux into the vitreous be minimized?

A2: Minimizing vector reflux is crucial to reduce off-target effects and potential immune responses.^[7] Techniques to achieve this include creating a small and self-sealing retinotomy, using a two-step injection process with a pre-bleb of BSS, and ensuring slow and controlled delivery of the therapeutic agent.^{[1][3][5]} Performing an intravitreal lavage after the injection can also significantly reduce the amount of vector in the vitreous.^[7]

Q3: What is the recommended management for post-injection elevated intraocular pressure (IOP)?

A3: Elevated IOP is a known complication, often associated with the inflammatory response or the use of corticosteroids.^[4] Management typically involves the use of topical IOP-lowering

medications. In cases of persistent or severe elevation, systemic medications or further surgical intervention may be necessary.

Q4: Can subretinal injection lead to cataract formation?

A4: Yes, cataract formation is a possible complication, particularly if the lens is inadvertently touched by surgical instruments during the procedure.^[6] Careful surgical technique and clear visualization throughout the procedure are key to minimizing this risk.

Quantitative Data Summary

The following table summarizes potential adverse events and their reported frequencies from clinical trials involving subretinal injections. Note that frequencies can vary depending on the specific therapeutic agent, patient population, and surgical technique.

Adverse Event	Reported Frequency	Severity
Intraocular Inflammation	Common	Mild to Moderate
Subconjunctival Hemorrhage	~10% of injections	Mild
Retinal Detachment	0.0% - 0.08% per injection ^[4]	Severe
Retinal Hemorrhage	Varies	Mild to Severe
Increased Intraocular Pressure	Common	Mild to Moderate
Cataract Formation	Less Common	Moderate to Severe
Endophthalmitis	Rare	Severe

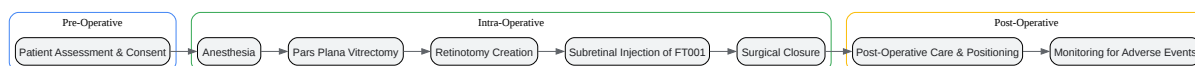
Experimental Protocols

Protocol 1: Standard Subretinal Injection Procedure

- Anesthesia: The procedure is performed under retrobulbar or general anesthesia.^[5]
- Vitrectomy: A standard three-port pars plana vitrectomy is performed.^[5] If the posterior hyaloid is attached, a posterior vitreous detachment is induced.^[5]

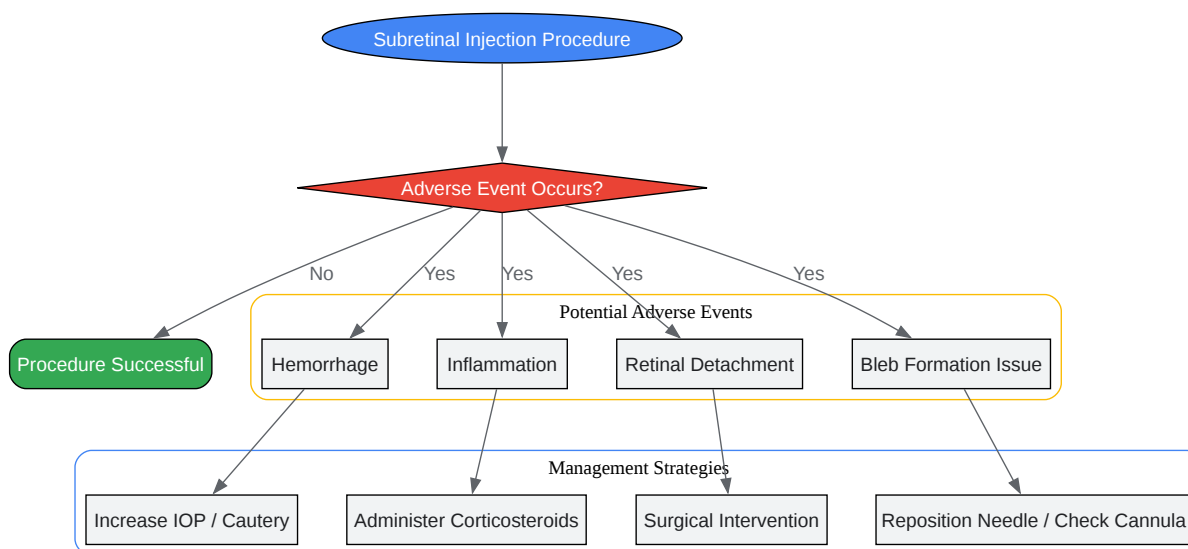
- Retinotomy Site Selection: A suitable injection site is chosen, typically in the superotemporal quadrant, avoiding major retinal vessels.
- Retinotomy Creation: A small retinotomy is created using a microvitrectomy blade or the subretinal injection cannula itself.
- Subretinal Injection:
 - One-Step Technique: The cannula is carefully introduced through the retinotomy into the subretinal space, and the therapeutic agent (**FT001**) is slowly injected to create a bleb.[3][5]
 - Two-Step Technique: A small amount of BSS is first injected to create a pre-bleb, followed by the injection of **FT001** into this space.[3][5]
- Closure: The cannula is withdrawn, and the stability of the bleb is confirmed. Sclerotomies are sutured if necessary to prevent hypotony and vector reflux.[1]
- Postoperative Care: Patients are typically advised to maintain a specific head position for a period to ensure proper localization of the therapeutic agent.[1] Postoperative anti-inflammatory medications are administered.

Visualizations



[Click to download full resolution via product page](#)

Caption: Experimental workflow for subretinal injection.



[Click to download full resolution via product page](#)

Need Custom Synthesis?

BenchChem offers custom synthesis for rare earth carbides and specific isotopic labeling.

Email: info@benchchem.com or [Request Quote Online](#).

References

- 1. mdpi.com [mdpi.com]
- 2. mdpi.com [mdpi.com]
- 3. encyclopedia.pub [encyclopedia.pub]

- 4. Treatment-Emergent Adverse Events in Gene Therapy Trials for Inherited Retinal Diseases: A Narrative Review - PMC [pmc.ncbi.nlm.nih.gov]
- 5. Subretinal Injection Techniques for Retinal Disease: A Review - PMC [pmc.ncbi.nlm.nih.gov]
- 6. Frontiers | Advances in technical methods and applications of subretinal injections in experimental animals [frontiersin.org]
- 7. An Optimized Treatment Protocol for Subretinal Injections Limits Intravitreal Vector Distribution - PMC [pmc.ncbi.nlm.nih.gov]
- 8. karger.com [karger.com]
- To cite this document: BenchChem. [Managing adverse events associated with subretinal injection of FT001]. BenchChem, [2025]. [Online PDF]. Available at: [https://www.benchchem.com/product/b607558#managing-adverse-events-associated-with-subretinal-injection-of-ft001]

Disclaimer & Data Validity:

The information provided in this document is for Research Use Only (RUO) and is strictly not intended for diagnostic or therapeutic procedures. While BenchChem strives to provide accurate protocols, we make no warranties, express or implied, regarding the fitness of this product for every specific experimental setup.

Technical Support: The protocols provided are for reference purposes. Unsure if this reagent suits your experiment? [[Contact our Ph.D. Support Team for a compatibility check](#)]

Need Industrial/Bulk Grade? [Request Custom Synthesis Quote](#)

BenchChem

Our mission is to be the trusted global source of essential and advanced chemicals, empowering scientists and researchers to drive progress in science and industry.

Contact

Address: 3281 E Guasti Rd
Ontario, CA 91761, United States
Phone: (601) 213-4426
Email: info@benchchem.com