

Confounding factors in the interpretation of 99mTc-bicisate scans

Author: BenchChem Technical Support Team. **Date:** December 2025

Compound of Interest

Compound Name: *Bicisate dihydrochloride*

Cat. No.: *B606108*

[Get Quote](#)

Technical Support Center: 99mTc-Bicisate Scans

Welcome to the technical support center for 99mTc-bicisate (also known as 99mTc-ECD) SPECT scans. This resource provides troubleshooting guides and frequently asked questions (FAQs) to help researchers, scientists, and drug development professionals address common challenges in the interpretation of these brain perfusion studies.

Frequently Asked Questions (FAQs)

Category 1: Technical & Methodological Issues

Question 1: Our 99mTc-bicisate SPECT images seem to have poor diagnostic accuracy. How can we improve this?

Answer: Poor diagnostic accuracy can often be attributed to technical factors during image reconstruction. An overall nonlinear relationship has been observed between 99mTc-bicisate SPECT data and cerebral blood flow (CBF) as measured by PET scans.^[1] Implementing a combination of linearization and scatter-attenuation correction methods during image processing has been shown to significantly improve diagnostic accuracy, sensitivity, and specificity.^{[1][2]}

Additionally, optimizing the parameters of your quantitative reconstruction algorithm is crucial. Factors such as the weighting factor used in scatter correction and the total number of

iterations can significantly impact the reconstructed activity concentration and the signal-to-noise ratio.

Question 2: What are the essential quality control (QC) steps for the ^{99m}Tc -bicisate radiopharmaceutical, and which method is most efficient?

Answer: Ensuring high radiochemical purity (RCP) of ^{99m}Tc -bicisate is critical before administration. The manufacturer's method often involves thin-layer chromatography (TLC), which can be time-consuming.[3] For busy clinical or research settings, alternative QC methods have been validated. The C18 mini cartridge/saline method is noted as one of the simplest and fastest, providing a result in approximately 2 minutes.[3] It is important to note that using a fast flow rate with the C18/saline method can lead to a significantly lower measured RCP.[3]

Question 3: We are observing artifacts in our images. What are the common causes and how can we mitigate them?

Answer: Artifacts can be patient-related or technical. Patient motion is a significant cause of artifacts.[4] It is crucial to ensure the patient is comfortable and to use light head restraint to minimize movement during acquisition.[5] Breathing artifacts can also occur, especially in SPECT/CT imaging.[6]

Technical artifacts can arise from faulty radiopharmaceutical preparation, leading to altered biodistribution (e.g., uptake in the stomach or thyroid due to free pertechnetate).[6] Equipment-related issues, often due to inadequate QC and calibration, can also be a source of artifacts.[6] Reviewing raw imaging data in a cinematic display before reconstruction can help identify issues like patient motion or extracardiac uptake that might degrade image quality.[7]

Category 2: Patient-Related Factors

Question 4: What is the correct patient preparation protocol before a ^{99m}Tc -bicisate injection?

Answer: Proper patient preparation is one of the most critical aspects of a successful scan. The environment during tracer injection and uptake significantly influences the resulting brain perfusion pattern.

- Environment: The patient should be placed in a quiet, dimly lit room.[5]

- Patient State: The patient should be comfortable, either seated or reclining with their eyes and ears open. They should be instructed not to speak or read.[5][8]
- IV Access: Intravenous access should be established at least 10 minutes before injection to allow the patient to accommodate to the setting.[5][8]
- Interaction: Minimal interaction should occur with the patient immediately before, during, and for at least 5 minutes after the injection.[5][8]
- Substances to Avoid: Patients should be instructed to avoid caffeine, alcohol, and other drugs known to affect cerebral blood flow prior to the scan.[5][8]

Question 5: Does a patient's age or renal function affect the scan interpretation?

Answer: Yes, both factors can be confounding.

- Age: Regional distribution of 99mTc-bicisate can decline significantly with age in certain brain regions, including the cingulate cortex, prefrontal and parietal cortex, striatum, and hippocampus (a decline of 1.0%-2.0% per decade).[9] Recognizing these normal, age-related patterns is important for accurate clinical interpretation.[9]
- Renal Impairment: 99mTc-bicisate is primarily cleared by the kidneys.[10][11] Therefore, caution should be exercised in patients with renal impairment as tracer elimination may be prolonged, potentially affecting dosimetry and image background clearance.[10][12]

Question 6: How should we manage patients who require sedation?

Answer: If sedation is necessary for an uncooperative patient, it should ideally be administered after the injection of the 99mTc-bicisate.[5][8] This is to ensure that the perfusion pattern captured by the tracer reflects the patient's baseline, unsedated state, as sedative agents can alter cerebral blood flow.

Category 3: Pathophysiological & Interpretive Pitfalls

Question 7: We are imaging a patient with a subacute stroke. The 99mTc-bicisate scan shows a perfusion defect, but other imaging suggests normal or even increased blood flow. Why is there a discrepancy?

Answer: This is a well-documented and critical confounding factor. In subacute stroke (e.g., 11-23 days after onset), ^{99m}Tc-bicisate may fail to accurately reflect cerebral blood flow (CBF), particularly in cases of reperfusion or "luxury perfusion".^[13] While other methods might show normal or elevated flow, ^{99m}Tc-bicisate scans can still show a defect (low count rate).^{[13][14]}

The reason for this discrepancy lies in the tracer's retention mechanism. ^{99m}Tc-bicisate is a lipophilic complex that crosses the blood-brain barrier and is then metabolized within viable brain cells by enzymes into a polar, trapped complex.^{[14][15]} In ischemic but reperfused tissue, the neuronal metabolic function required for this de-esterification and trapping may be damaged or absent.^[14] Consequently, even with restored blood flow, the tracer is not retained, leading to a false appearance of a perfusion defect. This suggests that ^{99m}Tc-bicisate uptake may be more indicative of tissue viability than just blood flow in these specific scenarios.^{[14][16]}

Question 8: How does an ictal vs. interictal state affect scan interpretation in epilepsy patients?

Answer: The timing of the injection relative to seizure activity is paramount for localization of epileptogenic foci.

- Ictal Scans: When ^{99m}Tc-bicisate is injected during a seizure, the scan typically reveals focal hyperperfusion (increased uptake) in the region of seizure origin.^[17]
- Interictal Scans: Scans performed between seizures (interictal) often show focal hypoperfusion (decreased uptake) in the same epileptogenic region.^[17]

Ictal SPECT with ^{99m}Tc-bicisate is generally considered a more sensitive tool for identifying seizure foci than interictal SPECT or scalp EEG, especially when MRI scans are normal.^[17] Close coordination between neurology and nuclear medicine teams is essential for the timely injection of the tracer during a seizure event.^[18]

Quantitative Data Summary

Table 1: Impact of Correction Methods on Diagnostic Accuracy of ^{99m}Tc-Bicisate SPECT

The following table summarizes the improvement in diagnostic accuracy for identifying chronic cerebral infarction when using a combination of linearization and scatter-attenuation correction,

as compared to uncorrected images.[\[1\]](#)[\[2\]](#)

Metric	Uncorrected SPECT Images	Corrected SPECT Images (Linearization + Scatter-Attenuation)
Sensitivity	69.6%	79.5%
Specificity	91.4%	95.7%
Accuracy	73.0%	82.0%

Experimental Protocols & Workflows

Protocol 1: Radiochemical Purity (RCP) Quality Control using C18 Mini Cartridge

This protocol describes a rapid method for determining the RCP of ^{99m}Tc-bicisate.[\[3\]](#)

Materials:

- C18 Sep-Pak mini cartridge
- Sterile saline for injection
- Syringes and needles
- Dose calibrator or gamma counter

Methodology:

- Prepare the ^{99m}Tc-bicisate according to the manufacturer's instructions.
- Draw a small, known volume of the prepared radiopharmaceutical into a syringe.
- Pass the sample through the C18 mini cartridge. The lipophilic ^{99m}Tc-bicisate complex will be retained on the column.
- Elute the cartridge with sterile saline. Impurities, such as free pertechnetate, will be eluted.

- Measure the radioactivity remaining on the cartridge and the radioactivity in the eluent separately using a dose calibrator.
- Calculation:
 - $RCP (\%) = [Activity\ on\ Cartridge / (Activity\ on\ Cartridge + Activity\ in\ Eluent)] \times 100$
- Critical Note: Ensure a regular, not excessively fast, flow rate during elution, as a fast flow can result in a falsely low RCP reading.[\[3\]](#)

Protocol 2: Standardized Patient Injection and Uptake Procedure

This protocol outlines the steps to minimize environmental and psychological stimuli that can confound brain perfusion imaging results.[\[5\]](#)[\[8\]](#)

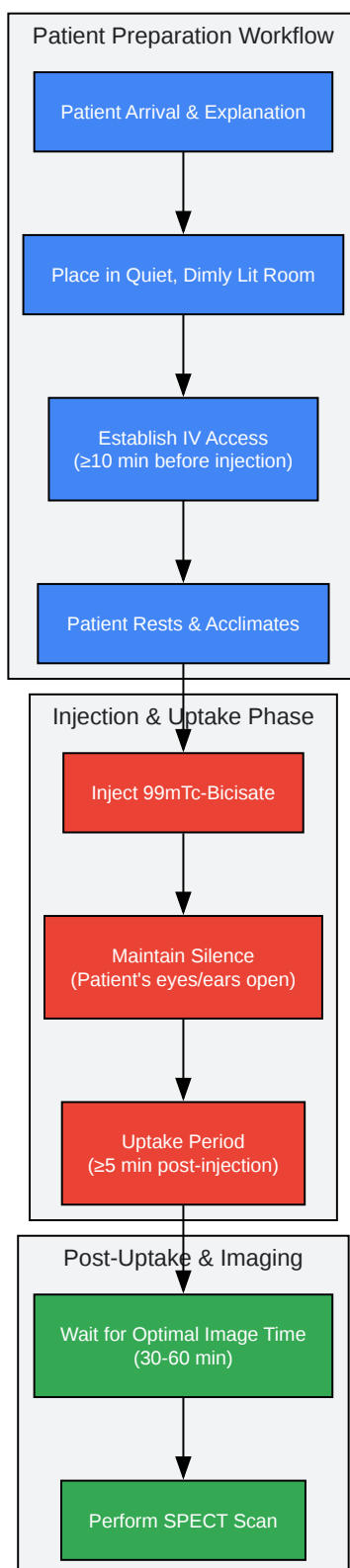
Objective: To achieve a true resting-state brain perfusion scan.

Methodology:

- Pre-Injection (10-15 minutes prior):
 - Escort the patient to a designated quiet, dimly lit room.
 - Explain the procedure briefly, emphasizing the need for quiet and stillness.
 - Have the patient sit or recline comfortably.
 - Place intravenous access and secure it. Allow the patient to rest for at least 10 minutes to acclimate.
- Injection and Uptake Phase (Injection time + 5 minutes):
 - Administer the prepared ^{99m}Tc -bicisate dose through the IV line.
 - Maintain a quiet environment. Do not speak to the patient.

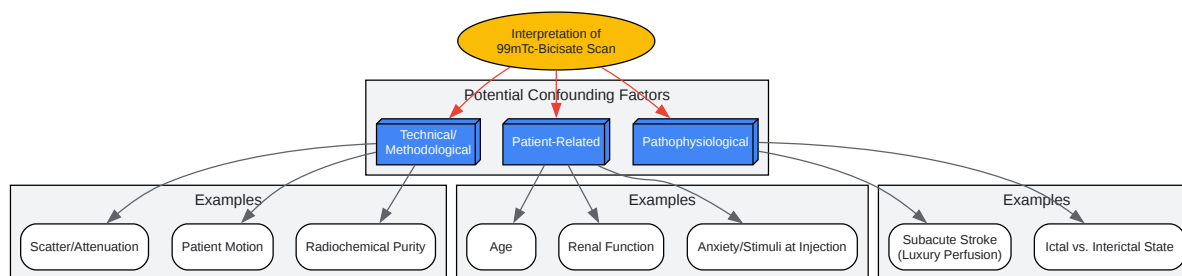
- Instruct the patient to keep their eyes and ears open but to not focus on any particular object, read, or talk.
- This quiet period should be maintained for a minimum of 5 minutes post-injection to allow for tracer uptake in the brain.
- Post-Uptake:
 - After the initial uptake phase, the patient may relax.
 - Encourage the patient to drink fluids and void frequently to minimize radiation dose to the bladder.[\[11\]](#)
 - Proceed to imaging after the recommended uptake time (optimal images are typically obtained 30-60 minutes post-injection).[\[11\]](#)

Visualizations



[Click to download full resolution via product page](#)

Caption: Standardized workflow for patient preparation and 99mTc-bicisate injection.



[Click to download full resolution via product page](#)

Caption: Logical relationship of confounding factors in 99mTc-bicisate scan interpretation.

Need Custom Synthesis?

BenchChem offers custom synthesis for rare earth carbides and specific isotopic labeling.

Email: info@benchchem.com or [Request Quote Online](#).

References

- 1. jsnm.org [jsnm.org]
- 2. Brain perfusion SPECT study with 99mTc-bicisate: clinical pitfalls and improved diagnostic accuracy with a combination of linearization and scatter-attenuation correction - PubMed [pubmed.ncbi.nlm.nih.gov]
- 3. Characterization and Quality Control Analysis of 99mTc-Bicisate | Journal of Nuclear Medicine Technology [tech.snmjournals.org]
- 4. mdpi.com [mdpi.com]
- 5. tech.snmjournals.org [tech.snmjournals.org]
- 6. med.emory.edu [med.emory.edu]
- 7. med.emory.edu [med.emory.edu]

- 8. snmmi.org [snmmi.org]
- 9. Normal patterns on 99mTc-ECD brain SPECT scans in adults - PubMed [pubmed.ncbi.nlm.nih.gov]
- 10. UpToDate 2018 [doctorabad.com]
- 11. pharmacyce.unm.edu [pharmacyce.unm.edu]
- 12. Technetium Tc 99m Bicisate - Drugs and Lactation Database (LactMed®) - NCBI Bookshelf [ncbi.nlm.nih.gov]
- 13. 99mTc-bicisate reliably images CBF in chronic brain diseases but fails to show reflow hyperemia in subacute stroke: report of a multicenter trial of 105 cases comparing 133Xe and 99mTc-bicisate (ECD, neurolite) measured by SPECT on same day - PubMed [pubmed.ncbi.nlm.nih.gov]
- 14. 99mTc-Bicisate and 99mTc-HMPAO SPECT Imaging in Early Spontaneous Reperfusion of Cerebral Embolism - PMC [pmc.ncbi.nlm.nih.gov]
- 15. Technetium 99mTc Bicisate [drugfuture.com]
- 16. 99mTc-bicisate and 99mTc-HMPAO SPECT imaging in early spontaneous reperfusion of cerebral embolism - PubMed [pubmed.ncbi.nlm.nih.gov]
- 17. Ictal and interictal technetium-99m-bicisate brain SPECT in children with refractory epilepsy - PubMed [pubmed.ncbi.nlm.nih.gov]
- 18. Identifying and troubleshooting the pitfalls of ictal/interictal brain perfusion SPECT studies - PubMed [pubmed.ncbi.nlm.nih.gov]
- To cite this document: BenchChem. [Confounding factors in the interpretation of 99mTc-bicisate scans]. BenchChem, [2025]. [Online PDF]. Available at: [https://www.benchchem.com/product/b606108#confounding-factors-in-the-interpretation-of-99mtc-bicisate-scans]

Disclaimer & Data Validity:

The information provided in this document is for Research Use Only (RUO) and is strictly not intended for diagnostic or therapeutic procedures. While BenchChem strives to provide accurate protocols, we make no warranties, express or implied, regarding the fitness of this product for every specific experimental setup.

Technical Support: The protocols provided are for reference purposes. Unsure if this reagent suits your experiment? [[Contact our Ph.D. Support Team for a compatibility check](#)]

Need Industrial/Bulk Grade? [Request Custom Synthesis Quote](#)

BenchChem

Our mission is to be the trusted global source of essential and advanced chemicals, empowering scientists and researchers to drive progress in science and industry.

Contact

Address: 3281 E Guasti Rd
Ontario, CA 91761, United States
Phone: (601) 213-4426
Email: info@benchchem.com