

# Technical Support Center: Overcoming Extra-Cardiac Uptake in Cardio-SPECT Imaging

**Author:** BenchChem Technical Support Team. **Date:** December 2025

## Compound of Interest

Compound Name: Cardio-Spect

Cat. No.: B570751

[Get Quote](#)

This technical support center provides troubleshooting guides and frequently asked questions (FAQs) to assist researchers, scientists, and drug development professionals in addressing the challenges of extra-cardiac radiotracer uptake in Single-Photon Emission Computed Tomography (SPECT) cardiac imaging.

## Frequently Asked Questions (FAQs) & Troubleshooting Guides

**Q1:** What are the common sources of extra-cardiac uptake in **Cardio-SPECT** imaging and why are they problematic?

**A1:** The most common sources of extra-cardiac uptake in myocardial perfusion imaging (MPI) using Technetium-99m (99mTc)-labeled tracers are the liver, gallbladder, and gastrointestinal (GI) tract.<sup>[1][2][3][4]</sup> This is because these tracers are cleared by the liver and excreted through the biliary system.<sup>[2][4]</sup> This uptake can be problematic as it can interfere with the visualization and quantitative analysis of the myocardial walls, particularly the inferior wall.<sup>[2][5]</sup> The "spillover" of activity from these adjacent organs can mask or mimic perfusion defects, potentially leading to inaccurate diagnoses.<sup>[2]</sup>

**Q2:** How does extra-cardiac uptake manifest as artifacts in SPECT images?

**A2:** Extra-cardiac activity can cause several artifacts. "Spillover" is a common artifact where photons from a "hot" extra-cardiac source are scattered and incorrectly detected as originating

from the myocardium, potentially obscuring a true perfusion defect.[2] Conversely, high uptake in an adjacent organ can sometimes lead to an apparent decrease in activity in the nearby myocardium, an artifact known as the "halo effect," especially when using filtered back-projection (FBP) reconstruction.[2][5] Iterative reconstruction methods, such as ordered subset expectation maximization (OSEM), are less prone to this latter artifact.[2]

Q3: What patient preparation strategies can minimize gut and liver uptake?

A3: Proper patient preparation is crucial for minimizing extra-cardiac uptake. Key strategies include:

- **Dietary Modifications:** For tracers like  $^{18}\text{F}$ -FDG used in PET imaging (which has similar uptake challenges), a high-fat, low-carbohydrate diet prior to imaging can suppress physiological myocardial uptake and potentially reduce interference from other tissues.[6][7][8][9] Some studies suggest that a fatty meal before  $^{99\text{mTc}}$ -sestamibi or  $^{99\text{mTc}}$ -tetrofosmin imaging can stimulate gallbladder contraction and clearance of the tracer from the liver and biliary system.[10]
- **Fasting:** While fasting is a standard preparation for many cardiac imaging procedures, its direct impact on reducing hepato-biliary uptake for SPECT MPI is not definitively proven, though it is often part of standard protocols.[11]
- **Hydration and Walking:** Encouraging the patient to drink water and walk around after tracer injection can help promote clearance of the radiotracer from the liver and GI tract.[12]
- **Pharmacological Intervention:** In some cases, pharmacological agents may be used to enhance clearance, although this is less common in routine clinical practice.[1]

Q4: Are there specific imaging acquisition or processing techniques to address extra-cardiac uptake?

A4: Yes, several techniques can be employed during and after image acquisition:

- **Delayed Imaging:** Acquiring images at a later time point after tracer injection can allow for further clearance of the radiotracer from the liver and gut, improving the heart-to-background ratio.[2][13]

- **Patient Positioning:** Imaging the patient in the prone position, in addition to the standard supine position, can sometimes help to separate the heart from underlying gut or liver activity.[\[13\]](#)
- **Image Reconstruction Algorithms:** As mentioned, iterative reconstruction algorithms like OSEM are generally more effective at handling artifacts from extra-cardiac activity compared to filtered backprojection.[\[2\]](#)
- **Scatter Correction:** Applying scatter correction during image reconstruction can significantly improve image contrast and reduce the impact of scattered photons from extra-cardiac sources.[\[14\]](#)
- **Attenuation Correction:** Using CT-based attenuation correction can improve the accuracy of the SPECT images by correcting for photon attenuation by different tissues, which can also help in better delineating the heart from surrounding structures.[\[15\]](#)
- **Specialized Software:** Novel image reconstruction methods, such as masking on unsmoothed images (MUS), have been developed to better separate the myocardium from adjacent extra-cardiac activity.[\[16\]](#)[\[17\]](#)

Q5: When is it necessary to repeat a SPECT acquisition due to high extra-cardiac uptake?

A5: A repeat acquisition may be necessary when the intensity of the extra-cardiac uptake is high enough to potentially compromise the diagnostic accuracy of the study. A study suggests that reacquisition is useful when the intensity of the extra-cardiac uptake is equal to or higher than the cardiac uptake, especially when there is no clear separation between the extra-cardiac source and the inferior wall of the heart.[\[2\]](#) Repeat imaging after a delay often shows improved image quality and can reduce the number of equivocal studies.[\[2\]](#)

## Experimental Protocols

### Patient Preparation Protocol for $^{99m}\text{Tc}$ -Sestamibi/Tetrofosmin SPECT MPI to Minimize Extra-Cardiac Uptake

- Patient Counseling: Instruct the patient on the importance of following the preparation guidelines to ensure optimal image quality.
- Fasting: The patient should fast for at least 4 hours prior to the study. Water is permitted.
- Caffeine and Medication Restriction: Patients should avoid caffeine for at least 12-24 hours before the administration of vasodilator stressors like adenosine or dipyridamole.[\[11\]](#)[\[18\]](#) Certain medications, such as beta-blockers and calcium channel blockers, may need to be withheld for a specific period before the stress test, as advised by the referring physician.[\[11\]](#)
- Stress Test: Perform either an exercise or pharmacological stress test according to established guidelines.[\[18\]](#)[\[19\]](#)[\[20\]](#)
- Radiotracer Injection: Inject the appropriate dose of 99mTc-sestamibi or 99mTc-tetrofosmin at peak stress.
- Post-Injection Interventions (to be implemented if high extra-cardiac uptake is anticipated or observed):
  - Hydration: Encourage the patient to drink one to two glasses of water.[\[12\]](#)
  - Ambulation: If the patient's condition allows, have them walk for 10-15 minutes.[\[12\]](#)
  - Fatty Meal/Drink: Administer a small fatty meal or a glass of whole milk approximately 15-30 minutes after tracer injection to promote hepato-biliary clearance.[\[5\]](#)[\[10\]](#) Note: The effectiveness of this can vary.[\[5\]](#)
- Image Acquisition: Begin SPECT imaging at the recommended time post-injection (e.g., 15-60 minutes for stress images, depending on the protocol and tracer).[\[13\]](#)
- Delayed Imaging (if necessary): If initial images show significant extra-cardiac interference, consider delayed imaging after an additional 30-60 minutes to allow for further clearance.[\[2\]](#)

## Data Presentation

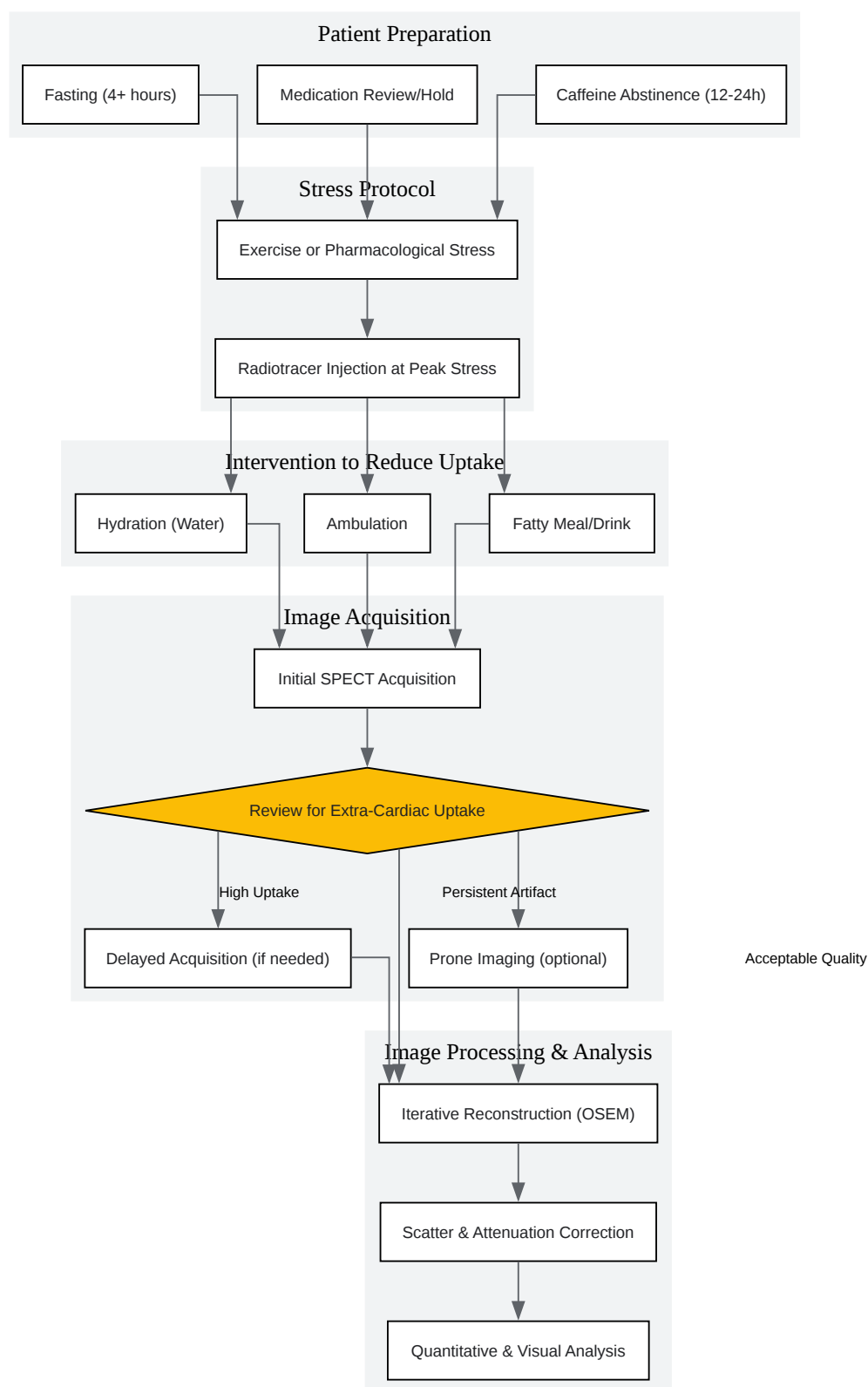
### Table 1: Summary of Interventions to Reduce Extra-Cardiac Uptake and Their Reported Effectiveness

Intervention	Mechanism of Action	Reported Effectiveness	Citations
Fatty Meal (e.g., whole milk)	Stimulates gallbladder contraction and biliary excretion.	Variable; some studies show improved image quality, while others find it insufficient, especially with attenuation correction.	<a href="#">[5]</a> <a href="#">[10]</a>
Drinking Water	Reduces gastric fundus activity and promotes transit of tracer through the bowel.	Can be as effective as a fatty meal and is easier for patients to tolerate.	<a href="#">[10]</a> <a href="#">[12]</a>
Walking/Light Exercise Post-Injection	Increases splanchnic blood flow and promotes GI motility.	Often used in combination with hydration; anecdotal evidence suggests effectiveness.	<a href="#">[12]</a>
Delayed Imaging	Allows for natural biological clearance of the tracer from the liver and gut.	Generally effective in improving image quality and reducing equivocal findings.	<a href="#">[2]</a> <a href="#">[13]</a>
Prone Imaging	Physically separates the heart from the liver and gut.	Can be effective in reducing artifacts from subdiaphragmatic activity.	<a href="#">[13]</a>
Pharmacological Agents (e.g., Erythromycin)	Can stimulate GI motility.	Investigated in some studies, but not a routine clinical practice.	

## Table 2: Impact of Image Reconstruction and Correction Techniques on Image Quality in the Presence of Extra-Cardiac Uptake

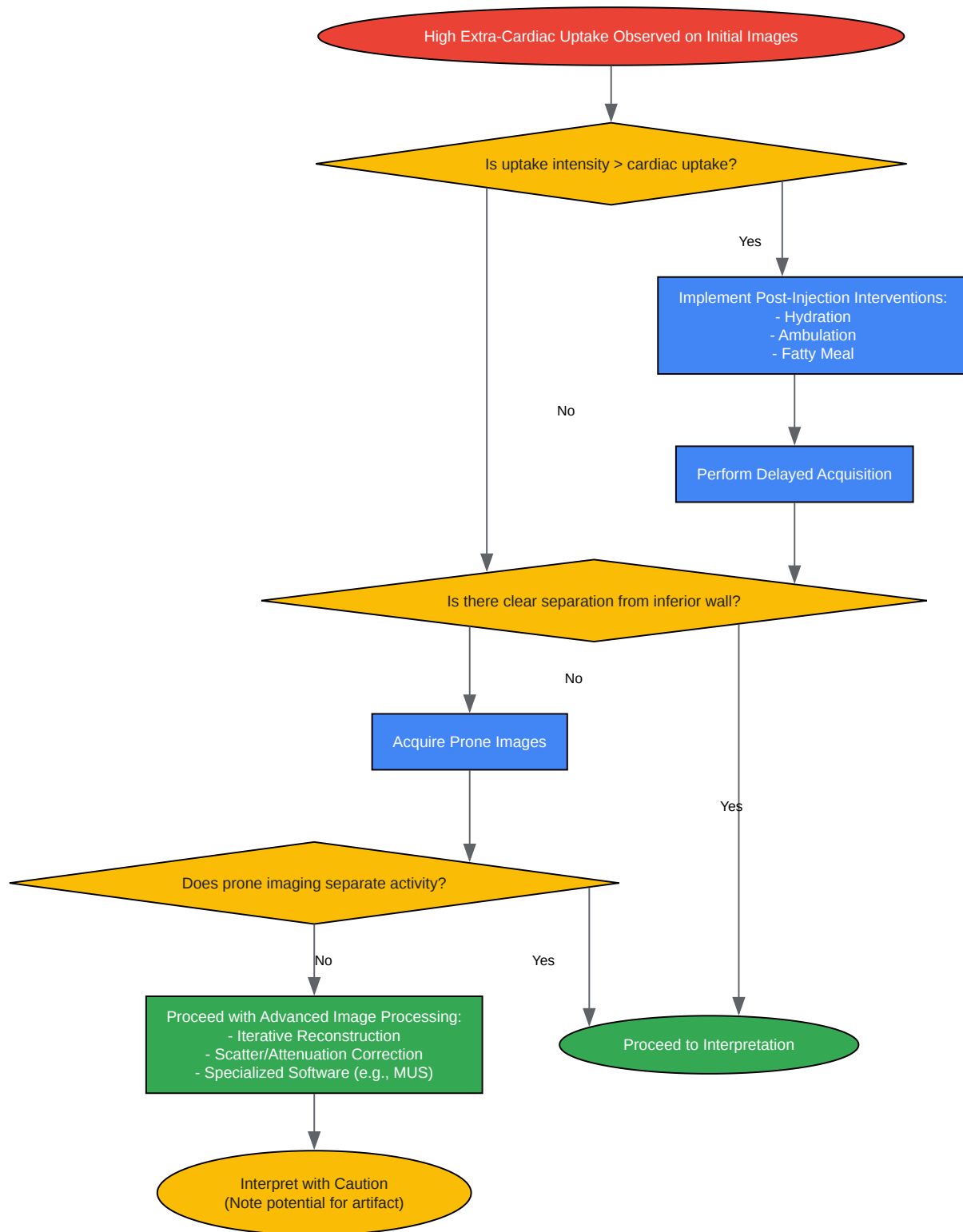
Technique	Impact on Image Quality	Key Findings	Citations
Iterative Reconstruction (e.g., OSEM)	Reduces "halo" artifacts compared to FBP.	Less susceptible to artifacts caused by high extra-cardiac activity.	[2]
Scatter Correction	Improves image contrast.	Significantly improves image contrast, even with high extra-cardiac activity.	[14]
Attenuation Correction (AC)	Improves image uniformity and contrast.	When combined with scatter correction and iterative reconstruction, leads to significant improvements in image quality.	[14]
Masking on Unsmoothed Images (MUS)	Enhances separation of extra-cardiac accumulation and improves inferior wall contrast.	Particularly effective when extra-cardiac activity is in close proximity to the myocardium.	[16][17]

## Mandatory Visualizations



[Click to download full resolution via product page](#)

Caption: Workflow for minimizing extra-cardiac uptake in **Cardio-SPECT**.



[Click to download full resolution via product page](#)

Caption: Troubleshooting logic for managing extra-cardiac uptake artifacts.



**Need Custom Synthesis?**

BenchChem offers custom synthesis for rare earth carbides and specific isotopic labeling.

Email: [info@benchchem.com](mailto:info@benchchem.com) or [Request Quote Online](#).

## References

- 1. The effects of pharmacological interventions, exercise, and dietary supplements on extra-cardiac radioactivity in myocardial perfusion single-photon emission computed tomography imaging - PubMed [pubmed.ncbi.nlm.nih.gov]
- 2. When is reacquisition necessary due to high extra-cardiac uptake in myocardial perfusion scintigraphy? - PMC [pmc.ncbi.nlm.nih.gov]
- 3. radiopaedia.org [radiopaedia.org]
- 4. tech.snmjournals.org [tech.snmjournals.org]
- 5. jnm.snmjournals.org [jnm.snmjournals.org]
- 6. Suppression of myocardial 18F-FDG uptake by preparing patients with a high-fat, low-carbohydrate diet - PubMed [pubmed.ncbi.nlm.nih.gov]
- 7. Suppression of myocardial 18F-FDG uptake with a preparatory "Atkins-style" low-carbohydrate diet - PubMed [pubmed.ncbi.nlm.nih.gov]
- 8. Suppression of Myocardial 18F-FDG Uptake Through Prolonged High-Fat, High-Protein, and Very-Low-Carbohydrate Diet Before FDG-PET/CT for Evaluation of Patients With Suspected Cardiac Sarcoidosis - PubMed [pubmed.ncbi.nlm.nih.gov]
- 9. ajronline.org [ajronline.org]
- 10. researchgate.net [researchgate.net]
- 11. emedicine.medscape.com [emedicine.medscape.com]
- 12. How to Reduce Gut Activity with Myocardial Perfusion Imaging [digirad.com]
- 13. med.emory.edu [med.emory.edu]
- 14. Does scatter correction of cardiac SPECT improve image quality in the presence of high extracardiac activity? - PubMed [pubmed.ncbi.nlm.nih.gov]
- 15. ahajournals.org [ahajournals.org]
- 16. A Novel Method to Suppress the Effect of Subdiaphragmatic Activity in 99mTc Myocardial Perfusion SPECT and Evaluation of Its Usefulness Using a Myocardial Phantom - PMC

[pmc.ncbi.nlm.nih.gov]

- 17. SPECT reconstruction using preprocessing masking for extra-cardiac uptake versus standard processing in 99mTc-sestamibi myocardial perfusion imaging - PubMed [pubmed.ncbi.nlm.nih.gov]
- 18. Patient centric performance and interpretation of SPECT and SPECT/CT myocardial perfusion imaging: a clinical consensus statement of the European Association of Cardiovascular Imaging of the ESC - PMC [pmc.ncbi.nlm.nih.gov]
- 19. asnc.org [asnc.org]
- 20. ASNC imaging guidelines for SPECT nuclear cardiology procedures: Stress, protocols, and tracers - PubMed [pubmed.ncbi.nlm.nih.gov]
- To cite this document: BenchChem. [Technical Support Center: Overcoming Extra-Cardiac Uptake in Cardio-SPECT Imaging]. BenchChem, [2025]. [Online PDF]. Available at: [https://www.benchchem.com/product/b570751#overcoming-challenges-of-extra-cardiac-uptake-in-cardio-spect-imaging]

---

#### Disclaimer & Data Validity:

The information provided in this document is for Research Use Only (RUO) and is strictly not intended for diagnostic or therapeutic procedures. While BenchChem strives to provide accurate protocols, we make no warranties, express or implied, regarding the fitness of this product for every specific experimental setup.

**Technical Support:** The protocols provided are for reference purposes. Unsure if this reagent suits your experiment? [[Contact our Ph.D. Support Team for a compatibility check](#)]

**Need Industrial/Bulk Grade?** [Request Custom Synthesis Quote](#)

## BenchChem

Our mission is to be the trusted global source of essential and advanced chemicals, empowering scientists and researchers to drive progress in science and industry.

#### Contact

Address: 3281 E Guasti Rd

Ontario, CA 91761, United States

Phone: (601) 213-4426

Email: [info@benchchem.com](mailto:info@benchchem.com)