

Unveiling Kidney Health: A Comparative Guide on Mertiatide Renal Uptake and Histopathology

Author: BenchChem Technical Support Team. **Date:** December 2025

Compound of Interest

Compound Name: Mertiatide

Cat. No.: B549169

[Get Quote](#)

For researchers, scientists, and drug development professionals, the accurate assessment of renal function and underlying pathology is paramount. This guide provides a comprehensive comparison of a key functional imaging parameter, **Mertiatide** (99mTc-MAG3) renal uptake, with the gold standard of renal assessment, histopathological analysis. By examining the experimental data and protocols, this document aims to illuminate the cross-validation between these two essential methodologies in evaluating kidney health.

Technetium-99m **Mertiatide** (99mTc-MAG3) renal scintigraphy is a widely utilized non-invasive imaging technique that provides a quantitative measure of renal function, primarily reflecting tubular secretion. Histopathological examination of a kidney biopsy, on the other hand, offers a direct microscopic view of the tissue, allowing for the precise grading of structural damage. Understanding the correlation between the functional data from MAG3 scans and the structural findings from biopsies is crucial for a holistic view of renal pathophysiology.

Quantitative Correlation: Mertiatide Uptake vs. Histopathological Scores

While extensive research has been conducted on renal transplant patients, data directly correlating quantitative **Mertiatide** uptake with histopathological findings in a broad spectrum of native kidney diseases is an evolving area of study. However, studies in specific patient populations and preclinical models have demonstrated a strong relationship between diminished renal function as measured by MAG3 scintigraphy and the severity of histological damage.

A pivotal study in the context of renal allografts provides a framework for this comparison. Although focused on transplant recipients, the methodology and findings offer valuable insights. In this study, parameters from MAG3 renograms were correlated with a histopathology score derived from renal biopsy findings.

Table 1: Correlation of MAG3 Renogram Parameters with Histopathology Score in Renal Allograft Dysfunction[1]

MAG3 Renogram Parameter	Correlation with Histopathology Score (r-value)	p-value
Perfusion Score	0.234	0.052
Function (Uptake) Score	-	-
Resistive Index (Ultrasound)	0.435	<0.001

Note: While a direct correlation for a quantitative uptake score was not provided in this specific table, the study found that patients with reduced uptake (Function Score > 0) had a tendency towards a higher mean histopathology score ($p < 0.06$)[1].

In preclinical studies, animal models of kidney disease have consistently shown a strong correlation between reduced MAG3 uptake and the extent of histopathological damage, such as tubular necrosis, interstitial fibrosis, and inflammation. For instance, in a rabbit model of unilateral ureteral obstruction, decreased MAG3 uptake in the obstructed kidney corresponded with histological evidence of interstitial inflammation, collecting tubule dilation, and atrophy[2]. Similarly, in a murine model of ischemia-reperfusion injury, dynamic MAG3 imaging detected significant renal dysfunction that correlated with histological changes of acute tubular necrosis[3].

Experimental Protocols

A standardized approach to both **Mertiatide** renal scintigraphy and histopathological evaluation is essential for reliable cross-validation. The following protocols outline the key steps in these procedures.

Mertiatide (99mTc-MAG3) Renal Scintigraphy Protocol

This protocol describes a standardized method for performing a quantitative MAG3 renal scan.

- Patient Preparation:
 - Ensure the patient is well-hydrated. Oral or intravenous hydration is often administered prior to the scan to ensure adequate urine flow.
 - Patients should void immediately before the imaging procedure begins.
 - Certain medications, such as ACE inhibitors and diuretics, may need to be withheld, depending on the clinical question.
- Radiopharmaceutical Administration:
 - An intravenous bolus of 99mTc-MAG3 is administered. The typical adult dose ranges from 185 to 370 MBq (5 to 10 mCi).
- Image Acquisition:
 - Dynamic imaging is initiated immediately upon injection using a large field-of-view gamma camera positioned posteriorly over the kidneys.
 - Sequential images are acquired for 20-30 minutes. A common protocol involves acquiring rapid 1-2 second frames for the first minute to assess perfusion, followed by 15-30 second frames for the remainder of the study to evaluate uptake and excretion.
- Quantitative Analysis of Renal Uptake:
 - Regions of interest (ROIs) are drawn around each kidney and in a background region (subrenal or perirenal).
 - Time-activity curves (renograms) are generated for each kidney after background subtraction.
 - The renal uptake can be quantified in several ways, including:

- **Relative Uptake:** The integral of the background-corrected counts in each kidney over a 1 to 2-minute interval post-injection is used to determine the percentage of total function contributed by each kidney.
- **Uptake Slope:** The initial slope of the renogram curve is proportional to the effective renal plasma flow.
- **Camera-based Clearance Methods:** Various formulas can be applied to the renogram data to estimate MAG3 clearance in ml/min.

Histopathological Analysis of Renal Biopsy

This protocol outlines the standard procedure for processing and scoring a renal biopsy to assess chronic changes.

- **Biopsy Acquisition:**
 - A core needle biopsy of the renal cortex is obtained, typically under ultrasound guidance.
- **Tissue Processing:**
 - The tissue is fixed in formalin, processed, and embedded in paraffin.
 - Thin sections (2-4 μm) are cut and stained with various histological stains, including:
 - **Hematoxylin and Eosin (H&E):** For general morphology.
 - **Periodic acid-Schiff (PAS):** To highlight basement membranes and mesangial matrix.
 - **Masson's Trichrome:** To visualize collagen and identify interstitial fibrosis.
 - **Jones Methenamine Silver:** To assess the glomerular basement membrane.
- **Semi-Quantitative Scoring:**
 - A renal pathologist examines the stained sections under a microscope.
 - Key histopathological features are scored semi-quantitatively. A common scoring system for chronic changes is based on the percentage of the cortical area affected.

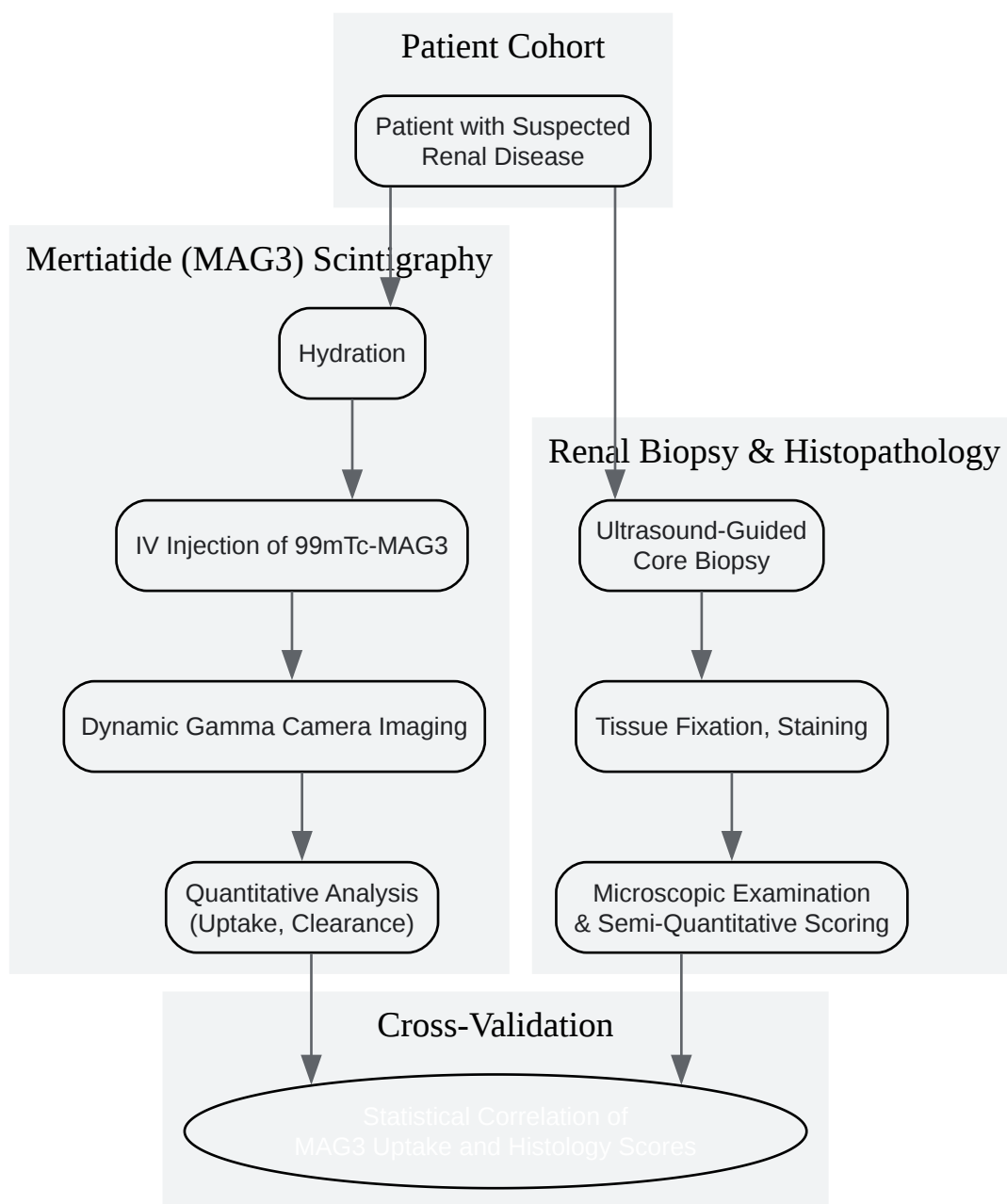
Table 2: Example of a Semi-Quantitative Scoring System for Interstitial Fibrosis and Tubular Atrophy (IFTA)

Score	Percentage of Cortical Area Affected
0	<10%
1	10-25%
2	26-50%
3	>50%

This scoring system can be applied to other features such as glomerulosclerosis and interstitial inflammation.

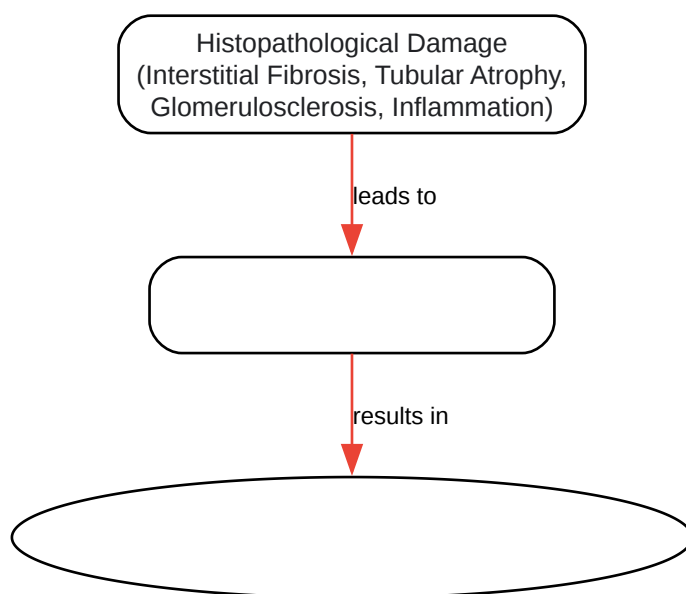
Visualizing the Workflow and Pathophysiological Link

To better understand the relationship between these methodologies, the following diagrams illustrate the experimental workflow and the logical connection between reduced **Mertiatide** uptake and underlying histopathological damage.



[Click to download full resolution via product page](#)

Experimental Workflow Diagram.



[Click to download full resolution via product page](#)

Pathophysiological Link Diagram.

Conclusion

The cross-validation of **Mertiatide** renal uptake with histopathological findings provides a powerful approach to understanding kidney disease. While MAG3 scintigraphy offers a non-invasive, quantitative assessment of renal tubular function, histopathology reveals the underlying structural abnormalities. The correlation between these two modalities, particularly the association of reduced **Mertiatide** uptake with increased severity of interstitial fibrosis and tubular atrophy, underscores the clinical utility of MAG3 scans in reflecting the degree of chronic kidney damage. For researchers and drug development professionals, integrating quantitative MAG3 imaging as a biomarker in preclinical and clinical studies can provide valuable, non-invasive insights into the efficacy of novel therapies aimed at preserving renal function and preventing structural deterioration. Further research focusing on the direct quantitative correlation in various native kidney diseases will continue to refine our understanding and enhance the diagnostic and prognostic power of this synergistic approach.

Need Custom Synthesis?

BenchChem offers custom synthesis for rare earth carbides and specific isotopic labeling.

Email: info@benchchem.com or [Request Quote Online](#).

References

- 1. Interstitial inflammation and interstitial fibrosis and tubular atrophy predict renal survival in lupus nephritis - PMC [pmc.ncbi.nlm.nih.gov]
- 2. academic.oup.com [academic.oup.com]
- 3. auajournals.org [auajournals.org]
- To cite this document: BenchChem. [Unveiling Kidney Health: A Comparative Guide on Mertiatide Renal Uptake and Histopathology]. BenchChem, [2025]. [Online PDF]. Available at: [https://www.benchchem.com/product/b549169#cross-validation-of-mertiatide-renal-uptake-with-histopathological-findings]

Disclaimer & Data Validity:

The information provided in this document is for Research Use Only (RUO) and is strictly not intended for diagnostic or therapeutic procedures. While BenchChem strives to provide accurate protocols, we make no warranties, express or implied, regarding the fitness of this product for every specific experimental setup.

Technical Support: The protocols provided are for reference purposes. Unsure if this reagent suits your experiment? [[Contact our Ph.D. Support Team for a compatibility check](#)]

Need Industrial/Bulk Grade? [Request Custom Synthesis Quote](#)

BenchChem

Our mission is to be the trusted global source of essential and advanced chemicals, empowering scientists and researchers to drive progress in science and industry.

Contact

Address: 3281 E Guasti Rd

Ontario, CA 91761, United States

Phone: (601) 213-4426

Email: info@benchchem.com