

Technical Support Center: Arytenoidectomy in BVFP Treatment

Author: BenchChem Technical Support Team. **Date:** December 2025

Compound of Interest

Compound Name: BVFP

Cat. No.: B5387700

[Get Quote](#)

This technical support center provides researchers, scientists, and drug development professionals with essential information for troubleshooting and navigating the complexities of arytenoidectomy in the treatment of Bilateral Vocal Fold Paralysis (**BVFP**).

Frequently Asked Questions (FAQs)

Q1: What are the most common complications observed in experimental models following arytenoidectomy for **BVFP**?

A1: The most frequently encountered complications in preclinical and clinical research include granulation tissue formation at the surgical site, scar tissue formation leading to glottic stenosis, aspiration, and significant changes in vocal function.[1][2] Postoperative swelling is also a concern and, in rare cases, can lead to airway obstruction.[3]

Q2: What is the reported success rate of arytenoidectomy in terms of decannulation?

A2: The success of arytenoidectomy, as measured by the decannulation rate, is generally high. A systematic review and meta-analysis reported a decannulation rate of 92% for endolaryngeal arytenoidectomy.[4][5][6] When combined with posterior cordectomy, the rate can be as high as 98%.[4][5][6]

Q3: Are there significant differences in outcomes between total and partial arytenoidectomy?

A3: Both total and partial arytenoidectomy have shown similar outcomes concerning phonation and swallowing.[1] However, partial arytenoidectomy is often favored in primary cases to be more conservative, with total arytenoidectomy reserved for revision surgeries.[1] Partial arytenoidectomy may have an advantage in preserving the height of the arytenoid cartilage, which can help reduce the risk of aspiration.[1]

Q4: What are the key considerations for choosing an appropriate animal model for arytenoidectomy research?

A4: The choice of an animal model depends on the specific research question. Canine models are frequently used for studying laryngeal paralysis and surgical interventions due to anatomical similarities to humans.[7] Rabbit models are also utilized for investigating vocal fold injury and healing.[8] Key considerations include the size of the larynx for surgical manipulation, the ability to perform functional voice assessments, and the ethical considerations of the experimental protocol.

Q5: How can granulation tissue formation be minimized in an experimental setting?

A5: Minimizing granulation tissue involves meticulous surgical technique to reduce tissue trauma and the use of mucosa-sparing techniques.[1] Preserving mucosal flaps to cover raw surgical areas can decrease the risk of granulation tissue formation.[1] Additionally, postoperative administration of anti-reflux medication can reduce inflammation from laryngopharyngeal reflux, which may contribute to granulation.[1]

Troubleshooting Guides

Issue 1: Excessive Granulation Tissue Formation Post-Arytenoidectomy

Symptom/Observation	Potential Cause	Troubleshooting/Mitigation Strategy
Obstructive granulation tissue at the surgical site, leading to respiratory distress in the animal model.	- Excessive tissue trauma during surgery.- Exposed cartilage.- Laryngopharyngeal reflux.	- Refine surgical technique to minimize thermal damage if using a laser.- Ensure complete mucosal coverage of the surgical wound.- Administer proton pump inhibitors or other anti-reflux medications postoperatively.
Recurrence of granulation tissue after removal.	- Underlying inflammatory response.- Incomplete initial removal.	- Consider local application of corticosteroids.- Ensure complete excision of the granulation tissue with clear margins.- Investigate and manage potential sources of chronic irritation.

Issue 2: Post-Surgical Aspiration

Symptom/Observation	Potential Cause	Troubleshooting/Mitigation Strategy
Evidence of aspiration pneumonia in the animal model (e.g., on necropsy or imaging).	- Overly aggressive resection of the arytenoid cartilage, leading to an incompetent glottis.- Impaired laryngeal sensation.	- Opt for partial arytenoidectomy to preserve arytenoid height and sensation.[9]- Perform a thorough preoperative assessment of swallowing function to identify at-risk subjects.- Implement post-operative dietary modifications (e.g., thickened liquids) in relevant models.
Difficulty with swallowing observed post-procedure.	- Edema and inflammation from the surgery.	- Administer anti-inflammatory medication post-operatively.- Allow for a sufficient recovery period for swelling to subside.

Issue 3: Unexpected Voice Changes or Lack of Improvement

Symptom/Observation	Potential Cause	Troubleshooting/Mitigation Strategy
Significant deterioration of voice quality beyond what is expected.	- Damage to the membranous vocal fold during surgery.- Excessive scarring and stiffening of the vocal fold.	- Employ surgical techniques that preserve the integrity of the vocal fold.- Consider post-operative voice therapy protocols adapted for the animal model.- Investigate therapeutic agents that modulate vocal fold scarring.
Inadequate airway improvement despite arytenoidectomy.	- Insufficient tissue removal.- Formation of scar tissue leading to glottic stenosis.	- Re-evaluate the extent of the initial resection.- Consider revision surgery if significant scarring has occurred.- Prophylactically explore anti-fibrotic therapies in the experimental design.

Data Presentation

Table 1: Comparison of Decannulation and Revision Surgery Rates for Different **BVFP** Surgical Techniques

Surgical Technique	Decannulation Rate (95% CI)	Revision Surgery Rate (95% CI)
Endolaryngeal Arytenoidectomy	0.92 (0.86–0.96)	0.06 (0.01–0.28)
External Arytenoidectomy	0.94 (0.71–0.99)	0.08 (0.01–0.53)
Posterior Cordectomy	0.97 (0.94–0.99)	Not Reported
Posterior Cordectomy & Arytenoidectomy	0.98 (0.93–0.99)	Not Reported
Laterofixation	0.95 (0.91–0.97)	0.11 (0.04–0.23)
Arytenoid Abduction	0.93 (0.86–0.97)	0.06 (0.02–0.13)

Data extracted from a systematic review and meta-analysis.[\[4\]](#)[\[5\]](#)[\[6\]](#)

Experimental Protocols

Protocol 1: Induction of BVFP and Subsequent Laser Arytenoidectomy in a Canine Model

Objective: To create a reliable model of **BVFP** and perform a partial arytenoidectomy to assess outcomes.

Materials:

- Adult canine subjects
- General anesthesia and intubation equipment
- Laryngoscope
- CO2 laser with a micro-manipulator
- Surgical microscope
- Standard laryngeal surgical instruments

Procedure:

- Induction of **BVFP**:
 - Anesthetize and intubate the canine subject.
 - Under microscopic guidance, identify and transect the recurrent laryngeal nerves bilaterally.
 - Confirm vocal fold paralysis via laryngoscopy.
 - Allow for a recovery period of at least 6 weeks to ensure chronic paralysis.
- Laser Partial Arytenoidectomy:
 - Re-anesthetize and intubate the subject.
 - Perform suspension laryngoscopy to expose the glottis.
 - Using the CO2 laser, make a precise incision over the vocal process of the arytenoid.
 - Carefully ablate the vocal process and a portion of the body of the arytenoid cartilage, preserving the muscular process and the main body for laryngeal framework support.[\[1\]](#)
 - Create a medially based mucosal flap to cover the exposed cartilage, minimizing the risk of granulation tissue formation.[\[1\]](#)
 - Assess the glottic airway post-ablation to ensure adequate widening.
- Post-operative Care and Assessment:
 - Monitor for respiratory distress and signs of aspiration.
 - Perform endoscopic evaluations at set time points (e.g., 1, 3, and 6 months) to assess for granulation tissue, scarring, and airway patency.[\[7\]](#)
 - Conduct functional voice analysis if applicable to the research goals.

Protocol 2: Histological Assessment of Vocal Fold Scarring

Objective: To quantify the degree of fibrosis in laryngeal tissue following experimental arytenoidectomy.

Materials:

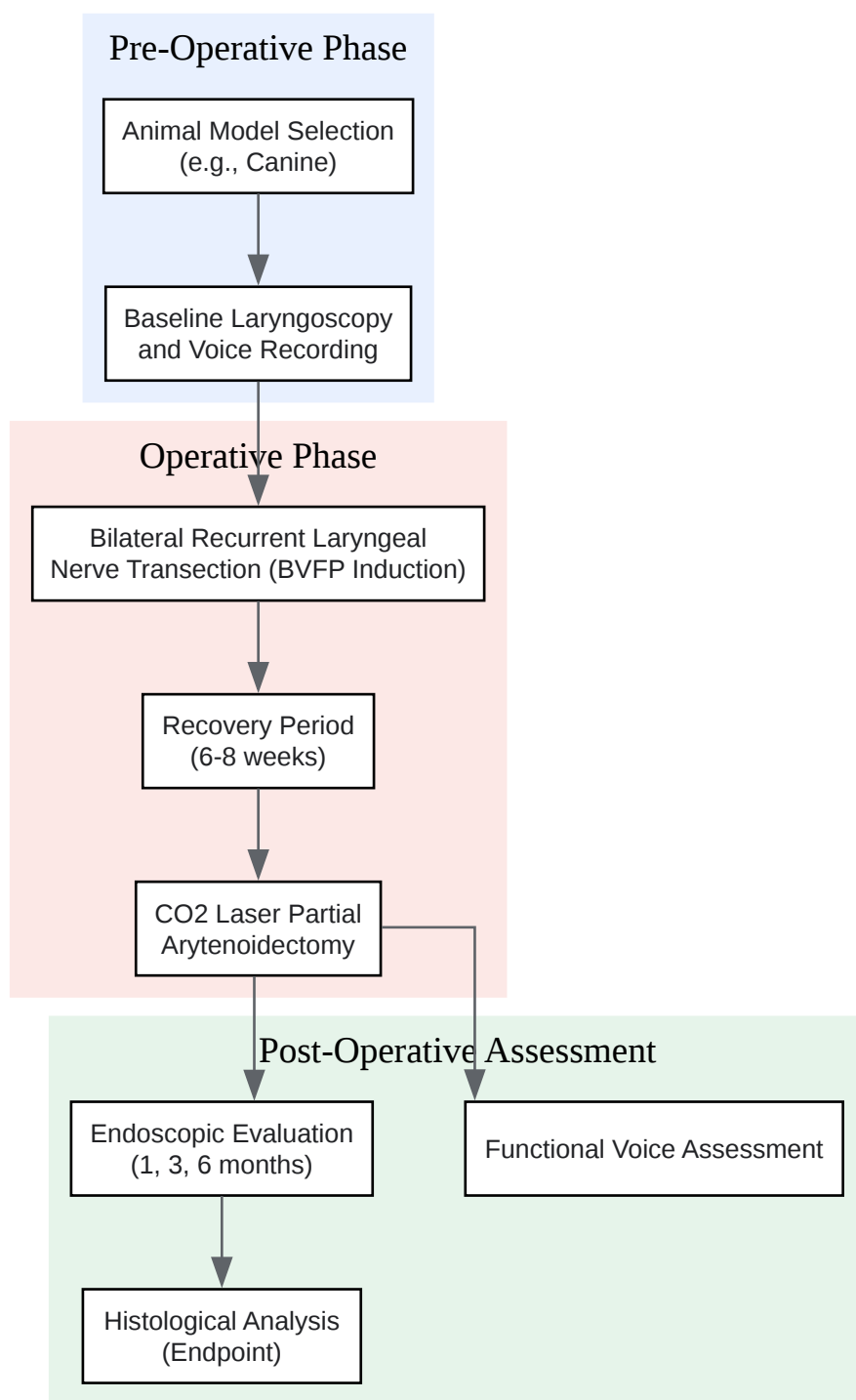
- Laryngeal tissue samples
- Formalin or other appropriate fixative
- Paraffin embedding station
- Microtome
- Masson's Trichrome stain
- Picrosirius Red stain
- Microscope with a digital camera
- Image analysis software

Procedure:

- Tissue Preparation:
 - Harvest the larynx from the euthanized animal model at the experimental endpoint.
 - Fix the tissue in 10% neutral buffered formalin for 24-48 hours.
 - Dehydrate the tissue through a graded series of ethanol, clear with xylene, and embed in paraffin.
 - Section the tissue at 5 μ m thickness using a microtome.
- Staining:

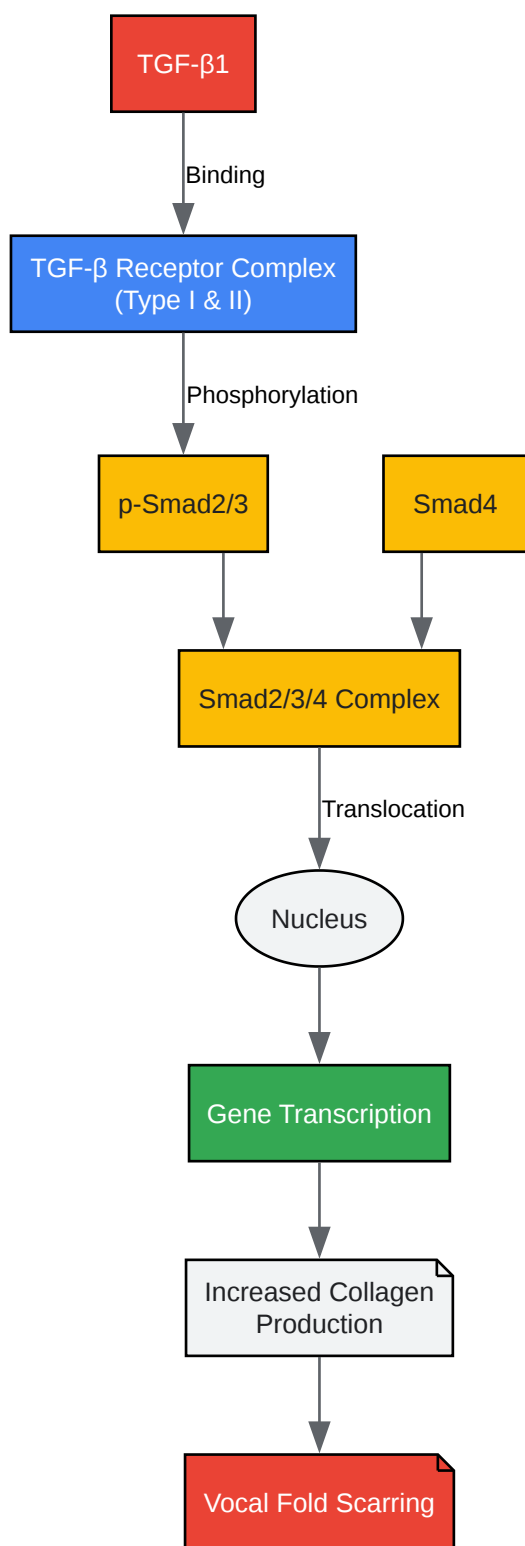
- Masson's Trichrome: Stain sections to differentiate collagen (blue/green) from muscle and cytoplasm (red).
- Picrosirius Red: Stain sections and visualize under polarized light to assess collagen fiber organization and density.
- Analysis:
 - Capture high-resolution images of the stained sections.
 - Using image analysis software, quantify the area of collagen deposition relative to the total tissue area in the lamina propria of the vocal fold.
 - Assess the organization and thickness of collagen fibers.
 - Compare the findings between experimental and control groups.

Mandatory Visualizations



[Click to download full resolution via product page](#)

Caption: Experimental workflow for studying arytenoidectomy in a **BVFP** animal model.



[Click to download full resolution via product page](#)

Caption: TGF-β signaling pathway in vocal fold scarring.

Need Custom Synthesis?

BenchChem offers custom synthesis for rare earth carbides and specific isotopic labeling.

Email: info@benchchem.com or [Request Quote Online](#).

References

- 1. Total and Partial Laser Arytenoidectomy for Bilateral Vocal Fold Paralysis - PMC [pmc.ncbi.nlm.nih.gov]
- 2. researchgate.net [researchgate.net]
- 3. Arytenoidectomy: Definition, risks, and outlook [medicalnewstoday.com]
- 4. Surgery for bilateral vocal fold paralysis: Systematic review and meta-analysis - PMC [pmc.ncbi.nlm.nih.gov]
- 5. db-thuringen.de [db-thuringen.de]
- 6. Surgery for bilateral vocal fold paralysis: Systematic review and meta-analysis - PubMed [pubmed.ncbi.nlm.nih.gov]
- 7. Video-assisted left partial arytenoidectomy by diode laser photoablation for treatment of canine laryngeal paralysis - PubMed [pubmed.ncbi.nlm.nih.gov]
- 8. Numerical and experimental investigations on vocal fold approximation in healthy and simulated unilateral vocal fold paralysis - PMC [pmc.ncbi.nlm.nih.gov]
- 9. Efficacy of Arytenoidectomy after Suture Lateralisation Failure in Patients with Bilateral Vocal Cord Paralysis - PMC [pmc.ncbi.nlm.nih.gov]
- To cite this document: BenchChem. [Technical Support Center: Arytenoidectomy in BVFP Treatment]. BenchChem, [2025]. [Online PDF]. Available at: [https://www.benchchem.com/product/b5387700#reducing-complications-of-arytenoidectomy-in-bvfp-treatment]

Disclaimer & Data Validity:

The information provided in this document is for Research Use Only (RUO) and is strictly not intended for diagnostic or therapeutic procedures. While BenchChem strives to provide accurate protocols, we make no warranties, express or implied, regarding the fitness of this product for every specific experimental setup.

Technical Support: The protocols provided are for reference purposes. Unsure if this reagent suits your experiment? [[Contact our Ph.D. Support Team for a compatibility check](#)]

Need Industrial/Bulk Grade? [Request Custom Synthesis Quote](#)

BenchChem

Our mission is to be the trusted global source of essential and advanced chemicals, empowering scientists and researchers to drive progress in science and industry.

Contact

Address: 3281 E Guasti Rd
Ontario, CA 91761, United States
Phone: (601) 213-4426
Email: info@benchchem.com