

Iofetamine (^{123}I) SPECT Technical Support Center: Optimizing Injection-to-Imaging Time

Author: BenchChem Technical Support Team. **Date:** May 2026

Compound of Interest

Compound Name: *Iofetamine hydrochloride*

CAS No.: *116316-03-1*

Cat. No.: *B048988*

[Get Quote](#)

Welcome to the technical support center for Iofetamine (^{123}I -IMP) SPECT imaging. This guide is designed for researchers, scientists, and drug development professionals to provide in-depth, field-proven insights into optimizing cerebral perfusion studies. Here, we move beyond standard protocols to explain the causality behind experimental choices, ensuring your experiments are built on a foundation of scientific integrity.

Frequently Asked Questions (FAQs)

This section addresses foundational questions about Iofetamine kinetics and general imaging principles.

Q1: What is the fundamental principle of Iofetamine (^{123}I -IMP) brain imaging?

A1: Iofetamine is a lipid-soluble radiopharmaceutical analogue of amphetamine.[1] Following intravenous injection, it rapidly crosses the blood-brain barrier and distributes throughout the brain in proportion to regional cerebral blood flow (rCBF).[2] Its initial distribution provides a "snapshot" of perfusion at the time of injection. The ^{123}I isotope emits gamma rays that are detected by a SPECT camera to create a three-dimensional map of brain perfusion.[1]

Q2: What are the key pharmacokinetic phases of lofetamine that influence imaging time?

A2: Understanding the three key phases is critical for protocol optimization:

- **First-Pass Extraction & Lung Uptake:** Immediately after injection, lofetamine is rapidly taken up by the lungs, which act as a temporary reservoir.[3][4] This initial lung uptake influences the rate at which the tracer becomes available to the brain.[5]
- **Brain Uptake:** The tracer is then released from the lungs and undergoes high first-pass extraction into the brain, reaching peak activity approximately 30-60 minutes post-injection. [3] Brain activity reaches about 90% of its maximum by 20 minutes.[5]
- **Washout and Redistribution:** Unlike agents like ^{99m}Tc -HMPAO or ^{99m}Tc -ECD which remain trapped, lofetamine exhibits significant washout or "redistribution" over time.[6] This means the tracer does not remain fixed, and images acquired at different time points can show different patterns of activity, a feature that is critically important in cerebrovascular studies.

Q3: Why is the patient's environment during injection so critical?

A3: The initial distribution of lofetamine reflects the cerebral blood flow at the moment of injection. Therefore, the patient's physiological and neurological state must be carefully controlled. For baseline perfusion studies (e.g., dementia evaluation), the patient should be in a quiet, dimly lit room, with eyes open, and should refrain from speaking or reading for at least 5 minutes post-injection to avoid activating specific cortical areas and creating artifactual "hot spots".[7] For epilepsy studies, this principle is leveraged to capture the altered perfusion state during a seizure.

Condition-Specific Protocol Optimization

The optimal injection-to-imaging window for lofetamine is not a single value but is highly dependent on the clinical question being investigated.

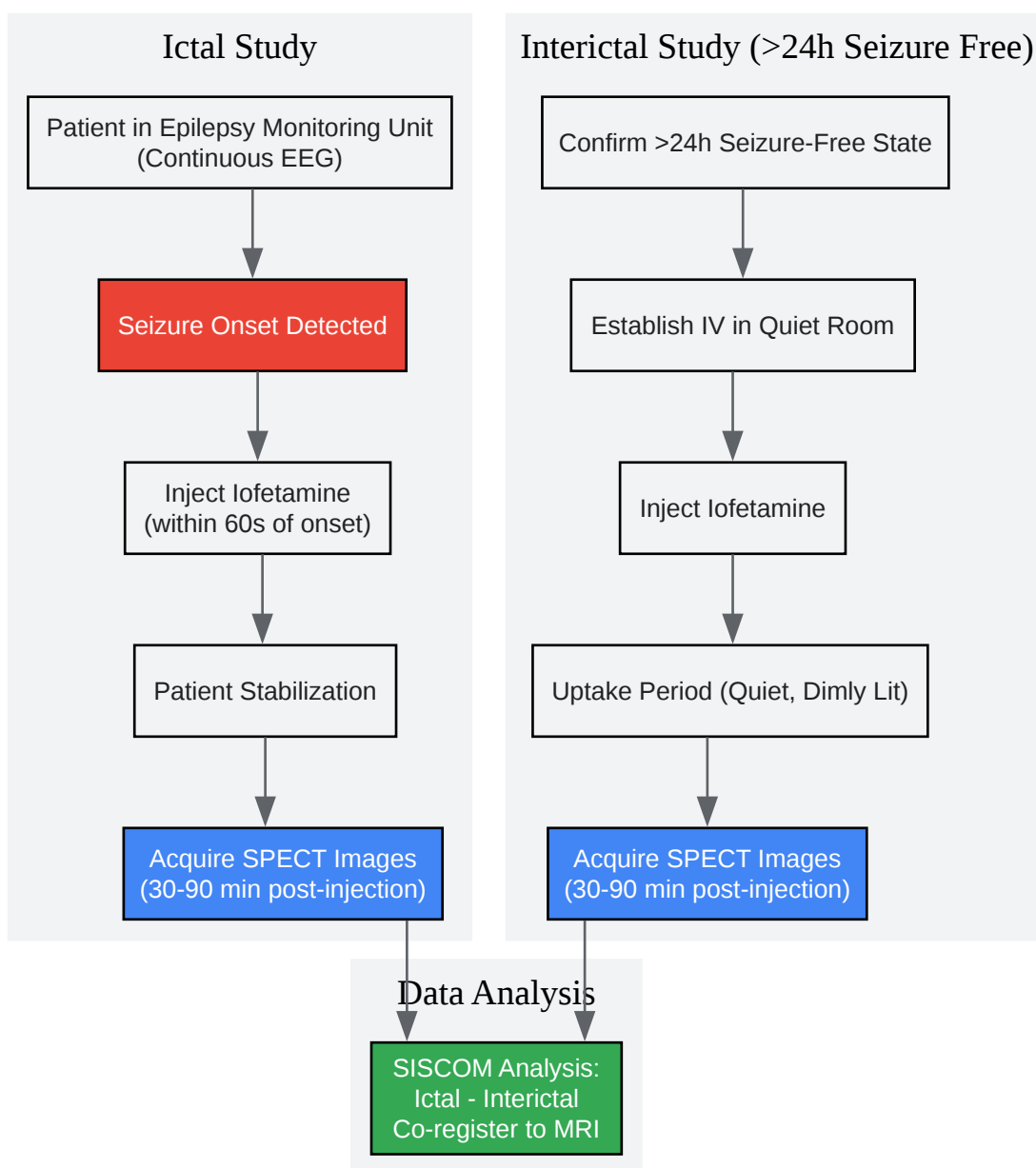
Epilepsy: Seizure Focus Localization

The goal in epilepsy imaging is to identify the epileptogenic zone by comparing cerebral perfusion during a seizure (ictal) with the baseline state (interictal).

- Ictal Protocol: The tracer must be injected as close to the onset of a seizure as possible, ideally within 60 seconds.[8] This requires a dedicated epilepsy monitoring unit where the patient is under continuous EEG monitoring and staff are prepared to inject immediately.[9] The hyperperfusion at the seizure focus is captured by the tracer. Since the initial tracer uptake is rapid, imaging can be performed after the patient is stabilized, typically 30 to 90 minutes post-injection.[1][7]
- Interictal Protocol: This scan serves as the baseline for comparison. It is crucial that the patient be truly interictal. The injection should occur after a prolonged seizure-free period, typically at least 24 hours.[9] The imaging time window is similar to the ictal scan: 30 to 90 minutes post-injection.

The process of subtracting the interictal scan from the ictal scan and co-registering it to an MRI (a technique known as SISCOM) is invaluable for precise localization.[9]

Below is a workflow diagram for a typical epilepsy study.



[Click to download full resolution via product page](#)

Caption: Ictal vs. Interictal SPECT Workflow for Epilepsy.

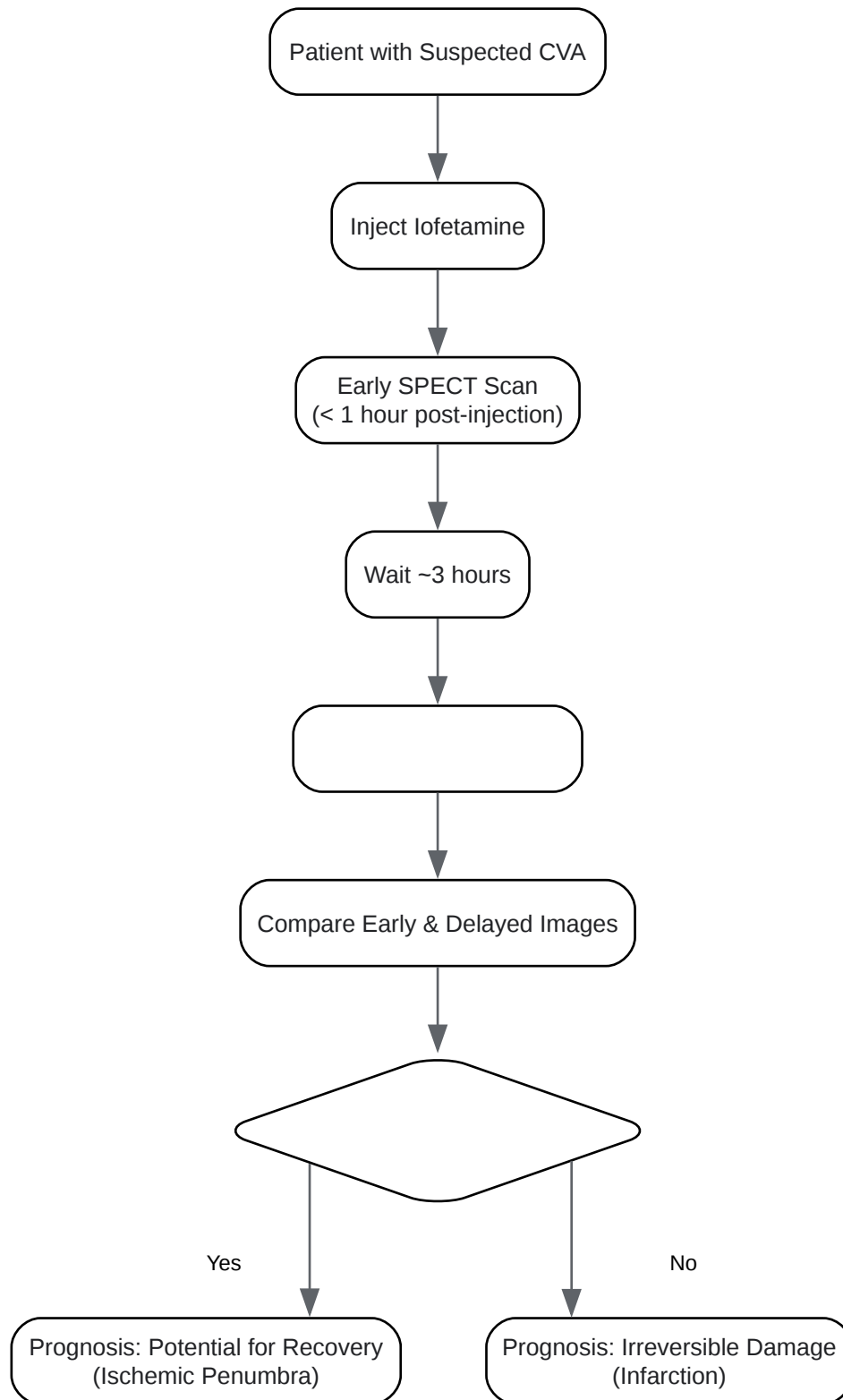
Cerebrovascular Disease: Assessing Perfusion and Viability

In stroke and transient ischemic attacks (TIAs), Iofetamine's redistribution property is a key diagnostic and prognostic feature. This necessitates a dual-scan protocol.

- Early Scan: Acquired within the first hour post-injection (some studies use a 20-minute time point), this scan reflects the initial cerebral blood flow at the time of the event.[\[6\]](#)[\[10\]](#) It will show a perfusion defect (a "cold" spot) in the ischemic area.
- Delayed Scan: Acquired approximately 4 hours post-injection, this scan assesses for redistribution.[\[6\]](#)[\[10\]](#)

The comparison between early and delayed scans provides critical information about tissue viability:

- No Redistribution: The defect remains unchanged. This suggests irreversible damage (infarction).
- Redistribution ("Fill-in"): The initially "cold" spot shows increased tracer activity on the delayed scan. This indicates that while initial blood flow was compromised, the tissue is still viable (ischemic penumbra) and may have better potential for recovery.[\[6\]](#)[\[11\]](#) The amplitude of this redistribution has been shown to correlate significantly with clinical outcome.[\[6\]](#)



[Click to download full resolution via product page](#)

Caption: Iofetamine Dual-Scan Workflow for Cerebrovascular Disease.

Dementia: Evaluating Perfusion Patterns

For neurodegenerative disorders like Alzheimer's disease, the goal is to identify characteristic patterns of hypoperfusion.

- **Optimal Imaging Window:** Unlike stroke, redistribution is not the primary focus. The key is to image when brain uptake is maximal and stable, providing the best contrast between normal and hypoperfused regions. Studies indicate the optimal imaging window is 30 to 60 minutes post-injection.[3] Imaging during this period has shown high sensitivity (88%) and specificity (87%) for diagnosing Alzheimer's disease. In Alzheimer's, this typically reveals bilateral temporoparietal hypoperfusion.[3]

Quantitative Data Summary

The choice of imaging agent impacts kinetics and image quality. Iofetamine (IMP) shows different characteristics compared to the more commonly used Technetium-99m agents.

Table 1: Pharmacokinetic Comparison of Brain Perfusion SPECT Agents

Parameter	¹²³ I-Iofetamine (IMP)	^{99m} Tc-HMPAO (Exametazime)	^{99m} Tc-ECD (Bicisate)
Brain Uptake Kinetics	Peaks at 30-60 min[3]	Rapid uptake, stable after minutes	Rapid uptake, stable after minutes
Redistribution	Significant washout & redistribution[6]	Minimal to no redistribution	Minimal to no redistribution
Recommended Scan Time	Condition-dependent (20 min - 4 hr)[5][6]	30-90 min post-injection[7]	30-60 min post-injection[7]
Gray/White Matter Ratio	Good	Good	Excellent
Primary Clearance	Renal	Hepatobiliary & Renal	Primarily Renal

Data synthesized from multiple sources for comparative purposes.[3][5][6][7][12][13]

Troubleshooting Guide & Advanced FAQs

Q4: My images show high lung and low brain counts. What happened and how can I fix it?

A4: This is a classic sign of delayed lung clearance of lofetamine. High initial uptake in the lungs is normal, but a slow release will delay the peak availability of the tracer to the brain.[5]

- Causality: This can be influenced by patient-specific factors, including certain pulmonary disorders or altered physiology.[14][15] The mechanism is thought to be related to nonspecific binding sites in the lung endothelium.[4][16]
- Troubleshooting: If you observe this pattern on early images, the best course of action is to perform delayed imaging. As the tracer eventually clears the lungs, brain uptake will increase. Delaying the scan to 60-90 minutes may yield a better brain-to-background ratio. There is a significant positive correlation between the clearance half-time in the lung and the time to reach maximum activity in the brain.[5]

Q5: We injected the tracer 5 minutes after a seizure ended (post-ictally). How does this affect interpretation?

A5: A post-ictal injection can be challenging to interpret and may not yield the classic hyperperfusion pattern of a true ictal scan. Immediately following a seizure, blood flow can decrease profoundly, leading to a hypoperfusion pattern at the seizure focus.[8] This can sometimes mimic an interictal scan or even show a "flipped" pattern. It is critical to document the exact time of injection relative to seizure onset and termination. While not ideal, a post-ictal scan can still provide useful information, but it must be interpreted with caution and in the context of all other clinical data (EEG, MRI).[8]

Q6: Can I use lofetamine to perform a quantitative cerebral blood flow (qCBF) study?

A6: Yes, but it is more complex than with other agents due to the tracer's redistribution. Quantitative methods have been developed that use a two-compartment model and require dynamic SPECT scanning with arterial blood sampling to generate an input function.[17][18] Simpler methods using a standard input function and a single blood sample have also been validated, with an optimal scan mid-time of 30-40 minutes post-injection.[17] These methods correct for the tracer clearance and can provide reliable rCBF values.[17]

Q7: What are common image artifacts to watch for during acquisition?

A7: Beyond the biological factors discussed, technical artifacts are a major source of error.

- **Patient Motion:** This is one of the most common artifacts and can blur images, creating artificial defects.^[5] Ensure the patient is comfortable and use head restraints. Gated SPECT can sometimes help correct for motion.
- **Attenuation:** Photons are attenuated by the skull and soft tissues, which can mimic perfusion defects. This is particularly true for deeper brain structures. Modern systems with CT-based attenuation correction can significantly mitigate this issue.
- **Center of Rotation (COR) Errors:** Improper alignment of the camera heads can lead to ring artifacts and loss of resolution. Regular quality control checks are essential to prevent this.

References

- Druckenbrod, R. W., Williams, C. C., & Gelfand, M. J. (1989). **Iofetamine hydrochloride I 123:** a new radiopharmaceutical for cerebral perfusion imaging. *DICP*, 23(1), 19–24. [\[Link\]](#)
- Matsuda, H., Kinuya, K., Higashi, S., Yokoyama, K., & Kuwabara, Y. (2000). Redistribution in I-123 N-isopropyl-p iodoamphetamine single-photon emission computed tomography in cerebrovascular disease and the effects of rehabilitation. *Nuclear Medicine Communications*, 21(1), 47-52. [\[Link\]](#)
- Vallabhajosula, S., Zimmerman, R. E., & Goldsmith, S. J. (1987). N-isopropyl-123I-p-iodoamphetamine uptake mechanism in the lung--is it dependent on pH, lipophilicity or pKa? *Nuclear Medicine and Biology*, 14(5), 491-493. [\[Link\]](#)
- Winchell, H. S., Horst, W. D., Braun, L., Oldendorf, W. H., Hattner, R., & Parker, H. (1980). N-isopropyl-[123I] p-iodoamphetamine: single-pass brain uptake and washout; binding to brain synaptosomes; and localization in dog and monkey brain. *Journal of Nuclear Medicine*, 21(10), 947-952. [\[Link\]](#)
- Delecluse, F., Voorde, F. V., de Roo, M., & van den Bergh, R. (1990). Early and delayed SPECT using N-isopropyl p-iodoamphetamine iodine 123 in cerebral ischemia. A prognostic index for clinical recovery. *Stroke*, 21(7), 1017-1021. [\[Link\]](#)

- Kosuda, S., Kawahara, S., Ishibashi, A., Tamura, K., Kubo, A., & Hashimoto, S. (1990). [Experimental study on N-isopropyl-p-iodoamphetamine lung uptake]. *Kaku Igaku*, 27(2), 149-153. [[Link](#)]
- Sumida, K., Yonekura, Y., Senda, M., Saji, H., Iwasaki, Y., Torizuka, T., ... & Konishi, J. (1988). Temporal changes in accumulation of N-isopropyl-p-iodoamphetamine in human brain: relation to lung clearance. *Journal of Nuclear Medicine*, 29(10), 1683-1689. [[Link](#)]
- Hirose, Y., Hayashida, K., Ishida, Y., Takamiya, M., & Nishimura, T. (1995). Clinical and experimental studies on the mechanism of abnormal accumulation in lung scanning with 123I-IMP. *Annals of Nuclear Medicine*, 9(3), 131-136. [[Link](#)]
- Hellman, R. S., Tikofsky, R. S., Collier, B. D., Hoffmann, R. G., Palmer, D. W., Glatt, S. L., ... & Isitman, A. T. (1989). Alzheimer disease: quantitative analysis of I-123-iodoamphetamine SPECT brain imaging. *Radiology*, 172(1), 183-188. [[Link](#)]
- Touho, H., Karasawa, J., Shishido, H., Morisako, T., & Uehara, T. (1990). Early and delayed imaging with 123I-IMP SPECT in patients with ischemic cerebrovascular disease. *Annals of Nuclear Medicine*, 4(3), 83-88. [[Link](#)]
- Johnson, K. A., Holman, B. L., Rosen, T. J., Nagel, J. S., English, R. J., & Growdon, J. H. (1990). Iofetamine I 123 single photon emission computed tomography is accurate in the diagnosis of Alzheimer's disease. *Archives of Internal Medicine*, 150(4), 752-756. [[Link](#)]
- Iida, H., Itoh, H., Nakazawa, M., Hatazawa, J., Nishizawa, S., Uemura, K., & Kanno, I. (1994). Quantitative mapping of regional cerebral blood flow using iodine-123-IMP and SPECT. *Journal of Nuclear Medicine*, 35(12), 2019-2030. [[Link](#)]
- Weber, D. A., Cabahug, C., Klieger, P., Volkow, N. D., Wong, C., Sacker, D., & Ivanovic, M. (1991). Effects of visual stimulation on the redistribution of iodine-123-IMP in the brain using SPECT imaging. *Journal of Nuclear Medicine*, 32(10), 1866-1872. [[Link](#)]
- Epilepsy Foundation. (2017). SPECT | Brain Imaging. [[Link](#)]
- Wikipedia. (2023). Iofetamine (123I). [[Link](#)]

- Ito, H., Kanno, I., Iida, H., Hatazawa, J., Itoh, H., & Uemura, K. (1994). A method to quantitate cerebral blood flow using a rotating gamma camera and iodine-123 iodoamphetamine with one blood sampling. *European Journal of Nuclear Medicine*, 21(10), 1056-1064. [[Link](#)]
- Tatum, W. O., T., F., S., M., M., L., S., G., ... & L., P. (1990). Initial experience with SPECT imaging of the brain using I-123 p-iodoamphetamine in focal epilepsy. *Epilepsia*, 31(2), 161-167. [[Link](#)]
- Ito, H., Inoue, K., Goto, R., Kinomura, S., Taki, Y., Okada, K., ... & Fukuda, H. (2006). Database of normal human cerebral blood flow measured by SPECT: I. Comparison between I-123-IMP, Tc-99m-HMPAO, and Tc-99m-ECD as referred with O-15 labeled water PET and voxel-based morphometry. *Annals of Nuclear Medicine*, 20(2), 131-138. [[Link](#)]
- Ikeda, H., Komatsu, M., Takahashi, K., Yasui, S., & Mariko, M. (1990). [Analysis of 123I IMP retention in the lung and application to the diagnosis of lung disease]. *Rinsho Hoshasen*, 35(2), 243-247. [[Link](#)]
- Guedj, E., Varrone, A., Boellaard, R., Albert, N. L., Barthel, H., van Berckel, B., ... & Kapucu, Ö. L. (2021). EANM procedure guideline for brain perfusion SPECT using 99mTc-labelled radiopharmaceuticals, version 2. *European Journal of Nuclear Medicine and Molecular Imaging*, 48(3), 634-651. [[Link](#)]
- Walovitch, R. C., Williams, S. J., LaFrance, N. D., & Ell, P. J. (1991). Intrasubject comparison between technetium-99m-ECD and technetium-99m-HMPAO in healthy human subjects. *Journal of Nuclear Medicine*, 32(9), 1752-1758. [[Link](#)]
- Weber, D. A., Franceschi, D., Ivanovic, M., Atkins, H. L., Cabahug, C., Wong, C. T., & Susskind, H. (1993). SPECT and planar brain imaging in crack abuse: iodine-123-iodoamphetamine uptake and localization. *Journal of Nuclear Medicine*, 34(6), 899-907. [[Link](#)]
- AuntMinnie.com. (2003). PET, SPECT guide pre-op seizure localization in epilepsy. [[Link](#)]
- University of New Mexico School of Medicine. (2017). Brain SPECT Protocol. [[Link](#)]

- Guedj, E., Varrone, A., Boellaard, R., Albert, N. L., Barthel, H., van Berckel, B., ... & Morbelli, S. (2022). SNMMI Procedure Standard/EANM Practice Guideline for Brain [18F]FDG PET Imaging version 2.0. *Journal of Nuclear Medicine*, 63(1), 154-165. [[Link](#)]
- Sone, T., Fukunaga, M., & Otsuka, N. (1999). Experimental investigation of I-123 iodoamphetamine in the detection of lung cancer. *Lung Cancer*, 25(1), 1-6. [[Link](#)]
- Al-Saeigh, A., & D'haese, P. F. (2023). Advancing stroke diagnosis and management through nuclear medicine: a systematic review of clinical trials. *Annals of Medicine and Surgery*, 83(1), 1-13. [[Link](#)]
- Ito, H., Inoue, K., Goto, R., Kinomura, S., Taki, Y., Okada, K., ... & Fukuda, H. (2006). Database of normal human cerebral blood flow measured by SPECT: I. Comparison between I-123-IMP, Tc-99m-HMPAO, and Tc-99m-ECD as referred with O-15 labeled water PET and voxel-based morphometry. *Annals of Nuclear Medicine*, 20(2), 131-138. [[Link](#)]
- University of New Mexico School of Medicine. (n.d.). Brain DaTscan® (I-123 Ioflupane) SPECT Protocol. [[Link](#)]
- Purdue University. (n.d.). Stroke Diagnosis and Management Today. [[Link](#)]
- CorHealth Ontario. (2023). Acute Stroke Imaging Protocol for Endovascular Treatment. [[Link](#)]
- Walovitch, R. C., Williams, S. J., LaFrance, N. D., & Ell, P. J. (1991). Intrasubject comparison between technetium-99m-ECD and technetium-99m-HMPAO in healthy human subjects. *ResearchGate*. [[Link](#)]
- Ito, H., Inoue, K., Goto, R., Kinomura, S., Taki, Y., Okada, K., ... & Fukuda, H. (2006). Database of normal human cerebral blood flow measured by SPECT: I. Comparison between I-123-IMP, Tc-99m-HMPAO, and Tc-99m-ECD as referred with O-15 labeled water PET and voxel-based morphometry. *J-STAGE*. [[Link](#)]

Need Custom Synthesis?

BenchChem offers custom synthesis for rare earth carbides and specific isotopic labeling.

Email: info@benchchem.com or [Request Quote Online](#).

Sources

- [1. SPECT Imaging of Epilepsy: An Overview and Comparison with F-18 FDG PET - PMC \[pmc.ncbi.nlm.nih.gov\]](#)
- [2. N-isopropyl-\[123I\] p-iodoamphetamine: single-pass brain uptake and washout; binding to brain synaptosomes; and localization in dog and monkey brain - PubMed \[pubmed.ncbi.nlm.nih.gov\]](#)
- [3. Alzheimer disease: quantitative analysis of I-123-iodoamphetamine SPECT brain imaging - PubMed \[pubmed.ncbi.nlm.nih.gov\]](#)
- [4. \[Experimental study on N-isopropyl-p-iodoamphetamine lung uptake\] - PubMed \[pubmed.ncbi.nlm.nih.gov\]](#)
- [5. radiology.wisc.edu \[radiology.wisc.edu\]](#)
- [6. Early and delayed SPECT using N-isopropyl p-iodoamphetamine iodine 123 in cerebral ischemia. A prognostic index for clinical recovery - PubMed \[pubmed.ncbi.nlm.nih.gov\]](#)
- [7. nucleanord.fr \[nucleanord.fr\]](#)
- [8. auntminnie.com \[auntminnie.com\]](#)
- [9. epilepsy.com \[epilepsy.com\]](#)
- [10. Early and delayed imaging with 123I-IMP SPECT in patients with ischemic cerebrovascular disease - PubMed \[pubmed.ncbi.nlm.nih.gov\]](#)
- [11. Redistribution in I-123 N-isopropyl-p iodoamphetamine single-photon emission computed tomography in cerebrovascular disease and the effects of rehabilitation - PubMed \[pubmed.ncbi.nlm.nih.gov\]](#)
- [12. Database of normal human cerebral blood flow measured by SPECT: I. Comparison between I-123-IMP, Tc-99m-HMPAO, and Tc-99m-ECD as referred with O-15 labeled water PET and voxel-based morphometry - PubMed \[pubmed.ncbi.nlm.nih.gov\]](#)
- [13. Intrasubject comparison between technetium-99m-ECD and technetium-99m-HMPAO in healthy human subjects - PubMed \[pubmed.ncbi.nlm.nih.gov\]](#)
- [14. Clinical and experimental studies on the mechanism of abnormal accumulation in lung scanning with 123I-IMP - PubMed \[pubmed.ncbi.nlm.nih.gov\]](#)
- [15. \[Analysis of 123I IMP retention in the lung and application to the diagnosis of lung disease\] - PubMed \[pubmed.ncbi.nlm.nih.gov\]](#)
- [16. N-isopropyl-123I-p-iodoamphetamine uptake mechanism in the lung--is it dependent on pH, lipophilicity or pKa? - PubMed \[pubmed.ncbi.nlm.nih.gov\]](#)

- [17. Quantitative mapping of regional cerebral blood flow using iodine-123-IMP and SPECT - PubMed \[pubmed.ncbi.nlm.nih.gov\]](#)
- [18. A method to quantitate cerebral blood flow using a rotating gamma camera and iodine-123 iodoamphetamine with one blood sampling - PubMed \[pubmed.ncbi.nlm.nih.gov\]](#)
- To cite this document: BenchChem. [Iofetamine (¹²³I) SPECT Technical Support Center: Optimizing Injection-to-Imaging Time]. BenchChem, [2026]. [Online PDF]. Available at: [<https://www.benchchem.com/product/b048988/docs#iofetamine-i-spect-technical-support-center-optimizing-injection-to-imaging-time>]

Disclaimer & Data Validity:

The information provided in this document is for Research Use Only (RUO) and is strictly not intended for diagnostic or therapeutic procedures. While BenchChem strives to provide accurate protocols, we make no warranties, express or implied, regarding the fitness of this product for every specific experimental setup.

Technical Support: The protocols provided are for reference purposes. Unsure if this reagent suits your experiment?

Need Industrial/Bulk Grade? [Request Custom Synthesis Quote](#)

BenchChem

Our mission is to be the trusted global source of essential and advanced chemicals, empowering scientists and researchers to drive progress in science and industry.

Contact

Address: 3281 E Guasti Rd
Ontario, CA 91761, United States
Phone: (601) 213-4426
Email: info@benchchem.com

[Contact our Ph.D. Support Team for a compatibility check](#)

