

Validating MRI Findings with Histopathology in Bromethalin Toxicosis: A Comparative Guide

Author: BenchChem Technical Support Team. **Date:** December 2025

Compound of Interest

Compound Name: Promurit

Cat. No.: B042284

[Get Quote](#)

For Researchers, Scientists, and Drug Development Professionals

This guide provides a comprehensive comparison of Magnetic Resonance Imaging (MRI) findings with histopathological evidence in cases of bromethalin toxicosis. Bromethalin, a potent neurotoxin found in some rodenticides, induces a characteristic spongiform leukoencephalomyelopathy. Understanding the correlation between non-invasive imaging and cellular-level pathology is crucial for accurate diagnosis, prognosis, and the development of potential therapeutic interventions. While existing research is primarily based on case reports in veterinary medicine, the findings offer valuable insights into the pathophysiology of this toxicosis.

Correlation of MRI and Histopathological Findings

MRI is a valuable antemortem diagnostic tool for bromethalin intoxication, with specific sequences showing a strong correlation with postmortem histopathological findings.^{[1][2][3]} The hallmark of bromethalin toxicosis is intramyelinic edema, which manifests as distinct changes on MRI that are confirmed by microscopic examination of central nervous system (CNS) tissue.^{[1][2]}

MRI Finding	Corresponding Histopathological Feature	Description of Correlation	Supporting Evidence
T2-Weighted (T2W) & T2-FLAIR Hyperintensity	Spongy Degeneration / Vacuolation of White Matter	The increased signal intensity on T2W and T2-FLAIR images directly corresponds to the fluid accumulation within the myelin sheaths, which appears as vacuoles or a "spongy" change on histopathology. [1] [2] [4] This is a consistent finding across affected white matter tracts. [1] [2]	Case studies in both felines and canines have demonstrated a clear topographical match between the areas of T2 hyperintensity and the histologically confirmed spongy degeneration. [1] [5]
Diffusion-Weighted Imaging (DWI) Hyperintensity	Intramyelinic Edema	The high signal intensity on DWI indicates restricted diffusion of water molecules. In bromethalin toxicosis, this is attributed to the trapping of fluid within the split myelin lamellae, a characteristic of intramyelinic edema. [1] [2] [4]	DWI has been highlighted as instrumental in raising the clinical suspicion of bromethalin poisoning, with findings being consistent with cytotoxic or intramyelinic edema. [1] [4]
Apparent Diffusion Coefficient (ADC) Hypointensity	Intramyelinic Edema	A corresponding decrease in the ADC values confirms the restricted diffusion seen on DWI. This	The presence of restricted diffusion on DWI with corresponding ADC hypointensity is a key

combination of high	feature that helps
DWI signal and low	differentiate
ADC signal is a strong	bromethalin toxicosis
indicator of	from other
intramyelinic edema	leukoencephalopathie
rather than vasogenic	s.[2][4]
edema.[1][2]	

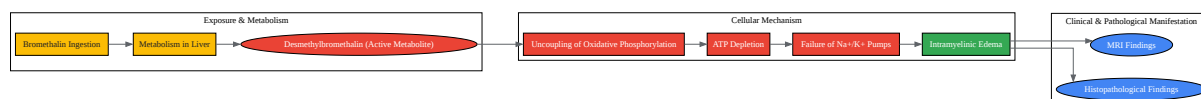
Experimental Protocols

The following table summarizes the typical methodologies employed in the studies that form the basis of our current understanding of bromethalin toxicosis imaging and pathology. It is important to note that as these are primarily clinical case reports, the protocols are not from controlled experimental studies.

Aspect	MRI Protocol	Histopathology Protocol
Subjects	Canines and felines with suspected bromethalin exposure presenting with neurological signs.[1][4][5]	Postmortem tissue from canines and felines with confirmed bromethalin exposure.[1][4][5]
Imaging Equipment	1.5T or 3T MRI scanners.	Light microscopy.
Key Sequences	T2-Weighted (T2W), T2-Fluid-Attenuated Inversion Recovery (T2-FLAIR), Diffusion-Weighted Imaging (DWI), and Apparent Diffusion Coefficient (ADC) maps.[1][2][4]	Hematoxylin and Eosin (H&E) staining.[6] In some cases, special stains for myelin (e.g., Luxol Fast Blue) may be used.
Procedure	Animals are anesthetized and placed in the MRI scanner. Scans of the brain and sometimes the spinal cord are acquired.	Brain and spinal cord are fixed in formalin, embedded in paraffin, sectioned, and stained for microscopic examination.
Analysis	Radiologists assess the images for signal abnormalities in the white matter across the different sequences.	Pathologists examine the stained tissue sections for evidence of spongy degeneration, vacuolation, and intramyelinic edema.

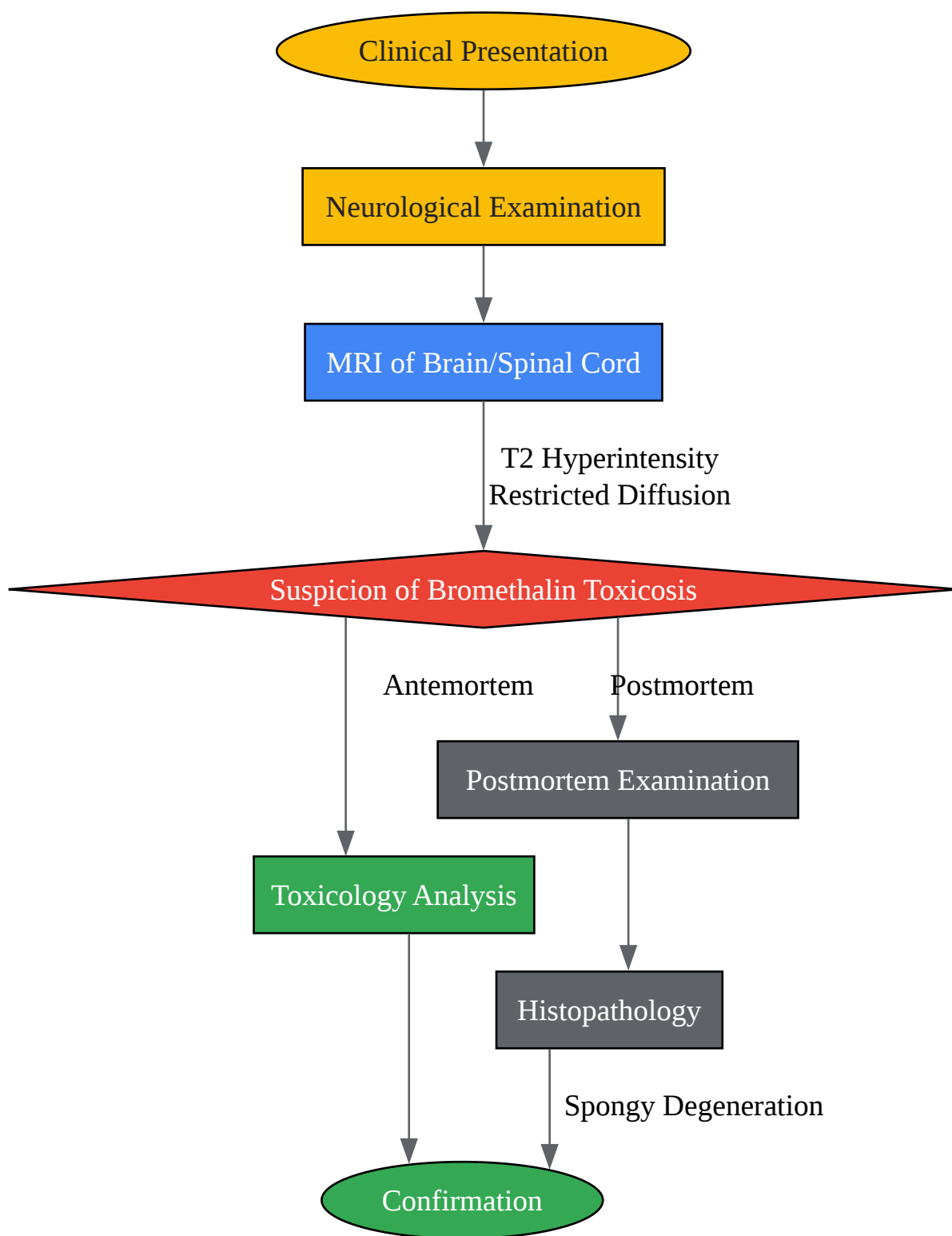
Visualizing the Pathophysiology and Diagnostic Workflow

To further elucidate the relationship between bromethalin's mechanism of action and the resulting pathology, as well as the typical diagnostic workflow, the following diagrams are provided.



[Click to download full resolution via product page](#)

Caption: Pathophysiological cascade of bromethalin toxicosis.



[Click to download full resolution via product page](#)

Caption: Diagnostic workflow for bromethalin toxicosis.

In conclusion, the available evidence strongly supports the use of MRI as a reliable, non-invasive method for diagnosing bromethalin-induced neurotoxicity, with findings that are consistently validated by histopathology. While the current literature is limited in its quantitative correlation, the qualitative agreement between imaging and microscopic findings is robust. Further research involving larger cohorts and quantitative analysis of MRI data (e.g., ADC values, fractional anisotropy from diffusion tensor imaging) correlated with quantitative histopathology (e.g., g-ratio, myelin sheath thickness) would be beneficial for a more in-depth understanding and potentially for monitoring therapeutic efficacy.

Need Custom Synthesis?

BenchChem offers custom synthesis for rare earth carbides and specific isotopic labeling.

Email: info@benchchem.com or [Request Quote Online](#).

References

- 1. Correlation of MRI with the Neuropathologic Changes in Two Cats with Bromethalin Intoxication - PubMed [pubmed.ncbi.nlm.nih.gov]
- 2. Bromethalin Exposure in Dogs and Cats: A 14-Year Retrospective Study (2010–2023) From the California Animal Health and Food Safety Laboratory System - PMC [pmc.ncbi.nlm.nih.gov]
- 3. researchgate.net [researchgate.net]
- 4. Case Report: MRI, Clinical, and Pathological Correlates of Bromethalin Toxicosis in Three Dogs - PMC [pmc.ncbi.nlm.nih.gov]
- 5. Case Report: MRI, Clinical, and Pathological Correlates of Bromethalin Toxicosis in Three Dogs - PubMed [pubmed.ncbi.nlm.nih.gov]
- 6. dvm360.com [dvm360.com]
- To cite this document: BenchChem. [Validating MRI Findings with Histopathology in Bromethalin Toxicosis: A Comparative Guide]. BenchChem, [2025]. [Online PDF]. Available at: [https://www.benchchem.com/product/b042284#validating-mri-findings-with-histopathology-in-bromethalin-cases]

Disclaimer & Data Validity:

The information provided in this document is for Research Use Only (RUO) and is strictly not intended for diagnostic or therapeutic procedures. While BenchChem strives to provide accurate protocols, we make no warranties, express or implied, regarding the fitness of this product for every specific experimental setup.

Technical Support: The protocols provided are for reference purposes. Unsure if this reagent suits your experiment? [[Contact our Ph.D. Support Team for a compatibility check](#)]

Need Industrial/Bulk Grade? [Request Custom Synthesis Quote](#)

BenchChem

Our mission is to be the trusted global source of essential and advanced chemicals, empowering scientists and researchers to drive progress in science and industry.

Contact

Address: 3281 E Guasti Rd
Ontario, CA 91761, United States
Phone: (601) 213-4426
Email: info@benchchem.com