

Technical Support Center: Standardizing Histopathological Assessment of DMH-Induced Lesions

Author: BenchChem Technical Support Team. **Date:** December 2025

Compound of Interest

Compound Name: 1,2-Dimethylhydrazine

Cat. No.: B038074

[Get Quote](#)

Welcome to the technical support center for the histopathological assessment of **1,2-dimethylhydrazine** (DMH)-induced lesions. This resource is designed for researchers, scientists, and drug development professionals to provide standardized protocols, troubleshooting guidance, and answers to frequently asked questions encountered during animal model experiments of colorectal cancer.

Frequently Asked Questions (FAQs)

Q1: What is the recommended dosage and administration route for DMH to induce colon tumors in rodents?

A1: The dosage and administration of DMH can vary depending on the rodent species and the desired timeline for tumor development. Generally, doses ranging from 15 mg/kg to 40 mg/kg body weight are used.^{[1][2]} The most common route of administration is subcutaneous (s.c.) injection, which has been shown to cause 100% epithelial dysplasia and precancerous lesions in a 12-week study.^{[3][4]} Intraperitoneal (i.p.) injections are also effective in inducing colon tumors.^[3] Weekly injections for a period of 15 to 20 weeks are a common regimen.^{[3][5]}

Q2: What is the typical timeline for the development of histopathological lesions after DMH administration?

A2: The development of lesions follows a progressive sequence. Aberrant crypt foci (ACF), the earliest preneoplastic lesions, can be observed as early as a few weeks after the initial DMH injections.[6] Over time, these can progress to low-grade and high-grade dysplasia, followed by the development of adenomas and adenocarcinomas.[6][7] The appearance of adenomas and adenocarcinomas often requires a longer latency period, potentially 20-40 weeks from the start of DMH treatment.[4]

Q3: What are Aberrant Crypt Foci (ACF) and how are they identified?

A3: Aberrant Crypt Foci (ACF) are considered the earliest identifiable preneoplastic lesions in the colon of rodents treated with carcinogens like DMH.[6] They are characterized by crypts that are larger than normal, have a thicker epithelial lining, and an increased pericryptal zone. ACF can be visualized ex vivo on the mucosal surface of the colon after staining with a solution like 0.2% methylene blue. Under a stereomicroscope, they appear as clusters of darker-staining, elongated, or slit-like crypt openings.

Q4: What are the key histopathological features to look for when grading dysplasia in DMH-induced lesions?

A4: Dysplasia is characterized by cytological and architectural changes in the colonic epithelium. Key features for grading include:

- Low-grade dysplasia: Characterized by nuclear stratification, hyperchromasia, mild loss of polarity, and minimal architectural distortion. Glandular structures are generally maintained. [6][7]
- High-grade dysplasia: Shows more severe cytological atypia, including significant nuclear pleomorphism, loss of polarity, increased and atypical mitotic figures, and complex glandular architecture such as cribriform patterns or back-to-back glands.[6][7]

Q5: Which signaling pathways are commonly activated in DMH-induced colorectal carcinogenesis?

A5: The Wnt/ β -catenin signaling pathway is a central mechanism in DMH-induced colorectal carcinogenesis.[8][9][10] Mutations, often in β -catenin itself in rodent models, lead to its accumulation in the nucleus, where it activates target genes that promote cell proliferation and tumor progression.[8][11] Additionally, inflammation-related pathways, such as the NF- κ B

signaling pathway, play a role in promoting carcinogenesis, often interacting with the Wnt pathway.[\[12\]](#)

Troubleshooting Guides

This section addresses common issues encountered during the histopathological preparation and analysis of DMH-induced lesions.

Problem	Potential Cause(s)	Recommended Solution(s)
Poor Tissue Fixation (e.g., autolysis, blurry nuclear detail)	1. Delayed fixation after tissue collection. 2. Insufficient fixative volume (less than 10:1 fixative to tissue ratio). 3. Fixative is old or of incorrect concentration.	1. Immediately place tissue in fixative upon collection. [13] 2. Ensure a fixative to tissue volume ratio of at least 10:1, preferably 20:1. [13] 3. Use fresh, properly prepared 10% neutral buffered formalin. [14]
Tissue Folds and Wrinkles in Sections	1. Incomplete stretching of the paraffin ribbon on the water bath. 2. Water bath temperature is too low. 3. Dull microtome blade.	1. Gently tease the floating section with forceps to remove folds before mounting on the slide. [15] 2. Maintain water bath temperature at 5-10°C below the melting point of the paraffin wax. [5] 3. Use a new, sharp microtome blade. [5]
Chatter or Micro-vibrations in Sections	1. Loose blade or tissue block in the microtome. 2. Cutting too quickly. 3. Tissue is too hard (over-dehydration or over-fixation).	1. Ensure the blade and cassette are securely clamped. [13] 2. Cut sections with a slow, steady motion. [13] 3. Reduce dehydration times if necessary. If tissue is already processed, soaking the block face with a softening solution may help.
Uneven or Inconsistent Staining	1. Inconsistent timing in staining solutions. 2. Depletion or contamination of staining reagents. 3. Residual paraffin on the slide (incomplete deparaffinization).	1. Use a timer for each step of the staining protocol to ensure consistency. [16] 2. Regularly filter hematoxylin and replace all staining solutions on a defined schedule. [16] 3. Ensure complete deparaffinization with fresh xylene or a xylene substitute. [16] [17]
Air Bubbles Under Coverslip	1. Incorrect coverslipping technique. 2. Mounting medium	1. Place the coverslip at an angle to the slide and lower it

is too viscous or applied in insufficient quantity.

slowly to allow air to escape. [16]2. Use an adequate amount of fresh mounting medium. If bubbles persist, gently press the coverslip with forceps to move them to the edge.

Data Presentation

Table 1: Standardized Histopathological Scoring for Dysplasia in DMH-Models

This table provides a simplified, standardized scoring system for dysplasia, adapted from various histopathological assessment guidelines.

Grade	Score	Architectural Changes	Cytological Features
Normal	0	Normal crypt architecture, straight and parallel glands.	Basally located, small, uniform nuclei. Abundant mucin.
Low-Grade Dysplasia	1	Mild glandular crowding, some branching. Crypt architecture is mostly preserved.	Elongated, hyperchromatic nuclei stratified in the basal half of the cell. Mild decrease in mucin.[6]
High-Grade Dysplasia	2	Marked glandular complexity (cribriform, back-to-back glands). Severe architectural distortion. Loss of crypt structure.	Nuclei are pleomorphic, vesicular, and lose polarity (extend to the apical surface). Increased and atypical mitoses. Significant mucin depletion.[6][7]
Carcinoma in situ / Intramucosal Carcinoma	3	Same as high-grade dysplasia, but with clear evidence of malignant cells confined to the mucosa.	Same as high-grade dysplasia.
Invasive Adenocarcinoma	4	Invasion of malignant glands through the muscularis mucosae into the submucosa or beyond.	Malignant cytological features as described above.

Table 2: Common Immunohistochemical (IHC) Markers for Lesion Characterization

Marker	Cellular Function	Typical Expression in DMH-induced Lesions
Ki-67	Proliferation marker	Expression increases with the grade of dysplasia. In normal crypts, it's confined to the base. In dysplasia and carcinoma, staining extends towards the luminal surface. [18] [19] [20]
β -catenin	Component of Wnt signaling pathway and cell adhesion	In normal tissue, expression is membranous. In dysplastic and neoplastic lesions, strong nuclear and/or cytoplasmic accumulation is observed due to pathway activation. [8] [11] [18] [21]
COX-2 (Cyclooxygenase-2)	Inflammatory enzyme	Upregulated in dysplastic and neoplastic tissues, indicating a role for inflammation in carcinogenesis. Expression intensity often correlates with the severity of dysplasia. [4] [18] [19] [21]

Experimental Protocols

Protocol 1: Hematoxylin and Eosin (H&E) Staining for Rodent Colon Sections

This protocol is for formalin-fixed, paraffin-embedded (FFPE) tissue sections.

Reagents:

- Xylene or xylene substitute

- Ethanol (100%, 95%, 70%)
- Distilled water
- Harris Hematoxylin solution
- Acid-alcohol (e.g., 1% HCl in 70% ethanol)
- Bluing reagent (e.g., Scott's Tap Water Substitute or 0.2% ammonia water)
- Eosin Y solution (0.5% - 1.0% in 95% ethanol)
- Permanent mounting medium

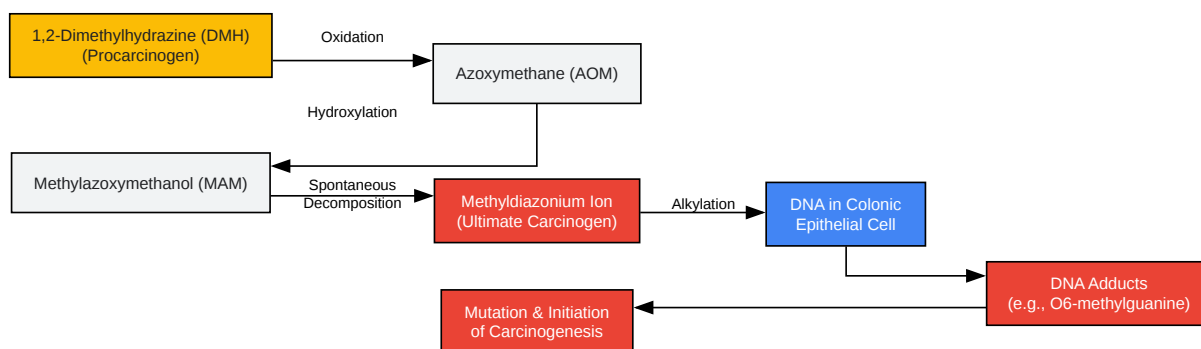
Procedure:

- Deparaffinization and Rehydration:
 - Xylene: 2 changes, 5-10 minutes each.[\[16\]](#)
 - 100% Ethanol: 2 changes, 3-5 minutes each.[\[16\]](#)
 - 95% Ethanol: 1 change, 3 minutes.[\[16\]](#)
 - 70% Ethanol: 1 change, 3 minutes.[\[16\]](#)
 - Rinse gently in running tap water for 5 minutes.[\[16\]](#)
- Hematoxylin Staining (Nuclei):
 - Immerse in filtered Harris Hematoxylin for 3-5 minutes.[\[16\]](#)
 - Rinse in running tap water until water runs clear.
 - Differentiation: Quickly dip slides in acid-alcohol for 1-5 seconds to remove background staining.[\[17\]](#)
 - Rinse immediately in tap water.

- Bluing: Immerse in a bluing agent for 30-60 seconds until nuclei turn a crisp blue.[16]
- Rinse thoroughly in tap water for 1-5 minutes.
- Eosin Staining (Cytoplasm & ECM):
 - Immerse slides in Eosin Y solution for 30 seconds to 2 minutes, depending on desired intensity.[16]
 - Rinse briefly in tap water.
- Dehydration, Clearing, and Mounting:
 - 95% Ethanol: 2 changes, 2-3 minutes each.[16]
 - 100% Ethanol: 2 changes, 2-3 minutes each.[16]
 - Xylene: 2 changes, 5 minutes each.[16]
 - Apply a drop of mounting medium to the section and coverslip, avoiding air bubbles.[14]
 - Allow slides to dry in a horizontal position.

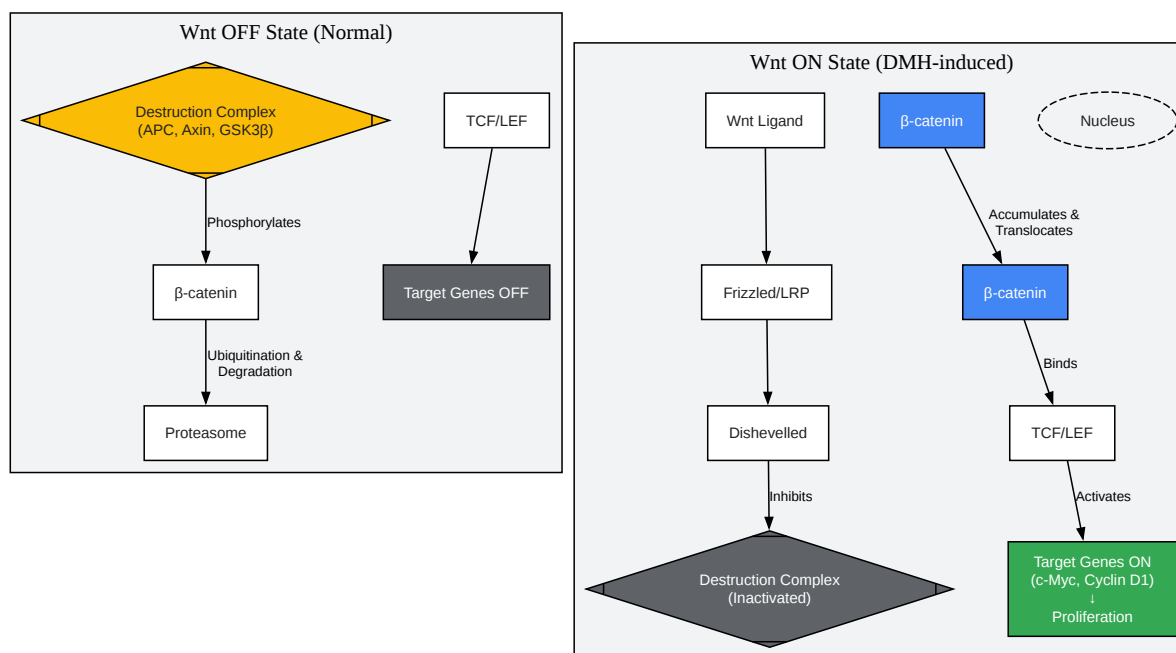
Mandatory Visualization

Signaling Pathways and Experimental Workflows

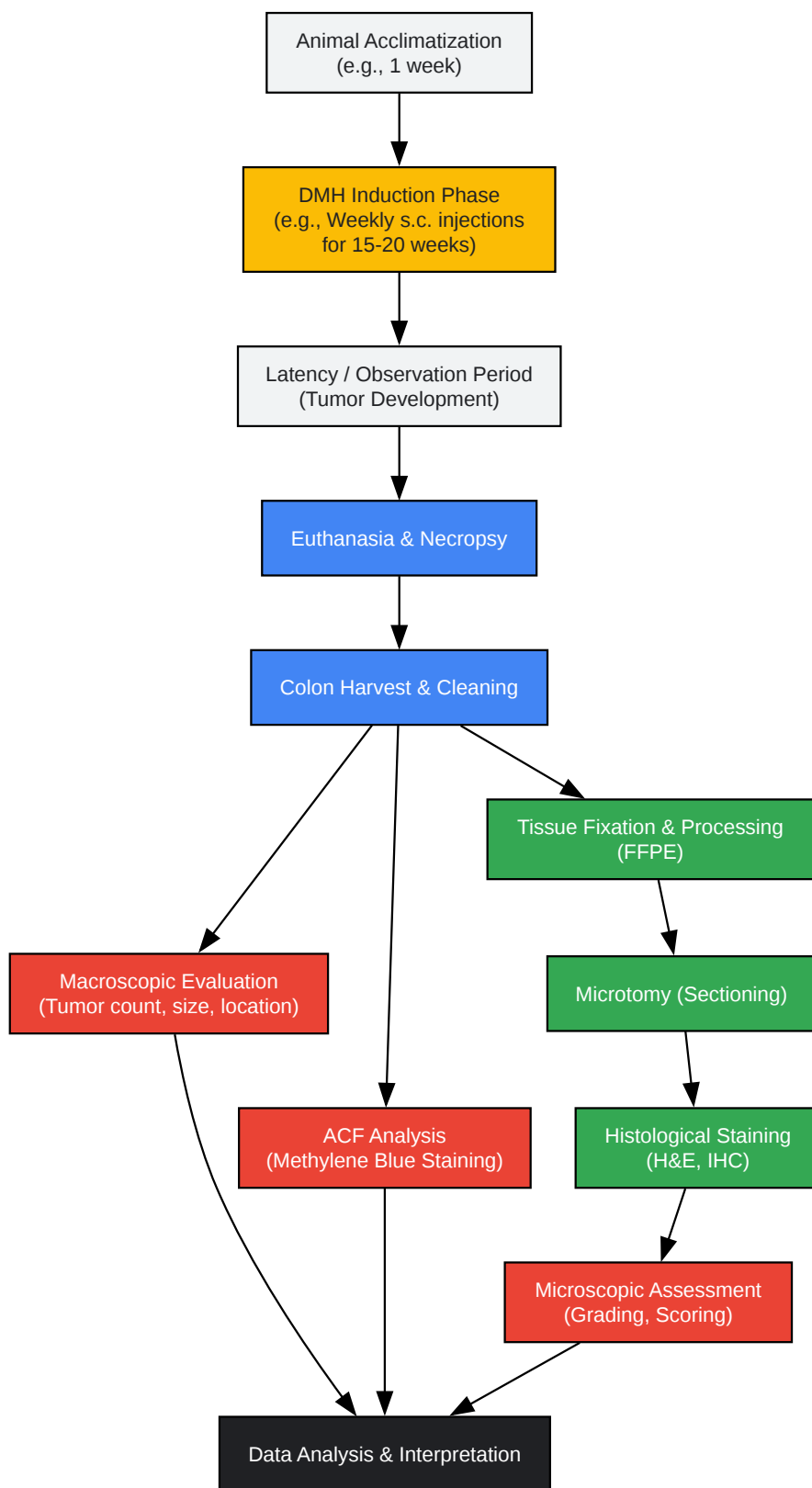


[Click to download full resolution via product page](#)

Caption: Metabolic activation pathway of **1,2-dimethylhydrazine (DMH)**.^{[1][3][22]}

[Click to download full resolution via product page](#)

Caption: Aberrant Wnt/ β -catenin signaling in DMH-induced carcinogenesis.^{[9][10][12]}



[Click to download full resolution via product page](#)

Need Custom Synthesis?

BenchChem offers custom synthesis for rare earth carbides and specific isotopic labeling.

Email: info@benchchem.com or [Request Quote Online](#).

References

- 1. journal.waocp.org [journal.waocp.org]
- 2. researchgate.net [researchgate.net]
- 3. Biochemical and molecular aspects of 1,2-dimethylhydrazine (DMH)-induced colon carcinogenesis: a review - PMC [pmc.ncbi.nlm.nih.gov]
- 4. Morphological Changes and Inflammation Preceded the Pathogenesis of 1,2-Dimethylhydrazine-Induced Colorectal Cancer - PMC [pmc.ncbi.nlm.nih.gov]
- 5. scispace.com [scispace.com]
- 6. researchgate.net [researchgate.net]
- 7. Pathology of Rodent Models of Intestinal Cancer: Progress Report and Recommendations - PMC [pmc.ncbi.nlm.nih.gov]
- 8. Alterations in lipid mediated signaling and Wnt/ β -catenin signaling in DMH induced colon cancer on supplementation of fish oil - PubMed [pubmed.ncbi.nlm.nih.gov]
- 9. Angiogenesis-Related Functions of Wnt Signaling in Colorectal Carcinogenesis [mdpi.com]
- 10. Wnt/ β -catenin signaling in colorectal cancer: Is therapeutic targeting even possible? - PubMed [pubmed.ncbi.nlm.nih.gov]
- 11. β -Catenin mutations in a mouse model of inflammation-related colon carcinogenesis induced by 1,2-dimethylhydrazine and dextran sodium sulfate - PMC [pmc.ncbi.nlm.nih.gov]
- 12. Wnt signaling in cancer stem cells and colon cancer metastasis - PMC [pmc.ncbi.nlm.nih.gov]
- 13. researchgate.net [researchgate.net]
- 14. Haematoxylin Eosin (H&E) staining [protocols.io]
- 15. A review of artifacts in histopathology - PMC [pmc.ncbi.nlm.nih.gov]
- 16. clyte.tech [clyte.tech]
- 17. labmethods.org [labmethods.org]

- 18. Immunohistochemical expressions of Ki-67, cyclin D1, beta-catenin, cyclooxygenase-2, and epidermal growth factor receptor in human colorectal adenoma: a validation study of tissue microarrays - PubMed [pubmed.ncbi.nlm.nih.gov]
- 19. COX-2 and Ki-67 immunohistochemical markers in the assessment of long-standing ulcerative colitis associated dysplasia - PubMed [pubmed.ncbi.nlm.nih.gov]
- 20. biotechlink.org [biotechlink.org]
- 21. researchgate.net [researchgate.net]
- 22. Biochemical and molecular aspects of 1,2-dimethylhydrazine (DMH)-induced colon carcinogenesis: a review - PubMed [pubmed.ncbi.nlm.nih.gov]
- To cite this document: BenchChem. [Technical Support Center: Standardizing Histopathological Assessment of DMH-Induced Lesions]. BenchChem, [2025]. [Online PDF]. Available at: [https://www.benchchem.com/product/b038074#standardizing-histopathological-assessment-of-dmh-induced-lesions]

Disclaimer & Data Validity:

The information provided in this document is for Research Use Only (RUO) and is strictly not intended for diagnostic or therapeutic procedures. While BenchChem strives to provide accurate protocols, we make no warranties, express or implied, regarding the fitness of this product for every specific experimental setup.

Technical Support: The protocols provided are for reference purposes. Unsure if this reagent suits your experiment? [[Contact our Ph.D. Support Team for a compatibility check](#)]

Need Industrial/Bulk Grade? [Request Custom Synthesis Quote](#)

BenchChem

Our mission is to be the trusted global source of essential and advanced chemicals, empowering scientists and researchers to drive progress in science and industry.

Contact

Address: 3281 E Guasti Rd

Ontario, CA 91761, United States

Phone: (601) 213-4426

Email: info@benchchem.com