

# Technical Support Center: Troubleshooting FAPI-2 Image Artifacts

**Author:** BenchChem Technical Support Team. **Date:** December 2025

## Compound of Interest

Compound Name: FAPI-2

Cat. No.: B3349772

[Get Quote](#)

Welcome to the technical support center for **FAPI-2** PET/CT imaging. This resource is designed for researchers, scientists, and drug development professionals to address specific issues that may arise during experiments, ensuring the acquisition of high-quality, reliable data.

## Frequently Asked Questions (FAQs) & Troubleshooting Guides

This section is divided into two parts:

- **Physiological & Benign Uptake (Pitfalls):** Addressing common findings where FAPI tracer uptake is not related to malignancy.
- **Technical Image Artifacts:** Focusing on artifacts arising from patient motion, metallic implants, and other technical factors.

### Part 1: Physiological & Benign Uptake (Pitfalls)

**Question:** Why am I observing high FAPI tracer uptake in joints and vertebral bodies that are not suspected of malignancy?

**Answer:** This is one of the most common findings in FAPI PET/CT imaging. The uptake is typically due to degenerative processes such as osteoarthritis, exostosis, and enthesopathy.[1][2][3] Fibroblast activation is a key component of tissue remodeling, inflammation, and fibrosis,

which are all present in degenerative joint and bone diseases.[2] On CT images, these areas of uptake often correspond to visible degenerative changes like facet joint arthritis.[2]

Question: What causes the significant FAPI uptake often seen in the uterus?

Answer: Variable physiological uterine tracer uptake is frequently reported, particularly in premenopausal women. This is due to fibroblast activation during normal physiological processes like angiogenesis and tissue remodeling in the endometrium. The intensity of this uptake has been observed to correlate negatively with age. This can sometimes complicate the interpretation of images for gynecological malignancies.

Question: I've noticed FAPI uptake in recent surgical sites and scars. Is this an indication of recurrence?

Answer: Not necessarily. FAP is significantly overexpressed by myofibroblasts during tissue remodeling and wound healing. Therefore, FAPI tracer accumulation is expected in areas of recent surgery, scarring, or trauma. It is crucial to correlate these findings with the patient's clinical history to avoid misinterpretation as malignant tissue.

Question: Can inflammatory lesions show FAPI uptake?

Answer: Yes, various inflammatory processes can lead to increased FAPI uptake. Fibroblast activation is a hallmark of inflammation. Conditions like inflammatory atheromata, pancreatitis, and even inflammatory responses to infections can show significant tracer accumulation. Distinguishing between malignant and inflammatory lesions can sometimes be challenging based on uptake values alone, although delayed imaging may help in some cases.

## Part 2: Technical Image Artifacts

Question: The PET images of the thoracic and abdominal regions appear blurry. What could be the cause and how can it be fixed?

Answer: Blurring in these regions is most often caused by respiratory motion. The movement of the diaphragm and lungs during the relatively long PET acquisition causes a mismatch between the PET and CT data. This misalignment can lead to inaccurate attenuation correction and smearing of the radioactive signal.

- **Solution:** Employing respiratory gating is the most effective solution. This technique monitors the patient's breathing cycle and acquires PET data only during specific phases, typically at end-expiration when motion is minimal. This ensures that the PET and CT data are better aligned, reducing motion artifacts and improving image sharpness.

**Question:** There are areas of unusually high and low uptake around a patient's metallic implant (e.g., dental filling, hip prosthesis). How should I interpret this?

**Answer:** These are characteristic metal artifacts. High-density materials like metal cause severe streaking and photon starvation on the CT scan. When this erroneous CT data is used for PET attenuation correction, it leads to a significant overestimation (hot spots) or underestimation (cold spots) of tracer activity in the surrounding tissues.

- **Solution:**
  - **Review Non-Attenuation-Corrected (NAC) Images:** Always review the NAC PET images. These images are not affected by CT-based artifacts and can help determine if an area of high uptake is a true biological finding or an artifact. If the "hot spot" disappears on the NAC images, it is an artifact.
  - **Use Metal Artifact Reduction (MAR) Algorithms:** If your scanner software is equipped with MAR, reprocess the CT data using this algorithm before it is used for attenuation correction. This can significantly reduce the impact of the metal artifact on the final PET image.

**Question:** Why is there a curvilinear "cold" artifact at the dome of the liver or base of the lungs?

**Answer:** This is a classic respiratory motion artifact resulting from a mismatch between the diaphragm's position during the CT scan (often acquired during a breath-hold) and its average position during the longer, free-breathing PET scan. This misalignment leads to an incorrect attenuation map and a subsequent underestimation of tracer uptake in that region.

- **Solution:** Similar to motion-induced blurring, respiratory gating is the primary method to correct this. Acquiring both PET and CT data at the same phase of respiration ensures proper alignment and accurate attenuation correction.

## Quantitative Data Summary

While there is an overlap in FAPI uptake between benign and malignant lesions, quantitative analysis can aid in differentiation. The following table summarizes typical Standardized Uptake Value (SUVmax) measurements for various findings.

Finding Category	Specific Lesion Type	Mean SUVmax (Range)	Reference
Malignant Lesions	Primary Tumors (various)	10.6 (0.97 - 25.71)	
Benign Lesions (Overall)	Various	4.2 (1.39 - 21.8)	
Degenerative Lesions		7.7 ( $\pm$ 2.9)	
Inflammatory Processes		3.64 (Median)	
Uterine Uptake (Physiological)		12.2 ( $\pm$ 7.3)	
Hemorrhoids		3.64 (Median)	
Fractures		3.64 (Median)	

Note: A study suggested an SUVmax cutoff value of 5.5 to differentiate between benign and malignant lesions, with a sensitivity of 78.8% and specificity of 85.1%. However, these values should be used as a guide and always interpreted in the context of clinical information and CT findings.

## Experimental Protocols

### Protocol 1: Standard FAPI PET/CT Patient Preparation and Image Acquisition

- Patient Preparation:
  - No specific patient preparation such as fasting is required.

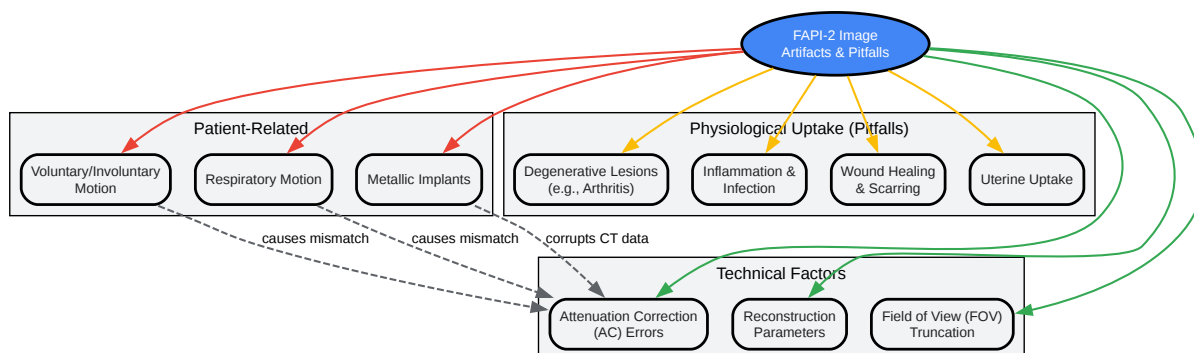
- Ensure the patient is well-hydrated.
- Instruct the patient to void immediately before the scan to minimize artifacts from bladder activity.
- Tracer Administration:
  - Administer the FAPI tracer intravenously.
  - Recommended administered activity for Gallium-68 ( $^{68}\text{Ga}$ ) based FAPI tracers is 100-200 MBq (or  $\sim 2$  MBq/kg).
  - Recommended administered activity for Fluorine-18 ( $^{18}\text{F}$ ) based FAPI tracers is 175-275 MBq (or 3-4 MBq/kg).
- Uptake Time:
  - For  $^{68}\text{Ga}$ -FAPI compounds, the recommended uptake time is between 20 and 60 minutes post-injection. An uptake time of 30-40 minutes is often a good compromise.
  - For  $^{18}\text{F}$ -FAPI compounds, the recommended uptake time is between 30 and 90 minutes post-injection.
- Image Acquisition:
  - CT Scan: Perform a low-dose CT scan for attenuation correction and anatomical localization. A diagnostic quality contrast-enhanced CT can be performed if clinically indicated.
  - PET Scan:
    - The scan range should typically be from the skull base to the mid-thigh. A vertex-to-toes scan may be considered depending on the clinical question.
    - Scanning from the thighs to the head is recommended to reduce artifacts from the bladder filling during the scan.

- Acquisition parameters (e.g., time per bed position) will be scanner-dependent but should be optimized for adequate counting statistics.

## Protocol 2: Troubleshooting Motion Artifacts with Respiratory Gating

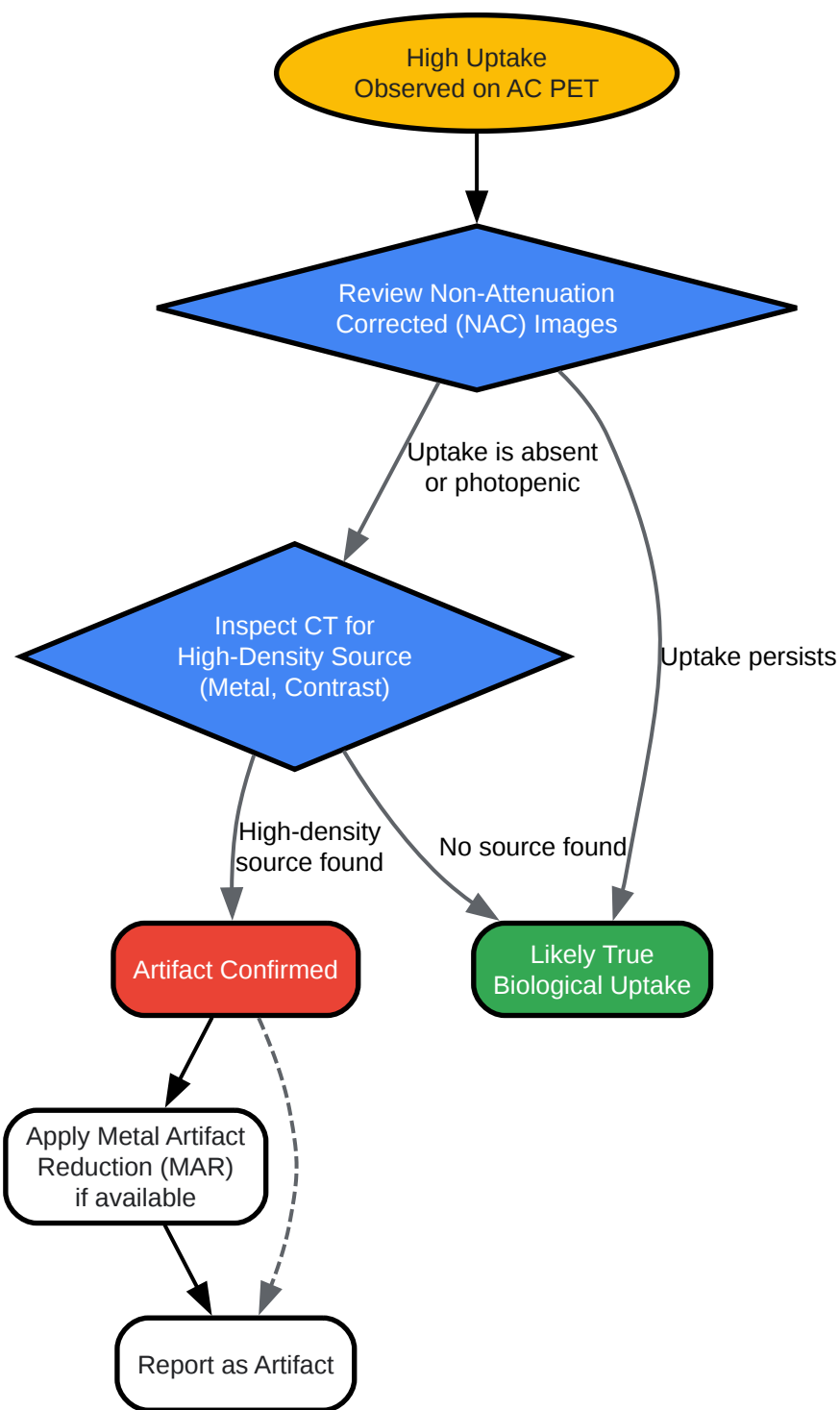
- Patient Setup:
  - Position the patient on the scanner bed.
  - Place the respiratory tracking system (e.g., a pressure-sensitive belt or an infrared camera with a marker block) on the patient's abdomen to monitor the respiratory cycle.
- Gated CT Acquisition:
  - Acquire a 4D-CT scan, which captures images at different phases of the breathing cycle. From this, a specific phase (typically end-expiration) can be selected to create the CT attenuation map.
- Gated PET Acquisition:
  - Acquire the PET data in "list mode" while concurrently recording the respiratory signal.
  - The PET data is then sorted into different temporal "bins" that correspond to different phases of the respiratory cycle.
- Image Reconstruction:
  - Reconstruct the PET image using only the data from the selected respiratory phase (e.g., end-expiration bin) and the corresponding CT attenuation map from the same phase.
  - This ensures that the PET and CT data are spatially and temporally aligned, minimizing motion-related artifacts.

## Mandatory Visualizations



[Click to download full resolution via product page](#)

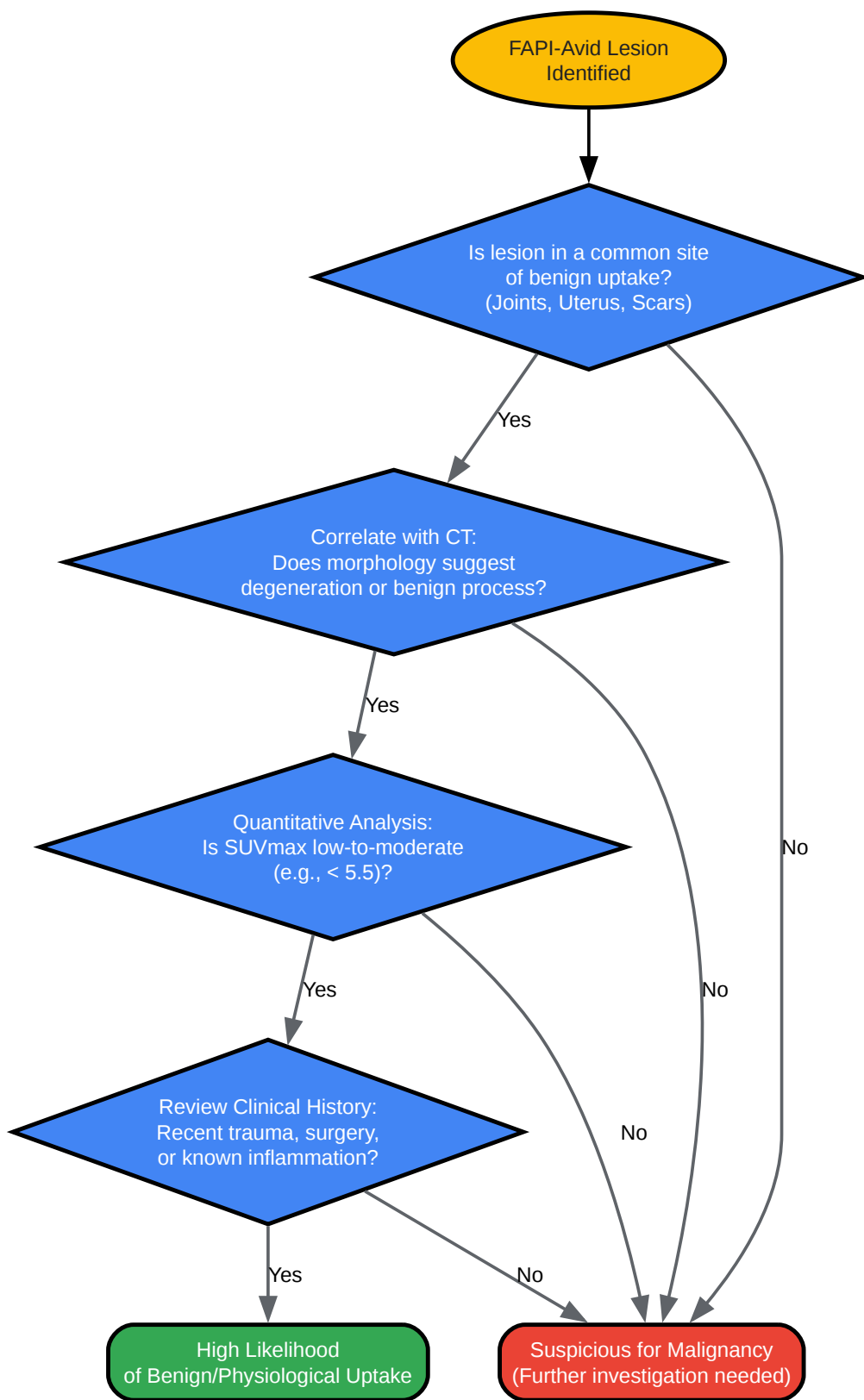
Caption: Overview of potential sources for **FAPI-2** PET/CT image artifacts and pitfalls.



[Click to download full resolution via product page](#)

Caption: Troubleshooting workflow for suspected attenuation correction (AC) artifacts.





[Click to download full resolution via product page](#)

Caption: Decision workflow for differentiating physiological from malignant FAPI uptake.

**Need Custom Synthesis?**

BenchChem offers custom synthesis for rare earth carbides and specific isotopic labeling.

Email: [info@benchchem.com](mailto:info@benchchem.com) or [Request Quote Online](#).

## References

- 1. SNMMI Procedure Standard/EANM Practice Guideline for Fibroblast Activation Protein (FAP) PET - PMC [[pmc.ncbi.nlm.nih.gov](https://pubmed.ncbi.nlm.nih.gov/)]
- 2. Pitfalls and Common Findings in 68Ga-FAPI PET: A Pictorial Analysis - PMC [[pmc.ncbi.nlm.nih.gov](https://pubmed.ncbi.nlm.nih.gov/)]
- 3. [jnm.snmjournals.org](https://jnm.snmjournals.org/) [[jnm.snmjournals.org](https://jnm.snmjournals.org/)]
- To cite this document: BenchChem. [Technical Support Center: Troubleshooting FAPI-2 Image Artifacts]. BenchChem, [2025]. [Online PDF]. Available at: [<https://www.benchchem.com/product/b3349772#troubleshooting-fapi-2-image-artifacts>]

---

**Disclaimer & Data Validity:**

The information provided in this document is for Research Use Only (RUO) and is strictly not intended for diagnostic or therapeutic procedures. While BenchChem strives to provide accurate protocols, we make no warranties, express or implied, regarding the fitness of this product for every specific experimental setup.

**Technical Support:** The protocols provided are for reference purposes. Unsure if this reagent suits your experiment? [[Contact our Ph.D. Support Team for a compatibility check](#)]

**Need Industrial/Bulk Grade?** [Request Custom Synthesis Quote](#)

# BenchChem

Our mission is to be the trusted global source of essential and advanced chemicals, empowering scientists and researchers to drive progress in science and industry.

## Contact

Address: 3281 E Guasti Rd

Ontario, CA 91761, United States

Phone: (601) 213-4426

Email: [info@benchchem.com](mailto:info@benchchem.com)