

# Validating the use of CardioPET in specific disease models (e.g., diabetes)

**Author:** BenchChem Technical Support Team. **Date:** December 2025

## Compound of Interest

Compound Name: *Cardiopet*

Cat. No.: *B3064052*

[Get Quote](#)

## Validating CardioPET in Diabetic Cardiomyopathy: A Comparative Guide

For Researchers, Scientists, and Drug Development Professionals

This guide provides an objective comparison of cardiac positron emission tomography (**CardioPET**) with established imaging modalities—cardiac magnetic resonance imaging (CMR) and echocardiography—for the assessment of diabetic cardiomyopathy (DCM) in preclinical disease models. The information presented is supported by experimental data from peer-reviewed studies, with detailed methodologies provided for key experiments.

## Comparative Analysis of Imaging Modalities

**CardioPET**, particularly with the tracer  $^{18}\text{F}$ -Fluorodeoxyglucose ( $^{18}\text{F}$ -FDG), offers a unique advantage in quantifying myocardial glucose metabolism, a key pathway altered in diabetes.[1][2] In contrast, CMR is the gold standard for assessing cardiac structure and function, while echocardiography is a widely accessible, non-invasive tool for functional assessment.[3][4] Recent studies suggest that specialized PET tracers may detect early pathological changes, such as fibrosis, even before functional abnormalities are apparent with conventional methods like echocardiography.[5][6]

A study directly comparing a PET tracer for fibroblast activation ( $[^{68}\text{Ga}]\text{Ga}$ -DOTA-FAPI-04) with echocardiography in db/db mice found that PET could identify cardiac fibrosis at an early stage,

whereas echocardiography and serum biomarkers failed to detect these subtle, early changes. [5][6] This highlights the potential of molecular imaging with PET to provide earlier insights into the disease process. While head-to-head comparisons of metabolic **CardioPET** ( $^{18}\text{F}$ -FDG) with both CMR and echocardiography in the same diabetic animal cohort are limited, the existing data allows for a comprehensive evaluation of their respective strengths and weaknesses.

## Data Presentation

The following tables summarize quantitative data from studies utilizing **CardioPET**, CMR, and echocardiography in common rodent models of diabetes.

Table 1: Performance of **CardioPET** ( $^{18}\text{F}$ -FDG) in Diabetic Mouse Models

Parameter	Diabetic Model	Age (weeks)	Control Value (mean $\pm$ SD)	Diabetic Value (mean $\pm$ SD)	Key Finding
Myocardial Glucose Uptake (MRGlu)	db/db mice	16	15.8 $\pm$ 3.5 nmol/g/min	45.2 $\pm$ 12.1 nmol/g/min	Significantly increased glucose uptake in diabetic mice. [7]
Glucose Uptake Rate Constant (Ki)	db/db mice	16	4.2 $\pm$ 0.9 $\mu\text{L/g/min}$	8.1 $\pm$ 1.8 $\mu\text{L/g/min}$	Elevated rate constant indicates altered glucose metabolism. [7]
$^{18}\text{F}$ -FDG Uptake	STZ-induced rats	-	-	Significantly Decreased	Reduced glucose uptake in a model of Type 1 diabetes.[8]

Table 2: Performance of Cardiac MRI in Diabetic Rodent Models

Parameter	Diabetic Model	Disease Duration	Control Value (mean ± SD)	Diabetic Value (mean ± SD)	Key Finding
End-Diastolic Volume (EDV)	STZ-induced rats	8 weeks	0.78 ± 0.07 mL	0.56 ± 0.05 mL	28% decrease in EDV in diabetic hearts.
End-Systolic Volume (ESV)	STZ-induced rats	8 weeks	0.29 ± 0.04 mL	0.32 ± 0.03 mL	10% increase in ESV, suggesting systolic impairment.
Stroke Volume (SV)	STZ-induced rats	8 weeks	0.49 ± 0.05 mL	0.25 ± 0.04 mL	48% reduction in stroke volume.
Ejection Fraction (EF)	STZ-induced rats	8 weeks	62.1 ± 4.5 %	44.8 ± 3.9 %	Significant reduction in ejection fraction.

Table 3: Performance of Echocardiography in Diabetic Mouse Models

Parameter	Diabetic Model	Age (weeks)	Control Value (mean $\pm$ SD)	Diabetic Value (mean $\pm$ SD)	Key Finding
Left Ventricular Ejection Fraction (LVEF)	db/db mice	20	55.2 $\pm$ 3.1 %	42.5 $\pm$ 2.8 %	Significant systolic dysfunction in later-stage diabetes.[9]
E/e' Ratio	db/db mice	20	12.4 $\pm$ 1.5	20.1 $\pm$ 2.3	Elevated E/e' ratio indicates diastolic dysfunction. [9]
Fractional Shortening (FS)	db/db mice	12	59.5 $\pm$ 2.3 %	43.8 $\pm$ 2.1 %	Early signs of systolic dysfunction.

## Experimental Protocols

### <sup>18</sup>F-FDG CardioPET Imaging in a Diabetic Mouse Model

Objective: To quantify myocardial glucose uptake.

Methodology:

- Animal Model: db/db mice (a model of type 2 diabetes) and control db/+ mice.
- Animal Preparation: Mice are fasted for 12-16 hours to reduce physiological myocardial glucose uptake and enhance the signal from pathological processes.
- Anesthesia: Anesthesia is induced and maintained with 1.5-2% isoflurane in oxygen.
- Radiotracer Injection: Approximately 20 MBq of <sup>18</sup>F-FDG is administered via a tail vein catheter.
- Uptake Period: A 60-minute uptake period is allowed for the tracer to distribute.

- **Image Acquisition:** A 15-minute dynamic PET scan is acquired. For cardiac gating, an ECG signal is simultaneously recorded.
- **Image Analysis:** The PET data is reconstructed, and regions of interest (ROIs) are drawn around the left ventricular myocardium. The myocardial metabolic rate of glucose (MRGlu) and the glucose uptake rate constant ( $K_i$ ) are calculated using Patlak graphical analysis.[9]

## Cardiac Magnetic Resonance (CMR) Imaging in a Diabetic Rat Model

**Objective:** To assess cardiac structure and function.

**Methodology:**

- **Animal Model:** Streptozotocin (STZ)-induced diabetic rats (a model of type 1 diabetes) and control rats.
- **Animal Preparation:** No specific dietary restrictions are required for this functional assessment.
- **Anesthesia:** Anesthesia is maintained with 1.5% isoflurane.
- **Physiological Monitoring:** ECG and respiration are monitored throughout the imaging session.
- **Image Acquisition:** Cine MRI images are acquired using a 9.4T scanner. Multiple short-axis slices covering the entire left ventricle are obtained.
- **Image Analysis:** The endocardial and epicardial borders of the left ventricle are manually traced at end-diastole and end-systole. End-diastolic volume (EDV), end-systolic volume (ESV), stroke volume (SV), and ejection fraction (EF) are then calculated.

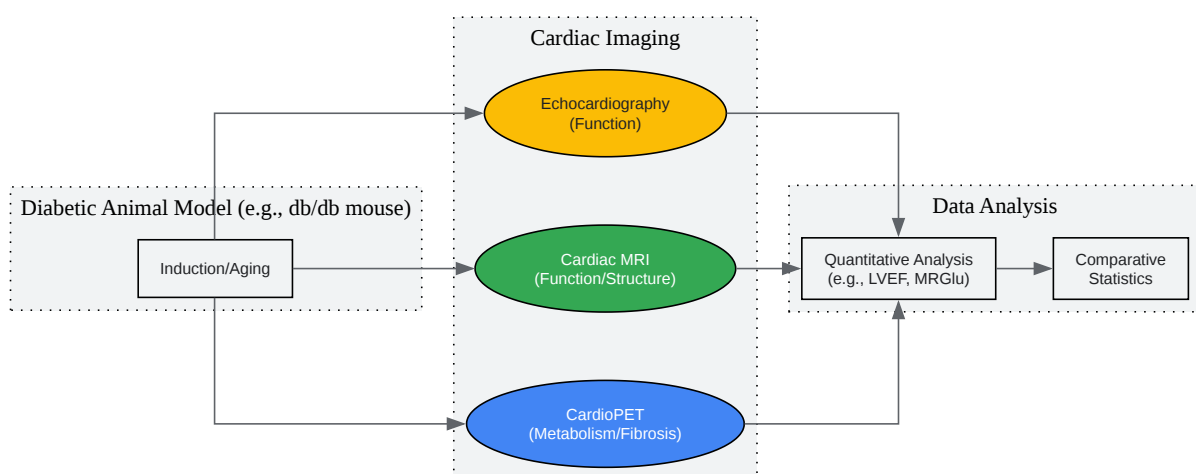
## Transthoracic Echocardiography in a Diabetic Mouse Model

**Objective:** To evaluate systolic and diastolic function.

### Methodology:

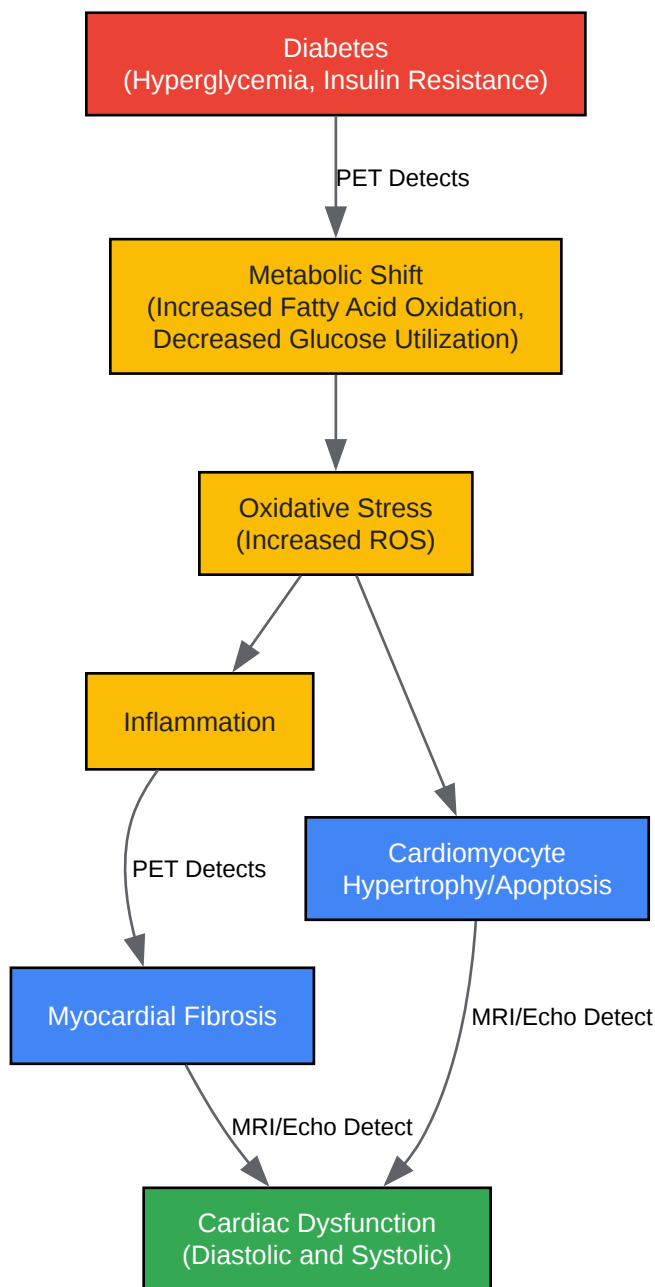
- Animal Model: db/db mice and control mice.
- Animal Preparation: The chest is shaved to ensure a good acoustic window.
- Anesthesia: Light anesthesia is induced with isoflurane.
- Image Acquisition: A high-frequency ultrasound system is used. M-mode images of the left ventricle are acquired from the parasternal short-axis view to measure wall thickness and chamber dimensions. Pulsed-wave Doppler of the mitral inflow and tissue Doppler of the mitral annulus are performed to assess diastolic function.
- Image Analysis: Left ventricular ejection fraction (LVEF) and fractional shortening (FS) are calculated from the M-mode measurements. The ratio of early diastolic mitral inflow velocity (E) to early diastolic mitral annular velocity (e') (E/e' ratio) is calculated to assess left ventricular filling pressures.<sup>[9]</sup>

## Visualizations



[Click to download full resolution via product page](#)

Caption: General experimental workflow for comparative cardiac imaging.

[Click to download full resolution via product page](#)

Caption: Simplified signaling pathway in diabetic cardiomyopathy.

**Need Custom Synthesis?**

BenchChem offers custom synthesis for rare earth carbides and specific isotopic labeling.

Email: [info@benchchem.com](mailto:info@benchchem.com) or [Request Quote Online](#).

## References

- 1. Multi-modality cardiac imaging in the management of diabetic heart disease - PubMed [pubmed.ncbi.nlm.nih.gov]
- 2. Non-invasive cardiac imaging techniques and vascular tools for the assessment of cardiovascular disease in type 2 diabetes mellitus - PMC [pmc.ncbi.nlm.nih.gov]
- 3. Diagnostic approaches for diabetic cardiomyopathy - PMC [pmc.ncbi.nlm.nih.gov]
- 4. Diabetic cardiomyopathy: a comprehensive review of diagnosis, management, and future directions - PMC [pmc.ncbi.nlm.nih.gov]
- 5. pubs.acs.org [pubs.acs.org]
- 6. Noninvasive Monitoring of Early Cardiac Fibrosis in Diabetic Mice by [68Ga]Ga-DOTA-FAPI-04 PET/CT Imaging - PMC [pmc.ncbi.nlm.nih.gov]
- 7. Longitudinal evaluation of myocardial glucose metabolism and contractile function in obese type 2 diabetic db/db mice using small-animal dynamic 18F-FDG PET and echocardiography - PMC [pmc.ncbi.nlm.nih.gov]
- 8. Left Ventricular Diastolic Dysfunction in a Rat Model of Diabetic Cardiomyopathy using ECG-gated 18F-FDG PET - PMC [pmc.ncbi.nlm.nih.gov]
- 9. Dynamic evolution and mechanism of myocardial glucose metabolism in different functional phenotypes of diabetic cardiomyopathy — a study based on 18 F-FDG microPET myocardial metabolic imaging - PMC [pmc.ncbi.nlm.nih.gov]
- To cite this document: BenchChem. [Validating the use of CardioPET in specific disease models (e.g., diabetes)]. BenchChem, [2025]. [Online PDF]. Available at: [https://www.benchchem.com/product/b3064052#validating-the-use-of-cardiopet-in-specific-disease-models-e-g-diabetes]

---

### Disclaimer & Data Validity:

The information provided in this document is for Research Use Only (RUO) and is strictly not intended for diagnostic or therapeutic procedures. While BenchChem strives to provide



accurate protocols, we make no warranties, express or implied, regarding the fitness of this product for every specific experimental setup.

**Technical Support:** The protocols provided are for reference purposes. Unsure if this reagent suits your experiment? [[Contact our Ph.D. Support Team for a compatibility check](#)]

**Need Industrial/Bulk Grade?** [Request Custom Synthesis Quote](#)

## BenchChem

Our mission is to be the trusted global source of essential and advanced chemicals, empowering scientists and researchers to drive progress in science and industry.

### Contact

Address: 3281 E Guasti Rd  
Ontario, CA 91761, United States  
Phone: (601) 213-4426  
Email: [info@benchchem.com](mailto:info@benchchem.com)