

Eob-dtpa MRI artifacts and correction methods

Author: BenchChem Technical Support Team. **Date:** December 2025

Compound of Interest

Compound Name: *Eob-dtpa*

Cat. No.: *B3021170*

[Get Quote](#)

Technical Support Center: Eob-dtpa MRI

This technical support center provides troubleshooting guides and frequently asked questions (FAQs) to assist researchers, scientists, and drug development professionals in addressing artifacts encountered during Gadolinium ethoxybenzyl diethylenetriamine pentaacetic acid (Gd-**EOB-DTPA**) enhanced Magnetic Resonance Imaging (MRI) experiments.

Troubleshooting Guides

This section offers solutions to common problems and artifacts that may arise during **Eob-dtpa** MRI studies.

Issue: Motion Artifacts Degrading Image Quality, Particularly in the Arterial Phase

Symptoms:

- Ghosting or blurring of anatomical structures.
- Indistinct tumor margins.
- Transient severe motion (TSM) artifacts appearing as a brief, severe image degradation.^[1]^[2]

Possible Causes:

- Patient movement, including breathing and cardiac pulsations.^[3]^[4]

- Shorter breath-hold times required during the arterial phase with Gd-**EOB-DTPA** compared to other contrast agents.[1]
- The high T1 relaxivity of Gd-**EOB-DTPA** can accentuate motion effects.[1]

Correction Methods:

- Patient Preparation and Communication:
 - Thoroughly explain the importance of holding still and breath-holding maneuvers to the patient before the scan.
 - Practice breath-holding with the patient to ensure they can comply.
- Acquisition Technique Modification:
 - Respiratory Gating/Triggering: Synchronize data acquisition with the patient's breathing cycle to minimize respiratory motion artifacts.[4]
 - Cardiac Gating: Use electrocardiogram (ECG) gating to reduce artifacts arising from cardiac pulsations, especially for lesions near the heart.[5]
 - Compressed Sensivity Encoding (CS): This advanced imaging technique can reduce pulsation artifacts.[5] A recent study demonstrated that CS-eTHRIVE (enhanced T1 high-resolution isotropic volumetric excitation with CS) significantly reduced pulsation artifacts in Gd-**EOB-DTPA**-enhanced 3D-T1TFE imaging compared to standard S-eTHRIVE.[5]
- Injection Protocol Adjustment:
 - Modifying the injection rate of Gd-**EOB-DTPA** can influence the incidence of arterial phase artifacts.[6] Slower injection rates may help mitigate some motion-related artifacts by broadening the contrast bolus.[2]

Issue: Appearance of Truncation (Gibbs) Artifacts

Symptoms:

- Ringing or line-like patterns near sharp high-contrast boundaries, such as the edge of the liver or major blood vessels.[\[1\]](#)[\[4\]](#)[\[7\]](#)
- These can sometimes be misinterpreted as pathological features.[\[4\]](#)

Possible Causes:

- Under-sampling of k-space, particularly of high-frequency data, which is common in the arterial phase of Gd-**EOB-DTPA** enhanced MRI.[\[1\]](#)[\[7\]](#)
- The rapid signal change during the arterial phase due to the contrast agent influx contributes to this artifact.[\[1\]](#)

Correction Methods:

- Increase Matrix Size: Acquiring data with a larger matrix size can reduce the appearance of truncation artifacts, although this may increase scan time.
- Apply a k-space Filter: Using a filter that smooths the k-space data before Fourier transformation can suppress the ringing artifact.
- Optimize Injection Rate: Studies have investigated the impact of different Gd-**EOB-DTPA** injection flow rates on the Gibbs artifact.[\[7\]](#)[\[8\]](#)[\[9\]](#) Adjusting the flow rate may help to homogenize the k-space sampling during the arterial phase.[\[7\]](#)[\[8\]](#)

Issue: Marginal High Intensity or "Rim" Artifacts

Symptoms:

- A bright band appearing at the margin of the liver, especially during the arterial phase.[\[1\]](#)

Possible Causes:

- This artifact is often observed when k-space data collection is centrally ordered.[\[1\]](#)

Correction Methods:

- **Modify k-space Trajectory:** Altering the order of k-space filling during the acquisition can mitigate this artifact. Consult with your MRI physicist or applications specialist to explore alternative k-space acquisition schemes.

Frequently Asked Questions (FAQs)

Q1: What are the most common types of artifacts in **Eob-dtpa** MRI?

A1: The most frequently encountered artifacts in Gd-**EOB-DTPA** enhanced MRI include:

- **Motion artifacts:** These are often more pronounced in the arterial phase and can manifest as blurring, ghosting, or transient severe motion.[\[1\]](#)[\[2\]](#)
- **Truncation (Gibbs) artifacts:** These appear as ringing or lines near high-contrast interfaces.[\[1\]](#)[\[4\]](#)[\[7\]](#)
- **Marginal high intensity:** This is a bright rim that can be seen at the edge of the liver.[\[1\]](#)
- **Aliasing or Wrap-around artifacts:** This occurs when the field of view is smaller than the object being imaged, causing anatomy outside the field of view to be superimposed on the image.[\[4\]](#)[\[10\]](#)

Q2: Why are artifacts more common in the arterial phase of **Eob-dtpa** MRI?

A2: Several factors contribute to the increased incidence of artifacts in the arterial phase:

- **Rapid Signal Change:** The rapid influx of the high-relaxivity Gd-**EOB-DTPA** contrast agent causes a significant and rapid change in signal intensity, which can lead to artifacts like truncation.[\[1\]](#)
- **Short Acquisition Window:** The arterial phase is brief, requiring rapid imaging, which can make it more susceptible to motion.
- **Patient Physiology:** The timing of the arterial phase often coincides with the point of maximum breath-holding effort for the patient, increasing the likelihood of motion.[\[1\]](#)

Q3: How can I reduce motion artifacts in my **Eob-dtpa** MRI experiments?

A3: A multi-faceted approach is often most effective:

- **Optimize Patient Comfort and Cooperation:** Ensure the patient is comfortable and well-informed about the need to remain still and the breath-holding instructions.
- **Utilize Motion Correction Techniques:** Employ respiratory and cardiac gating to synchronize image acquisition with physiological movements.[\[4\]](#)[\[5\]](#)
- **Consider Advanced Sequences:** Techniques like Compressed Sensitivity Encoding have shown promise in reducing pulsation artifacts.[\[5\]](#)
- **Adjust Injection Protocol:** Modifying the injection rate of the contrast agent can sometimes help.[\[6\]](#)

Q4: Can the injection rate of Gd-**EOB-DTPA** really affect image quality?

A4: Yes, the injection rate can influence the presence of artifacts, particularly in the arterial phase. Research has shown that a lower injection rate may decrease the incidence of certain artifacts.[\[6\]](#)

Quantitative Data on Injection Rate and Artifact Incidence

The following table summarizes findings from a study comparing the presence of artifacts at different Gd-**EOB-DTPA** injection rates.[\[6\]](#)

Injection Rate	No Artifacts	Artifacts Only in Arterial Phase	Artifacts Only in Portal-Venous Phase	Artifacts in Both Phases	Total Patients
1.0 mL/s	243 (78%)	13 (4%)	16 (5%)	38 (12%)	312
1.5 mL/s	49 (23.5%)	82 (40%)	20 (10%)	53 (25%)	207

A significant difference was found between the two groups regarding the absence of artifacts and the presence of artifacts only during the arterial phase ($p < 0.001$).[\[6\]](#)

Experimental Protocols

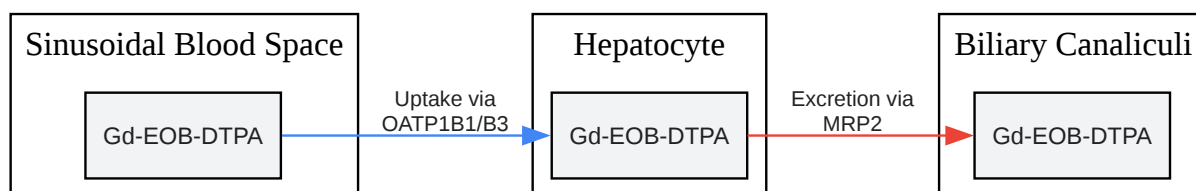
Protocol 1: Gd-**EOB-DTPA** Enhanced Liver MRI for Functional Assessment

This protocol is adapted from studies evaluating liver function using Gd-**EOB-DTPA**.[\[11\]](#)[\[12\]](#)

- Pre-contrast Imaging:
 - Acquire T1-weighted volume-interpolated breath-hold examination (VIBE) sequences with fat suppression before contrast injection.[\[11\]](#)
 - Obtain heavily T2-weighted images for MR cholangiopancreatography (MRCP) if required. This should be done before or within 1.5 minutes of contrast administration to avoid signal loss in the bile ducts.[\[1\]](#)
- Contrast Administration:
 - Administer Gd-**EOB-DTPA** intravenously at a dose of 0.025 mmol/kg of body weight.[\[13\]](#)
 - The injection rate can be varied (e.g., 1.0 mL/s or 1.5 mL/s) to assess its impact on arterial phase artifacts.[\[6\]](#)
- Dynamic Post-contrast Imaging:
 - Arterial Phase: Acquire images approximately 20-35 seconds after the start of injection.
 - Portal Venous Phase: Acquire images at approximately 60 seconds post-injection.[\[1\]](#)
 - Transitional Phase: Acquire images at 120-180 seconds post-injection.[\[1\]](#)
- Hepatobiliary Phase (HBP) Imaging:
 - Acquire T1-weighted VIBE sequences with fat suppression 15-20 minutes after contrast injection.[\[1\]](#)[\[11\]](#)
- Data Analysis (for functional assessment):

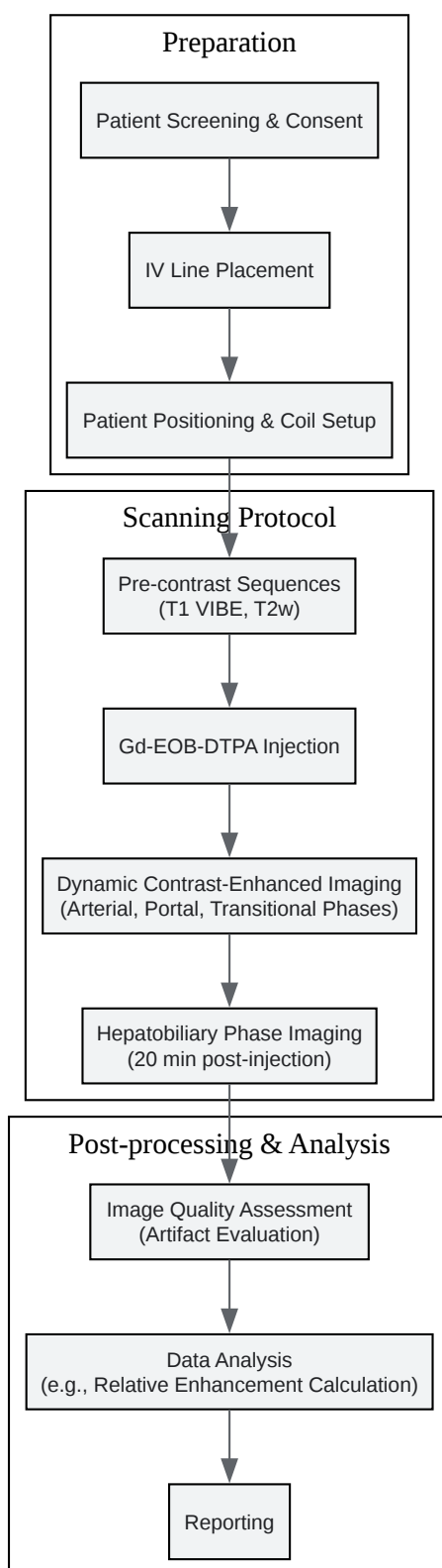
- Measure the mean signal intensity (SI) of the liver parenchyma on pre-contrast (SI_pre) and HBP (SI_post) images.[11]
- Calculate the Relative Enhancement (RE) using the formula: $RE = (SI_{post} - SI_{pre}) / SI_{pre}$. [11] This value can be correlated with liver function.

Visualizations



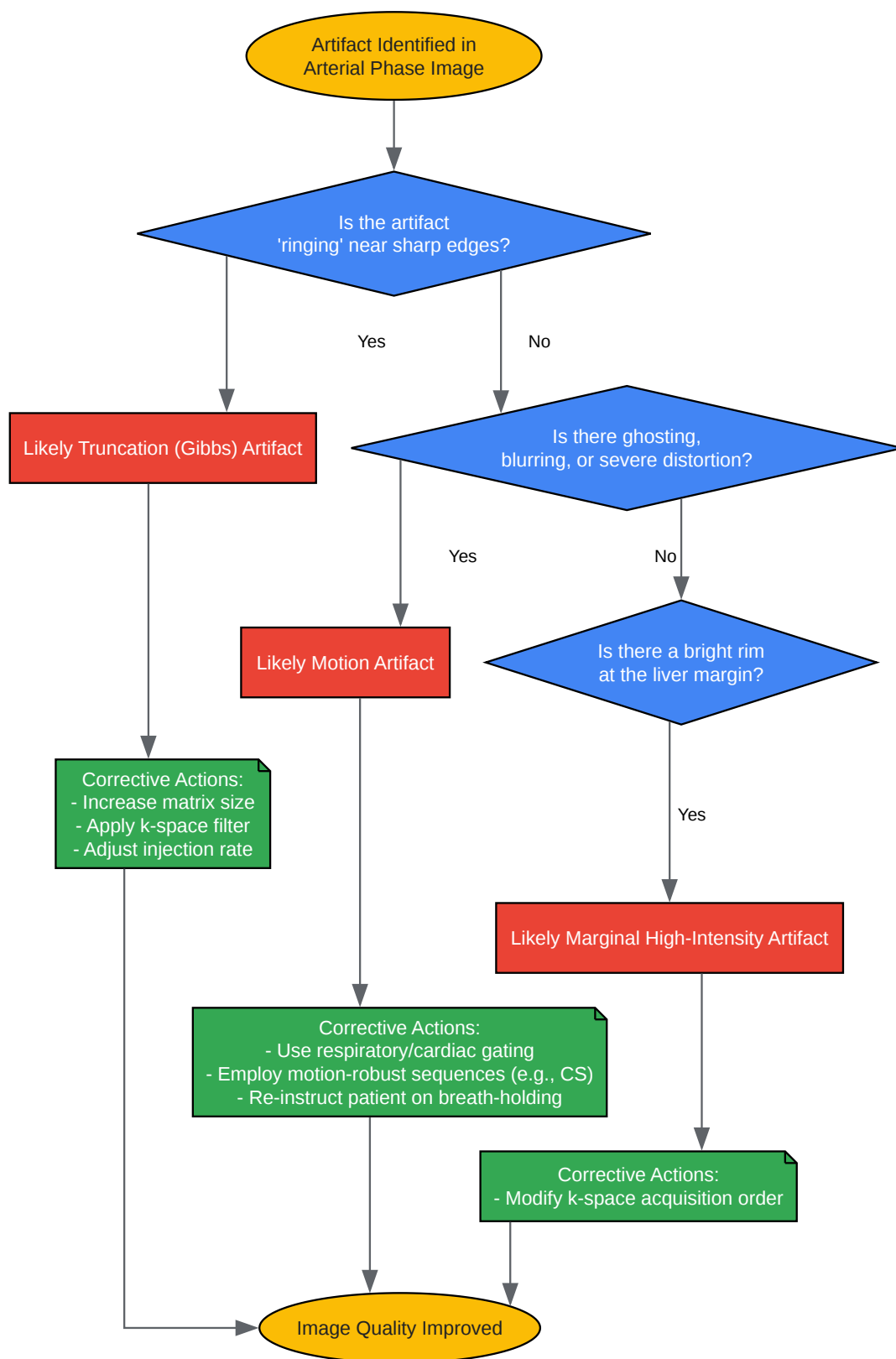
[Click to download full resolution via product page](#)

Caption: Cellular pathway of Gd-**EOB-DTPA** uptake and excretion.



[Click to download full resolution via product page](#)

Caption: Standard experimental workflow for a Gd-**EOB-DTPA** enhanced MRI study.



[Click to download full resolution via product page](#)

Caption: Logical workflow for troubleshooting common arterial phase artifacts.

Need Custom Synthesis?

BenchChem offers custom synthesis for rare earth carbides and specific isotopic labeling.

Email: info@benchchem.com or [Request Quote Online](#).

References

- 1. Diagnosis of Hepatocellular Carcinoma Using Gd-EOB-DTPA MR Imaging - PMC [pmc.ncbi.nlm.nih.gov]
- 2. Troubleshooting Arterial-Phase MR Images of Gadoxetate Disodium-Enhanced Liver - PMC [pmc.ncbi.nlm.nih.gov]
- 3. radiologija.bayer.com [radiologija.bayer.com]
- 4. Artifacts in Magnetic Resonance Imaging - PMC [pmc.ncbi.nlm.nih.gov]
- 5. Pulsation artifact reduction using compressed sensitivity encoding in Gd-EOB-DTPA contrast-enhanced magnetic resonance imaging - PubMed [pubmed.ncbi.nlm.nih.gov]
- 6. Influence of injection rate in determining the development of artifacts during the acquisition of dynamic arterial phase in Gd-EOB-DTPA MRI studies - PubMed [pubmed.ncbi.nlm.nih.gov]
- 7. jahc.it [jahc.it]
- 8. View of Comparative study of different Gd-EOB-DTPA flows as a solution of the Gibbs Arterial Phase artifact in liver MRI | Journal of Advanced Health Care [jahc.it]
- 9. Comparative study of different Gd-EOB-DTPA flows as a solution of the Gibbs Arterial Phase artifact in liver MRI | Journal of Advanced Health Care [jahc.it]
- 10. MRI artifact - Wikipedia [en.wikipedia.org]
- 11. Liver fibrosis and Gd-EOB-DTPA-enhanced MRI: A histopathologic correlation - PMC [pmc.ncbi.nlm.nih.gov]
- 12. Experimental hepatic dysfunction: evaluation by MRI with Gd-EOB-DTPA - PubMed [pubmed.ncbi.nlm.nih.gov]
- 13. Focal hepatic lesions in Gd-EOB-DTPA enhanced MRI: the atlas - PMC [pmc.ncbi.nlm.nih.gov]
- To cite this document: BenchChem. [Eob-dtpa MRI artifacts and correction methods]. BenchChem, [2025]. [Online PDF]. Available at:

[<https://www.benchchem.com/product/b3021170#eob-dtpa-mri-artifacts-and-correction-methods>]

Disclaimer & Data Validity:

The information provided in this document is for Research Use Only (RUO) and is strictly not intended for diagnostic or therapeutic procedures. While BenchChem strives to provide accurate protocols, we make no warranties, express or implied, regarding the fitness of this product for every specific experimental setup.

Technical Support: The protocols provided are for reference purposes. Unsure if this reagent suits your experiment? [[Contact our Ph.D. Support Team for a compatibility check](#)]

Need Industrial/Bulk Grade? [Request Custom Synthesis Quote](#)

BenchChem

Our mission is to be the trusted global source of essential and advanced chemicals, empowering scientists and researchers to drive progress in science and industry.

Contact

Address: 3281 E Guasti Rd
Ontario, CA 91761, United States
Phone: (601) 213-4426
Email: info@benchchem.com