

Breath-hold techniques for arterial phase imaging with Eob-dtpa

Author: BenchChem Technical Support Team. **Date:** December 2025

Compound of Interest

Compound Name: Eob-dtpa

Cat. No.: B3021170

[Get Quote](#)

Technical Support Center: Arterial Phase Imaging with Eob-dtpa

This technical support center provides troubleshooting guidance and frequently asked questions (FAQs) for researchers, scientists, and drug development professionals utilizing gadoxetate disodium (Gd-**Eob-dtpa**, Eovist®/Primovist®) for arterial phase magnetic resonance imaging (MRI).

Troubleshooting Guide

This guide addresses common issues encountered during arterial phase imaging with **Eob-dtpa**, focusing on mitigating motion artifacts and ensuring optimal image quality.

Issue: Severe Respiratory Motion Artifacts in the Arterial Phase (Transient Severe Respiratory Motion - TSRM)

Q1: We are observing significant ghosting and blurring specifically during the arterial phase of our **Eob-dtpa** enhanced liver scans. What could be the cause?

A1: This phenomenon is likely Transient Severe Respiratory Motion (TSRM), a known side effect of Gd-**Eob-dtpa**, occurring in approximately 5-22% of patients.^[1] The exact pathophysiology is not fully understood, but it is characterized by a brief period of involuntary diaphragmatic motion that coincides with the arterial phase acquisition.

Q2: What are the known risk factors for TSRM?

A2: Several potential risk factors have been identified, including:

- Prior history of TSRM: Patients who have experienced TSRM in a previous Gd-**Eob-dtpa** scan are more likely to experience it again.
- High-volume contrast injection: Larger volumes of the contrast agent may be associated with a higher incidence of TSRM.[2]
- Patient-specific factors: Low body weight, a history of allergy to iodinated contrast media, and chronic obstructive pulmonary disease (COPD) have been suggested as potential risk factors, though findings can be inconsistent across studies.[2]

Q3: How can we mitigate or resolve TSRM-related artifacts?

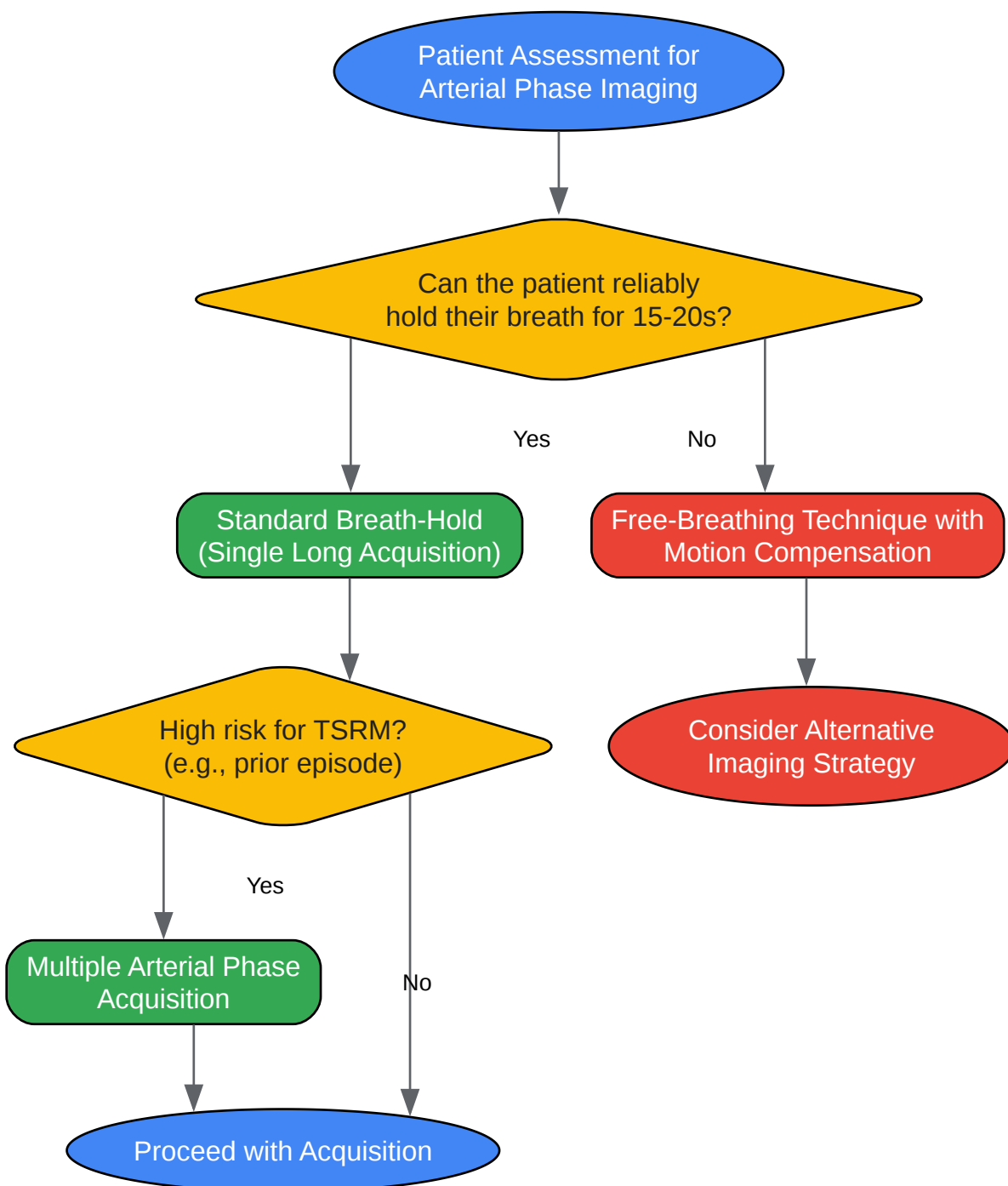
A3: Several strategies can be employed to minimize or overcome TSRM:

- Patient Communication and Coaching:
 - Thoroughly explain the breathing instructions before the scan.
 - Practice the breath-hold maneuver with the patient.
 - Using visualized breath-hold training tools can significantly improve patient compliance and reduce motion artifacts.[3]
- Modified Injection Protocol:
 - Slower Injection Rate: Reducing the injection rate to 1 mL/sec has been proposed as a method to reduce the incidence of TSRM.[2]
 - Dilution: Diluting the contrast agent may also help mitigate this effect.
- Advanced Imaging Techniques:
 - Multiple Arterial Phase Acquisitions: Acquiring several shorter arterial phase scans instead of a single long one increases the probability of obtaining at least one artifact-free phase.

[\[2\]](#)[\[4\]](#)[\[5\]](#) This technique has been shown to provide acceptable image quality in a high percentage of patients who experience TSM.[\[4\]](#)

- Accelerated Imaging: Utilizing parallel imaging techniques (e.g., GRAPPA, SENSE) or compressed sensing can shorten the required breath-hold time, making it easier for patients to comply.
- Free-Breathing Techniques: For patients who are unable to perform a breath-hold, free-breathing acquisition methods with motion compensation can be a viable alternative.[\[1\]](#)

Below is a decision-making workflow for selecting an appropriate breath-hold technique:



[Click to download full resolution via product page](#)

Decision workflow for breath-hold technique selection.

Frequently Asked Questions (FAQs)

Q4: What is the optimal timing for the late arterial phase with **Eob-dtpa**?

A4: The ideal late arterial phase demonstrates enhancement of the hepatic artery and portal vein without significant enhancement of the hepatic veins.[6] With bolus tracking, image acquisition is typically initiated 5-15 seconds after the contrast arrives in the abdominal aorta. [7] For a fixed-delay approach, scanning usually commences around 30-35 seconds after the start of the injection.[6][7]

Q5: Should breath-holds be performed at end-inspiration or end-expiration?

A5: While both can be used, end-expiration is often preferred for abdominal imaging. It is generally more reproducible for patients to perform consistently across multiple breath-holds.

Q6: How do free-breathing techniques compare to breath-hold techniques in terms of image quality?

A6: While breath-hold techniques are generally considered to provide superior image quality by minimizing motion, advances in free-breathing sequences with motion compensation have made them a viable alternative, especially for patients who cannot hold their breath. Some studies have shown that free-breathing techniques can yield comparable diagnostic performance and, in some cases, higher signal-to-noise (SNR) and contrast-to-noise (CNR) ratios than breath-hold diffusion-weighted imaging (DWI).[8] However, other studies comparing dynamic contrast-enhanced free-breathing and breath-hold techniques have found the overall image quality to be similar, with some trade-offs in artifact levels and lesion detectability.[9]

Q7: Can patient coaching and preparation really make a difference in reducing motion artifacts?

A7: Yes. Studies have shown that intensified patient preparation, including education and supervised breath-hold training, can significantly reduce respiratory motion artifacts.[10] Visualized breath-hold training, in particular, has been demonstrated to improve SNR and CNR and reduce artifact scores compared to verbal instructions alone.[3]

Quantitative Data Summary

The following tables summarize quantitative data from various studies comparing different breath-hold techniques for arterial phase imaging with **Eob-dtpa**.

Table 1: Incidence of Transient Severe Respiratory Motion (TSRM) with Gd-**Eob-dtpa**

Study Cohort/Parameter	Reported Incidence of TSRM	Reference
General Patient Population	5% - 22%	[1]
Bi-institutional Study (Site A)	15%	[10]
Bi-institutional Study (Site B)	22.7%	[10]
Multi-center Study	~10% (range 2.4-18%)	[2]

Table 2: Qualitative Image Quality Comparison of Breath-Hold Techniques

Technique	Overall Image Quality Score (Mean \pm SD)	Motion Artifact Score (Mean \pm SD)	Reference
Free-Breathing (XD-VIBE)	Reviewer 1: 3.5 \pm 0.8 Reviewer 2: 3.3 \pm 0.9	Reviewer 1: 3.5 \pm 0.7 Reviewer 2: 3.4 \pm 0.8	[9]
Free-Breathing (GRASP)	Reviewer 1: 3.7 \pm 0.6 Reviewer 2: 3.6 \pm 0.7	Reviewer 1: 3.8 \pm 0.5 Reviewer 2: 3.7 \pm 0.6	[9]
Single Arterial Phase (with TSM)	Often non-diagnostic	4 (severe) to 5 (extensive)	[4]
Multiple Arterial Phase (with TSM)	Acceptable in 90.9% of cases	At least one phase with minimal to moderate artifact	[4]

Note: Image quality and artifact scores are typically on a 5-point Likert scale, where higher scores indicate better quality and lower scores indicate fewer artifacts.

Experimental Protocols

Protocol 1: Standard Breath-Hold Arterial Phase Imaging

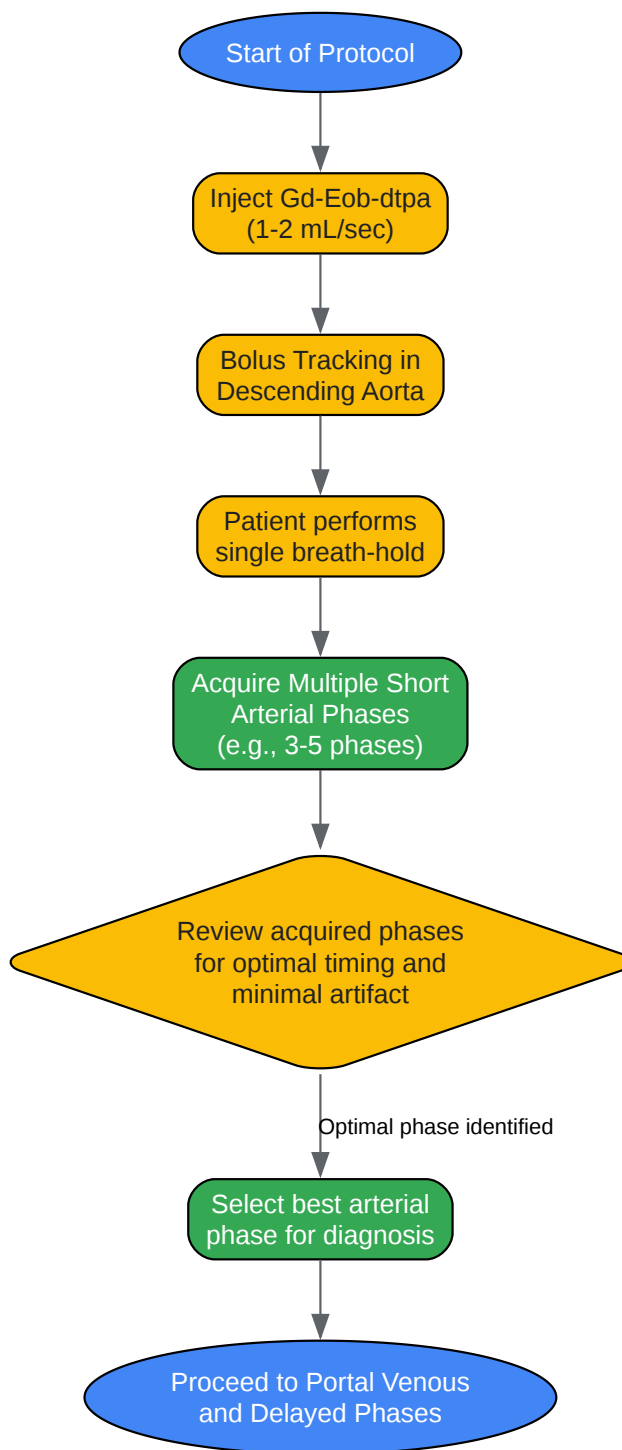
- Patient Preparation:

- Instruct the patient to fast for at least 4 hours prior to the examination.[\[7\]](#)
- Explain the breath-hold procedure clearly and practice with the patient.
- Contrast Injection:
 - Administer Gd-**Eob-dtpa** at a dose of 0.025 mmol/kg body weight.
 - Inject at a rate of 1-2 mL/sec followed by a 20-30 mL saline flush.[\[7\]](#)
- Image Acquisition:
 - Utilize a 3D T1-weighted gradient echo sequence (e.g., VIBE, LAVA, THRIVE).
 - Employ bolus tracking with a region of interest in the descending aorta.
 - Initiate the breath-hold command ("take a breath in, blow it out, and hold") just before the contrast arrives.
 - Start the acquisition approximately 5-15 seconds after contrast detection in the aorta.[\[7\]](#)
 - The acquisition window should be around 15-25 seconds.

Protocol 2: Multiple Arterial Phase Acquisition

- Patient Preparation and Contrast Injection:
 - Follow the same steps as the standard protocol.
- Image Acquisition:
 - Use a sequence that allows for rapid, repeated acquisitions (e.g., TWIST-VIBE, 4D-TRAK).
 - Acquire 3 to 5 short arterial phases within a single breath-hold of approximately 15-25 seconds.[\[11\]](#)
 - This allows for capturing the transition from the early to the late arterial phase, increasing the likelihood of an optimal, artifact-free dataset.

The following diagram illustrates the workflow for a multiple arterial phase acquisition protocol.



[Click to download full resolution via product page](#)

Workflow for multiple arterial phase acquisition.

Protocol 3: Free-Breathing Arterial Phase Imaging

- Patient Preparation and Contrast Injection:
 - Follow the same steps as the standard protocol. Patient coaching on maintaining a regular, shallow breathing pattern is beneficial.
- Image Acquisition:
 - Employ a motion-robust sequence such as radial VIBE or a Cartesian sequence with prospective or retrospective motion correction.
 - These sequences continuously acquire data over a longer period (e.g., 60-90 seconds) during free breathing.
 - The data is then reconstructed to provide images from different phases of respiration, from which a motion-minimized arterial phase can be selected.

Need Custom Synthesis?

BenchChem offers custom synthesis for rare earth carbides and specific isotopic labeling.

Email: info@benchchem.com or [Request Quote Online](#).

References

- 1. Respiratory motion artefacts in Gd-EOB-DTPA (Primovist/Eovist) and Gd-DOTA (Dotarem)-enhanced dynamic phase liver MRI after intensified and standard pre-scan patient preparation: A bi-institutional analysis - PMC [[pmc.ncbi.nlm.nih.gov](https://pubmed.ncbi.nlm.nih.gov/)]
- 2. radiopaedia.org [radiopaedia.org]
- 3. [researchgate.net](https://www.researchgate.net/) [[researchgate.net](https://www.researchgate.net/)]
- 4. spandidos-publications.com [spandidos-publications.com]
- 5. Troubleshooting Arterial-Phase MR Images of Gadoxetate Disodium-Enhanced Liver - PMC [[pmc.ncbi.nlm.nih.gov](https://pubmed.ncbi.nlm.nih.gov/)]
- 6. [youtube.com](https://www.youtube.com/) [[youtube.com](https://www.youtube.com/)]
- 7. [tranow.com](https://www.tranow.com/) [[tranow.com](https://www.tranow.com/)]

- 8. Comparison of breathhold, navigator-triggered, and free-breathing diffusion-weighted MRI for focal hepatic lesions - PubMed [pubmed.ncbi.nlm.nih.gov]
- 9. Free-breathing contrast-enhanced multiphase MRI of the liver in patients with a high risk of breath-holding failure: comparison of compressed sensing-accelerated radial and Cartesian acquisition techniques - PubMed [pubmed.ncbi.nlm.nih.gov]
- 10. researchgate.net [researchgate.net]
- 11. Fast MRI Techniques of the Liver and Pancreaticobiliary Tract: Overview and Application - PMC [pmc.ncbi.nlm.nih.gov]
- To cite this document: BenchChem. [Breath-hold techniques for arterial phase imaging with Eob-dtpa]. BenchChem, [2025]. [Online PDF]. Available at: [https://www.benchchem.com/product/b3021170#breath-hold-techniques-for-arterial-phase-imaging-with-eob-dtpa]

Disclaimer & Data Validity:

The information provided in this document is for Research Use Only (RUO) and is strictly not intended for diagnostic or therapeutic procedures. While BenchChem strives to provide accurate protocols, we make no warranties, express or implied, regarding the fitness of this product for every specific experimental setup.

Technical Support: The protocols provided are for reference purposes. Unsure if this reagent suits your experiment? [[Contact our Ph.D. Support Team for a compatibility check](#)]

Need Industrial/Bulk Grade? [Request Custom Synthesis Quote](#)

BenchChem

Our mission is to be the trusted global source of essential and advanced chemicals, empowering scientists and researchers to drive progress in science and industry.

Contact

Address: 3281 E Guasti Rd
Ontario, CA 91761, United States
Phone: (601) 213-4426
Email: info@benchchem.com