

interpretation pitfalls in sestamibi parathyroid scanning

Author: BenchChem Technical Support Team. **Date:** December 2025

Compound of Interest

Compound Name: *Technetium (99mTc) sestamibi*

Cat. No.: *B018738*

[Get Quote](#)

Technical Support Center: Sestamibi Parathyroid Scanning

This technical support center provides troubleshooting guides and frequently asked questions (FAQs) to address common interpretation pitfalls encountered during sestamibi parathyroid scanning. The information is tailored for researchers, scientists, and drug development professionals.

Troubleshooting Guides

Issue: Positive Sestamibi Scan, but No Adenoma Found During Surgery

Possible Causes and Troubleshooting Steps:

- **False-Positive Scan:** A key challenge in sestamibi scanning is the possibility of a false-positive result, where the scan indicates an adenoma that isn't surgically confirmed. This can occur when tissues other than a parathyroid adenoma concentrate the radioactive tracer to a greater degree than the surrounding tissues.^[1]
 - **Actionable Advice:** Surgeons should be cautious about dismissing a positive scan intraoperatively.^[1] The use of a handheld gamma probe during surgery can help locate the radioactive tissue identified on the preoperative scan.^[1] If an adenoma is not immediately apparent, it should not be assumed that the scan was false-positive.^[1]

- Misinterpretation of Thyroid Nodules: Thyroid adenomas are a frequently cited cause of false-positive scans.[1][2]
 - Actionable Advice: Including left and right oblique views during the scan can help differentiate a hot thyroid nodule from a parathyroid adenoma, as a thyroid nodule will not be distinct from the thyroid.[1] A positive scan should only be considered as such if it reveals a single focus of radioactivity clearly separate from the thyroid.[1]
- Ectopic Parathyroid Adenomas: Parathyroid adenomas can be located in unusual (ectopic) positions, which can lead to surgical challenges.[3]
 - Actionable Advice: If a suspected adenoma is not found in the typical locations, consider the possibility of an ectopic gland. Advanced imaging techniques like 4D-MRI may be necessary in such cases.[3]

Issue: Negative Sestamibi Scan in a Patient with Confirmed Primary Hyperparathyroidism

Possible Causes and Troubleshooting Steps:

- Multi-gland Disease: The sensitivity of sestamibi scans is reduced in the presence of multi-gland disease, such as parathyroid hyperplasia.[3][4] Patients with negative preoperative scans have a significantly higher likelihood of multi-glandular disease.[3] Hyperplastic glands generally do not absorb enough radioactivity to be detected by the scan.[5]
 - Actionable Advice: A negative scan does not rule out primary hyperparathyroidism.[6] In cases of negative imaging, intraoperative PTH (iOPTh) monitoring can guide the surgical approach and help ensure all hypersecreting tissue is removed.[3]
- Small Adenomas: The scan's sensitivity is lower for smaller adenomas, particularly those weighing less than 500 mg.[4] Patients with negative scans tend to have smaller adenomas.[3]
 - Actionable Advice: Consider alternative or complementary imaging modalities like high-resolution ultrasound, which may have better sensitivity for smaller glands.

- **Histological Factors:** The cellular composition of the adenoma influences tracer uptake. Adenomas composed predominantly of chief cells are more likely to result in a negative scan, while those with a higher proportion of oxyphil cells, which are rich in mitochondria, tend to produce positive scans.[\[7\]](#)[\[8\]](#)
 - **Actionable Advice:** Be aware that the histological characteristics of the adenoma can impact scan results. A negative scan may be unavoidable in patients with chief cell-predominant adenomas.[\[8\]](#)
- **Co-existing Thyroid Disease:** The presence of thyroid conditions like nodular goiter or autoimmune thyroid disease can decrease the diagnostic accuracy of sestamibi scans.[\[3\]](#)
 - **Actionable Advice:** In patients with known thyroid disease, consider using a dual-isotope subtraction technique (e.g., with Technetium-99m pertechnetate or Iodine-123) to help differentiate parathyroid from thyroid tissue.[\[9\]](#)[\[10\]](#)

Frequently Asked Questions (FAQs)

Q1: What are the main causes of false-positive sestamibi parathyroid scans?

A1: False-positive sestamibi scans can be attributed to several factors where non-parathyroid tissues show increased tracer uptake. The most common causes include:

- **Thyroid abnormalities:** Thyroid adenomas, nodular goiter, and thyroid cancer (including follicular, Hürthle cell, and papillary carcinomas) can all lead to false-positive results.[\[1\]](#)[\[2\]](#)[\[11\]](#)
- **Lymph nodes:** While less common, inflamed or metastatic lymph nodes can sometimes show increased sestamibi uptake.[\[1\]](#)
- **Other tissues:** Rare causes of false-positives include brown adipose tissue and thymomas.[\[2\]](#)

Q2: What factors contribute to false-negative sestamibi parathyroid scans?

A2: A false-negative scan occurs when a patient has a parathyroid adenoma, but the scan fails to detect it. Key contributing factors include:

- Multi-glandular disease: The scan is less sensitive in detecting parathyroid hyperplasia or multiple adenomas compared to a single adenoma.[3][4]
- Small gland size: Smaller adenomas are more likely to be missed by the scan.[3][4]
- Histopathology: Adenomas with a lower density of mitochondria-rich oxyphil cells and a predominance of chief cells have reduced sestamibi uptake.[7][8]
- Ectopic gland location: Adenomas in unusual locations can be difficult to identify.[3]
- Concurrent thyroid disease: Thyroid pathologies can interfere with the interpretation of the scan.[3]
- Mild disease: Lower levels of serum calcium and parathyroid hormone (PTH) have been correlated with reduced scan sensitivity.[3][12]

Q3: Can technical errors affect the outcome of a sestamibi scan?

A3: Yes, technical aspects of the scan are crucial for its accuracy. Poor scanning techniques are a significant reason for negative or incorrect scans.[5][6] Important technical considerations include:

- Imaging protocol: The use of both early and delayed imaging, as well as oblique views, is important for accurate interpretation.[5]
- Camera positioning: The gamma camera should be positioned as close to the patient as possible (ideally less than 8 cm).[5]
- SPECT/CT: The addition of single-photon emission computed tomography (SPECT), especially when combined with CT (SPECT/CT), improves the three-dimensional localization of adenomas.[13][14]

Q4: What is the role of dual-isotope imaging in sestamibi parathyroid scanning?

A4: Dual-isotope imaging involves the use of a second radiotracer that is taken up by the thyroid gland (e.g., Technetium-99m pertechnetate or Iodine-123) in addition to sestamibi.[9] The thyroid-specific image is then subtracted from the sestamibi image, which helps to isolate

and identify parathyroid tissue that retains the sestamibi tracer.[9] This technique can be particularly useful in patients with co-existing thyroid abnormalities to reduce the rate of false-positive results.[10]

Data Presentation

Table 1: Factors Influencing Sestamibi Scan Accuracy

Factor	Impact on Scan Accuracy	Reference
Gland Size	Smaller adenomas (<500mg) are associated with lower sensitivity.	[4]
Histology	Oxyphil-predominant adenomas have higher uptake and are more likely to be positive. Chief cell-predominant adenomas are more often associated with negative scans.	[7][8]
Disease Type	Sensitivity is lower in multi-gland disease (hyperplasia) compared to single adenomas.	[3][4]
Biochemical Severity	Higher serum calcium and PTH levels are associated with a higher likelihood of a positive scan.	[3][12]
Co-existing Thyroid Disease	Can decrease the sensitivity and specificity of the scan.	[3]

Experimental Protocols

Dual-Phase Sestamibi Parathyroid Scintigraphy Protocol

This protocol is a generalized representation and may vary between institutions.

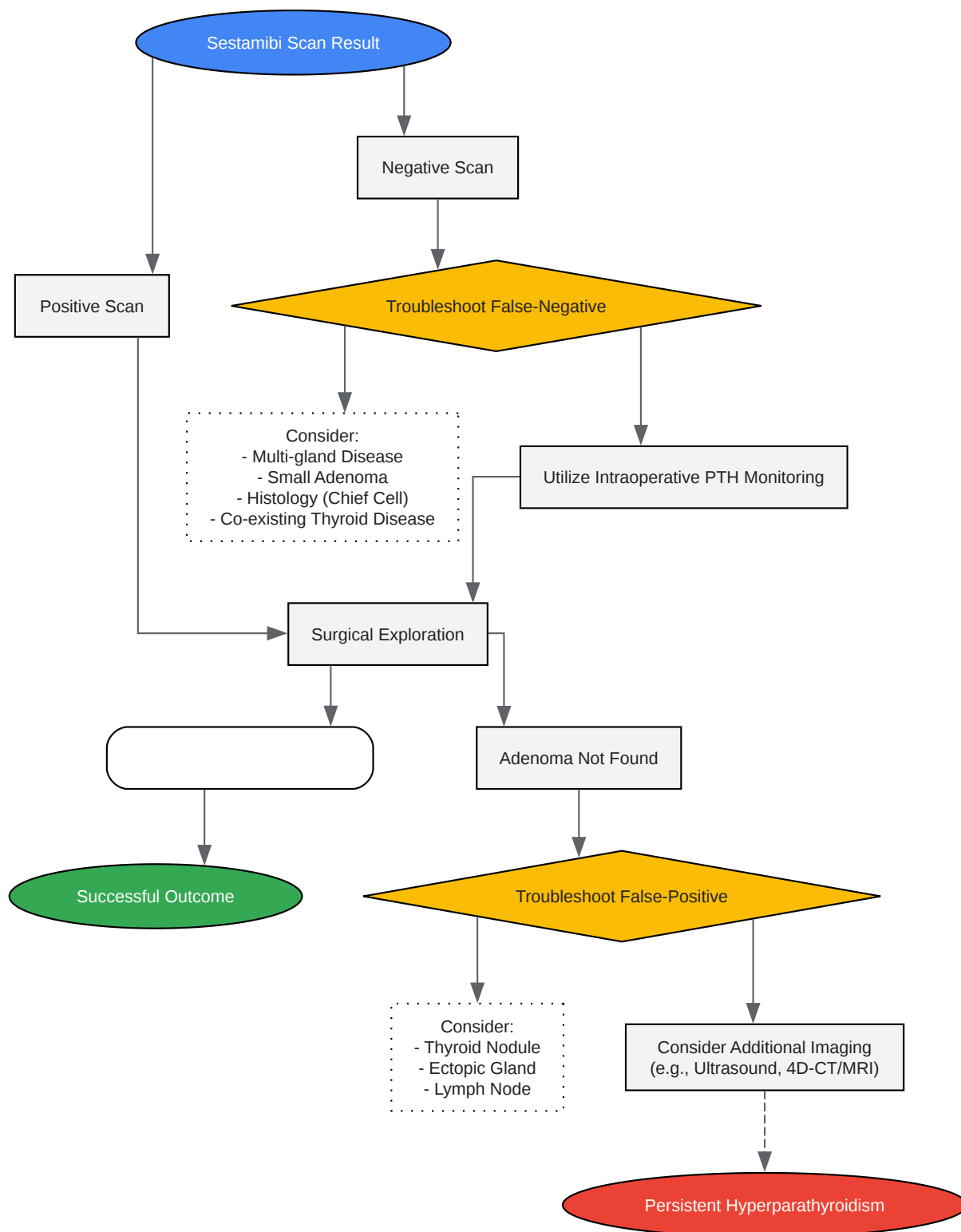
- Patient Preparation: No specific patient preparation is typically required.[5] Some institutions may advise the patient to drink a lemon juice solution to reduce salivary gland uptake, though its utility is debated.[5]
- Radiopharmaceutical Administration:
 - An intravenous injection of 740–1,110 MBq (20–30 mCi) of Technetium-99m (99mTc) sestamibi is administered.[9]
- Early Imaging:
 - Imaging is initiated approximately 5-15 minutes post-injection.[5][15]
 - Views obtained typically include anterior neck, anterior neck with a marker, anterior mediastinum, and left and right anterior oblique views.[5]
- Delayed Imaging:
 - Delayed images are acquired 1.5 to 3 hours post-injection.[13]
 - The same views as the early imaging phase are typically acquired.
- SPECT/CT (Optional but Recommended):
 - SPECT imaging can be performed after the early planar images are acquired.[9]
 - This provides three-dimensional localization of the tracer uptake.
- Image Interpretation:
 - A parathyroid adenoma is typically identified as a focus of increased tracer uptake that persists or becomes more prominent on the delayed images compared to the surrounding thyroid tissue, which tends to wash out the tracer more rapidly.[9]

Dual-Isotope Subtraction Scintigraphy Protocol (99mTc-Sestamibi/99mTc-Per technetate)

- Radiopharmaceutical Administration (Sestamibi):

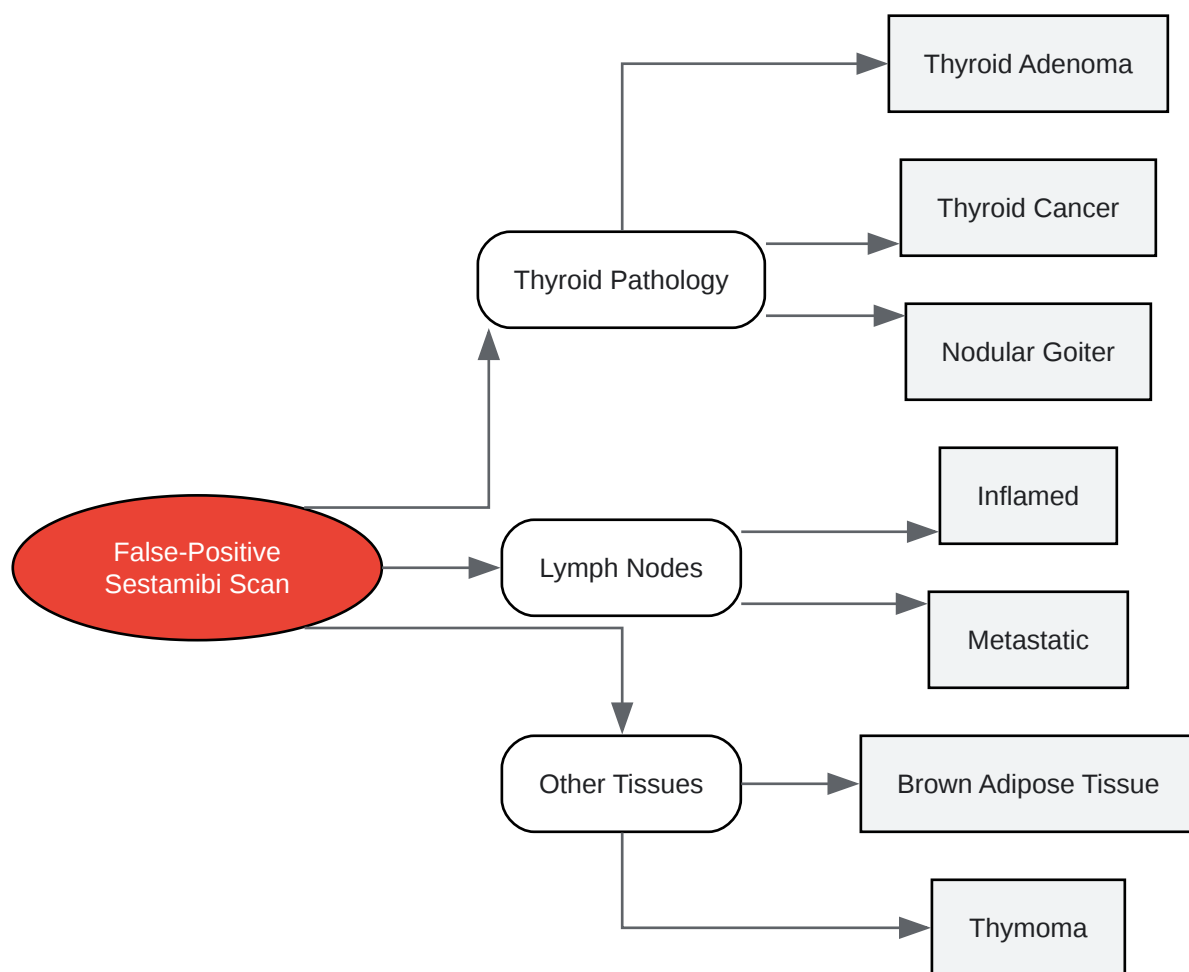
- An intravenous injection of ^{99m}Tc -sestamibi is administered as in the dual-phase protocol.
- Early Sestamibi Imaging:
 - Early images of the neck are acquired.
- Radiopharmaceutical Administration (Pertechnetate):
 - Following the early sestamibi images, an intravenous injection of 74–370 MBq (2–10 mCi) of ^{99m}Tc -pertechnetate is given.^[9]
- Pertechnetate Imaging:
 - Images of the thyroid gland are acquired.
- Image Processing:
 - The pertechnetate image (representing the thyroid) is digitally subtracted from the sestamibi image.
- Image Interpretation:
 - Any remaining focus of radioactivity after subtraction is considered to be of parathyroid origin.^[9]

Visualizations



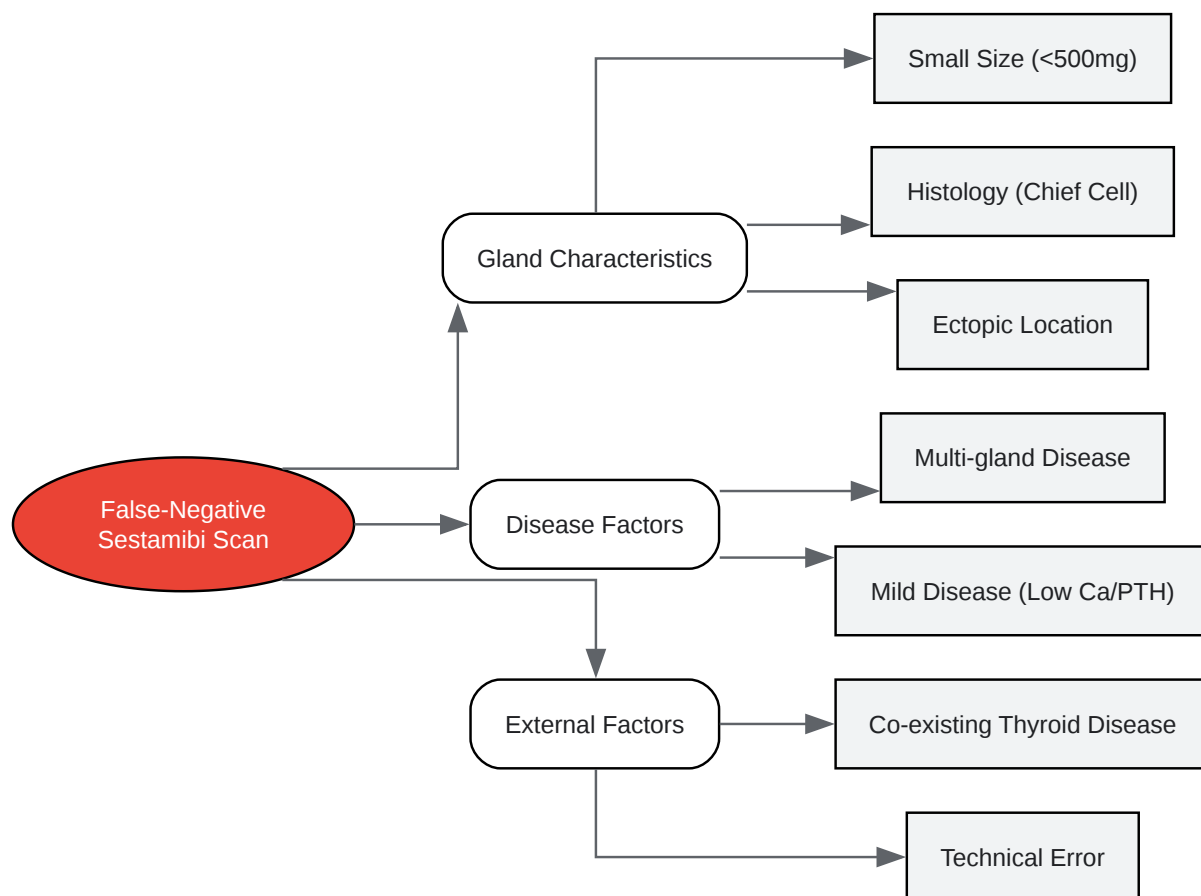
[Click to download full resolution via product page](#)

Caption: Workflow for troubleshooting sestamibi scan interpretation.



[Click to download full resolution via product page](#)

Caption: Common causes of false-positive sestamibi scans.



[Click to download full resolution via product page](#)

Caption: Common causes of false-negative sestamibi scans.

Need Custom Synthesis?

BenchChem offers custom synthesis for rare earth carbides and specific isotopic labeling.

Email: info@benchchem.com or [Request Quote Online](#).

References

- 1. The False-Positive Parathyroid Sestamibi: A Real or Perceived Problem and A Case for Radioguided Parathyroidectomy - PMC [pmc.ncbi.nlm.nih.gov]
- 2. researchgate.net [researchgate.net]

- 3. False-negative 99mTc-sestamibi scans: factors and outcomes in primary hyperparathyroidism - PMC [pmc.ncbi.nlm.nih.gov]
- 4. Limitations of Tc99m-MIBI-SPECT Imaging Scans in Persistent Primary Hyperparathyroidism - PMC [pmc.ncbi.nlm.nih.gov]
- 5. Parathyroid Sestamibi Scan Technical Page: How Parathyroid Sestamibi Scanning is Performed. This is a page for Radiologists and Nuclear Medicine Techs. [parathyroid.com]
- 6. Sestamibi Scan for Parathyroid Disease. Sestamibi parathyroid x-ray scan locates problem parathyroid glands and parathyroid tumors. Sestamibi is the BEST parathyroid x-ray. [parathyroid.com]
- 7. Sestamibi parathyroid scan - Wikipedia [en.wikipedia.org]
- 8. Negative imaging studies for primary hyperparathyroidism are unavoidable: correlation of sestamibi and high-resolution ultrasound scanning with histological analysis in 150 patients - PubMed [pubmed.ncbi.nlm.nih.gov]
- 9. SNM Practice Guideline for Parathyroid Scintigraphy 4.0 | Journal of Nuclear Medicine Technology [tech.snmjournals.org]
- 10. 99mTc-Sestamibi/123I Subtraction SPECT/CT in Parathyroid Scintigraphy: Is Additional Pinhole Imaging Useful? - PMC [pmc.ncbi.nlm.nih.gov]
- 11. Sestamibi scintigraphy for parathyroid localisation: a reminder of the dangers of false positives - PMC [pmc.ncbi.nlm.nih.gov]
- 12. Differences in Accuracy of 99mTc-Sestamibi Scanning Between Severe and Mild Forms of Primary Hyperparathyroidism | Journal of Nuclear Medicine Technology [tech.snmjournals.org]
- 13. med.emory.edu [med.emory.edu]
- 14. Quantitative application of dual-phase 99mTc-sestamibi SPECT/CT imaging of parathyroid lesions: identification of optimal timing in secondary hyperparathyroidism - PMC [pmc.ncbi.nlm.nih.gov]
- 15. hyperparathyroidmd.com [hyperparathyroidmd.com]
- To cite this document: BenchChem. [interpretation pitfalls in sestamibi parathyroid scanning]. BenchChem, [2025]. [Online PDF]. Available at: [https://www.benchchem.com/product/b018738#interpretation-pitfalls-in-sestamibi-parathyroid-scanning]

Disclaimer & Data Validity:

The information provided in this document is for Research Use Only (RUO) and is strictly not intended for diagnostic or therapeutic procedures. While BenchChem strives to provide accurate protocols, we make no warranties, express or implied, regarding the fitness of this product for every specific experimental setup.

Technical Support: The protocols provided are for reference purposes. Unsure if this reagent suits your experiment? [[Contact our Ph.D. Support Team for a compatibility check](#)]

Need Industrial/Bulk Grade? [Request Custom Synthesis Quote](#)

BenchChem

Our mission is to be the trusted global source of essential and advanced chemicals, empowering scientists and researchers to drive progress in science and industry.

Contact

Address: 3281 E Guasti Rd
Ontario, CA 91761, United States
Phone: (601) 213-4426
Email: info@benchchem.com