

identifying and mitigating sestamibi imaging artifacts.

Author: BenchChem Technical Support Team. **Date:** December 2025

Compound of Interest

Compound Name: *Technetium (99mTc) sestamibi*

Cat. No.: *B018738*

[Get Quote](#)

Technical Support Center: Sestamibi Imaging

This technical support center provides troubleshooting guides and frequently asked questions to help researchers, scientists, and drug development professionals identify and mitigate common artifacts in Technetium-99m Sestamibi (MIBI) imaging.

Troubleshooting Guides

This section addresses specific artifacts you may encounter during Sestamibi SPECT imaging.

1. Soft Tissue Attenuation Artifacts

- Question: My reconstructed images show a perfusion defect in the anterior or inferior wall of the myocardium, but I suspect it's an artifact. What could be the cause and how can I fix it?
- Answer: This is likely a soft tissue attenuation artifact, one of the most common issues in myocardial perfusion imaging.^{[1][2]} It occurs when photons emitted from the radiotracer are absorbed by overlying tissue, such as the breast or diaphragm, creating an apparent, but false, perfusion defect.
 - Causes:
 - Breast Attenuation: Most common in female patients, this typically creates a fixed defect in the anterior wall.^[1] The position of the breast can also change between rest and

stress imaging, sometimes resulting in a reversible defect that can be mistaken for ischemia.[1]

- Diaphragmatic Attenuation: More common in male patients, this can cause a fixed defect in the inferior wall.[1]
- Mitigation and Correction Strategies:
 - Review Raw Data: Always review the raw cine images to visually identify attenuating structures.[1][3]
 - Prone Imaging: Acquiring an additional set of images with the patient in the prone position can help differentiate a true defect from a diaphragmatic attenuation artifact.[1] However, prone imaging may introduce an antero-septal attenuation defect.
 - Attenuation Correction (AC): Using a hybrid SPECT/CT scanner to acquire a CT-based attenuation map is a highly effective method to correct for these artifacts.[2]
 - Gated SPECT: Can help differentiate attenuation artifacts from true infarcts.

2. Patient Motion Artifacts

- Question: The borders of the myocardium in my reconstructed images appear blurry, and there are streaks or "tails" of activity. What is causing this?
- Answer: These are classic signs of patient motion during image acquisition.[3][4][5] Motion, including both sudden movements and gradual "upward creep" of the heart after stress, can lead to significant image degradation and misinterpretation.[6]
 - Causes:
 - Patient discomfort or inability to remain still for the duration of the scan.[1]
 - Respiratory motion, which can cause blurring and artificial defects, particularly in the infero-apical region.[4][5]
 - Mitigation and Correction Strategies:

- Patient Comfort: Ensure the patient is as comfortable as possible before starting the acquisition to minimize voluntary motion.[1]
- Motion Detection and Correction Software: Most modern systems have software algorithms that can detect and correct for patient motion.[4][7][8] It's crucial to review the raw data to confirm the presence of motion.[3]
- Respiratory Gating: For respiratory motion, gated acquisition techniques can be employed to minimize blurring.[4]
- Re-acquisition: If significant motion is detected before the patient leaves the lab, the best solution is often to re-acquire the images.[9]

3. Extracardiac Activity Artifacts

- Question: There is high uptake in the liver or gut that is interfering with the evaluation of the inferior myocardial wall. How can I manage this?
- Answer: This is an artifact caused by extracardiac uptake of Sestamibi, particularly in the liver, gallbladder, and gastrointestinal tract.[10][11] This can cause artificially increased counts in the adjacent inferior wall due to scatter and volume averaging, potentially masking a true defect.[1]
 - Causes:
 - Sestamibi is cleared through the hepatobiliary system, leading to physiological uptake in the liver and gut.[10]
 - Suboptimal stress levels can be associated with higher abdominal background activity.[10]
 - Mitigation and Correction Strategies:
 - Delayed Imaging: In some cases, waiting for a longer period between injection and imaging can allow for further clearance of the radiotracer from the liver.

- **Fatty Meal or Milk:** Giving the patient a fatty meal or milk after injection can sometimes promote gallbladder contraction and clearance of activity.
- **Image Processing Techniques:** Specialized reconstruction algorithms can help to separate the myocardial activity from the adjacent extracardiac uptake.[\[11\]](#) Reviewing the raw data is essential to identify the source and location of the extracardiac activity.
[\[12\]](#)

Summary of Common Artifacts and Solutions

Artifact Type	Common Causes	Imaging Characteristics	Mitigation & Correction Strategies
Soft Tissue Attenuation	Breast tissue, diaphragm, large body habitus. [1]	Fixed or reversible defects (anterior, inferior walls). [1] [13]	Attenuation correction (SPECT/CT), prone imaging, gated SPECT.
Patient Motion	Patient discomfort, long scan times, respiratory motion. [4]	Blurry myocardial borders, streaks, distorted LV shape. [3] [5]	Ensure patient comfort, use motion correction software, respiratory gating, re-acquire images. [1] [4] [9]
Extracardiac Activity	Hepatobiliary clearance of Sestamibi. [10]	High uptake in liver/gut obscuring the inferior wall. [11]	Delayed imaging, fatty meal, specialized reconstruction algorithms. [11]
Instrument/Processing Errors	Center of rotation misalignment, flood field non-uniformity. [3]	Ring artifacts, oblong cavity, image blur. [3]	Regular camera quality control, reprocess data with correct parameters. [3]

Frequently Asked Questions (FAQs)

- Q1: What is the first step I should take when I suspect an artifact in my Sestamibi scan?

- A1: Always begin by reviewing the raw projection data in a cine loop.[1][3] This allows you to visually inspect for patient motion, identify the location and intensity of extracardiac activity, and spot potential attenuation from overlying tissue before interpreting the processed images.
- Q2: How can I differentiate between a true myocardial infarction and a soft tissue attenuation artifact?
 - A2: This can be challenging. A true infarct will typically show a corresponding wall motion abnormality on gated SPECT images. Attenuation artifacts, on the other hand, often show normal wall motion. Comparing supine and prone images or using CT-based attenuation correction are definitive ways to resolve the issue.[2]
- Q3: Can the way the Sestamibi radiopharmaceutical is prepared affect image quality?
 - A3: Yes, proper quality control of the radiopharmaceutical is crucial.[14][15] Impurities in the preparation can lead to altered biodistribution and potential artifacts. It is essential to follow standardized procedures for preparation and radiochemical purity testing.[14][16][17]
- Q4: Does the type of patient stress (exercise vs. pharmacologic) influence the likelihood of artifacts?
 - A4: Yes. For example, patients undergoing pharmacologic stress may experience more discomfort, potentially leading to increased respiratory motion.[5] Additionally, suboptimal exercise levels can be associated with increased abdominal tracer uptake, which can interfere with inferior wall assessment.[10]
- Q5: Are there any patient preparation steps that can minimize artifacts?
 - A5: Absolutely. Proper patient preparation is a key first step.[1] This includes ensuring the patient has followed fasting instructions and avoided caffeine (for pharmacologic stress). [1] Also, ensuring the patient is comfortable and well-informed about the need to remain still can significantly reduce motion artifacts.[1]

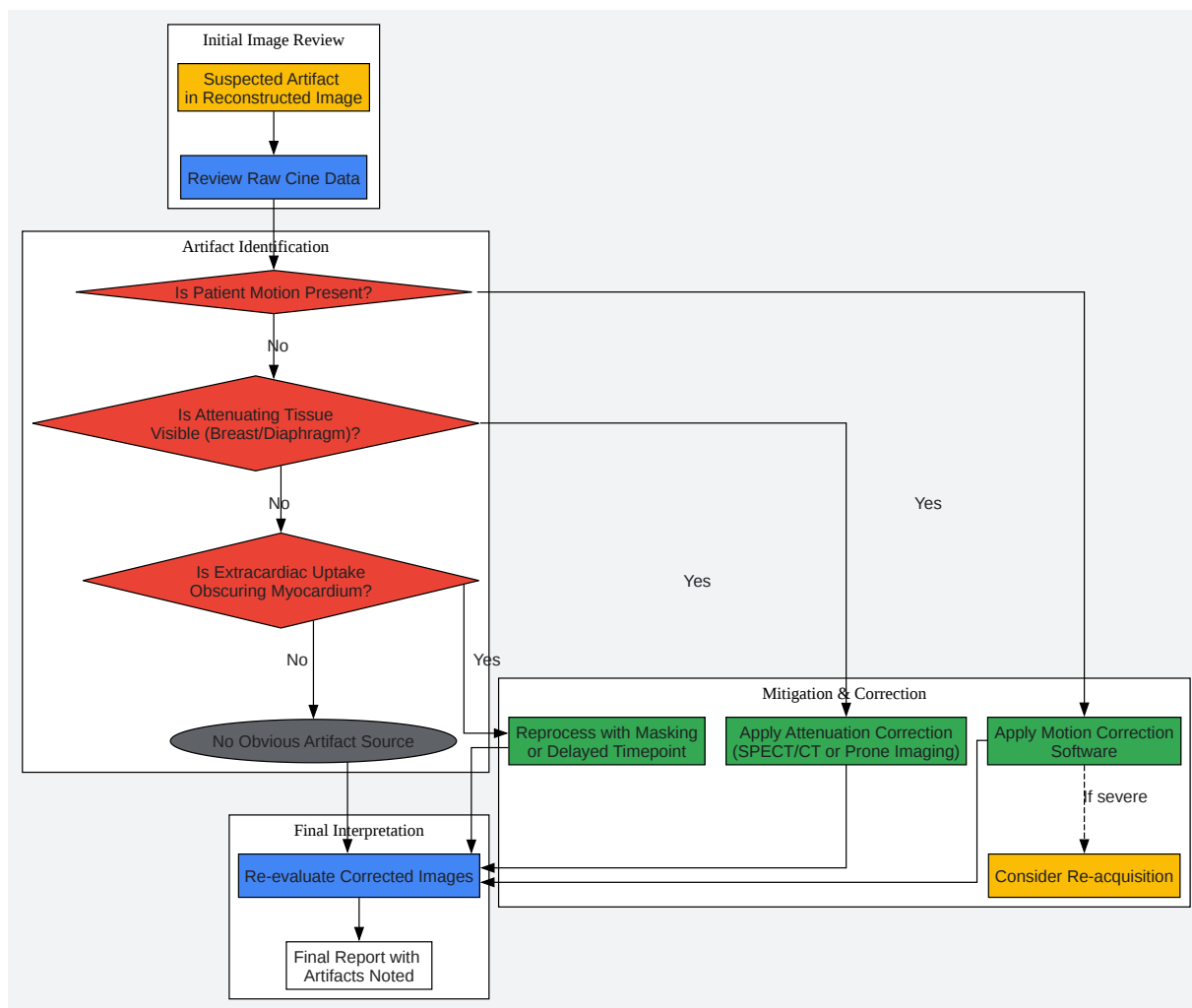
Experimental Protocols

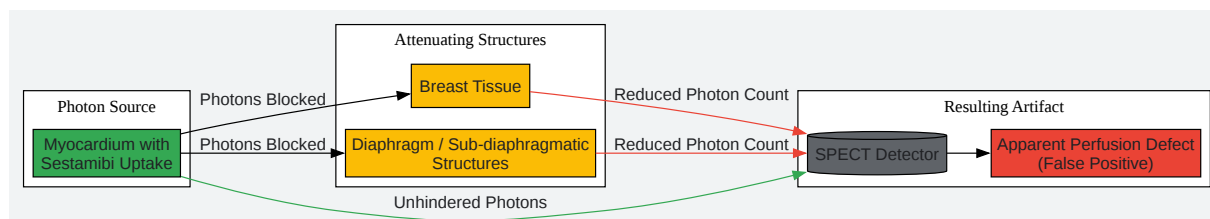
Protocol: Quality Control for Sestamibi Imaging

A strict and regular quality control (QC) protocol is essential to prevent instrument-related artifacts.[18]

- Daily QC:
 - Flood Field Uniformity: Acquire a high-count flood image to check for non-uniformities in the detector, which can cause "ring" artifacts.[3]
 - Peaking: Ensure the camera's energy window is correctly centered on the 140-keV photopeak of Technetium-99m.
- Weekly/Quarterly QC:
 - Center of Rotation (COR) Calibration: Perform a COR test to ensure proper alignment of the detector heads. Misalignment can lead to blurring and distortion in the reconstructed images.[3]
- Data Processing QC:
 - Review Reconstruction Parameters: Always review the automated reconstruction axes. Incorrectly placed axes can distort the shape of the myocardium and create false defects.
 - Verify Rest vs. Stress Alignment: Ensure the rest and stress datasets are properly aligned before interpretation.

Visualizations





[Click to download full resolution via product page](#)

Need Custom Synthesis?

BenchChem offers custom synthesis for rare earth carbides and specific isotopic labeling.

Email: info@benchchem.com or [Request Quote Online](#).

References

- 1. Artifacts and Pitfalls in Myocardial Perfusion Imaging | Journal of Nuclear Medicine Technology [tech.snmjournals.org]
- 2. Added Value of CT Attenuation Correction and Prone Positioning in Improving Breast and Subdiaphragmatic Attenuation in Myocardial Perfusion Imaging - PubMed [pubmed.ncbi.nlm.nih.gov]
- 3. static1.squarespace.com [static1.squarespace.com]
- 4. Correction of Heart Motion Due to Respiration in Clinical Myocardial Perfusion SPECT Scans Using Respiratory Gating | Journal of Nuclear Medicine [jnm.snmjournals.org]
- 5. asnc.org [asnc.org]
- 6. tech.snmjournals.org [tech.snmjournals.org]
- 7. Value of automatic patient motion detection and correction in myocardial perfusion imaging using a CZT-based SPECT camera - PMC [pmc.ncbi.nlm.nih.gov]
- 8. Detection and Correction of Patient Motion in SPECT Imaging | Journal of Nuclear Medicine Technology [tech.snmjournals.org]

- 9. youtube.com [youtube.com]
- 10. Increased extra-cardiac background uptake on immediate and delayed post-stress images with 99Tcm sestamibi: determinants, independence, and significance of counts in lung, abdomen and myocardium - PubMed [pubmed.ncbi.nlm.nih.gov]
- 11. SPECT reconstruction using preprocessing masking for extra-cardiac uptake versus standard processing in 99mTc-sestamibi myocardial perfusion imaging - PubMed [pubmed.ncbi.nlm.nih.gov]
- 12. Unusual extracardiac findings detected on myocardial perfusion single photon emission computed tomography studies with Tc-99m sestamibi - PubMed [pubmed.ncbi.nlm.nih.gov]
- 13. Identifying and Correcting Commonly Encountered Artifacts in Diagnostic Myocardial Perfusion Scan Interpretation: An Interactive Exhibit for Physicians | Journal of Nuclear Medicine [jnm.snmjournals.org]
- 14. Rapid preparation and quality control method for technetium-99m-2-methoxy isobutyl isonitrile (technetium-99m-sestamibi) - PubMed [pubmed.ncbi.nlm.nih.gov]
- 15. A Better Method of Quality Control for Technetium-99m Sestamibi | Journal of Nuclear Medicine Technology [tech.snmjournals.org]
- 16. tech.snmjournals.org [tech.snmjournals.org]
- 17. pdfs.semanticscholar.org [pdfs.semanticscholar.org]
- 18. revistamedicinamilitara.ro [revistamedicinamilitara.ro]
- To cite this document: BenchChem. [identifying and mitigating sestamibi imaging artifacts.]. BenchChem, [2025]. [Online PDF]. Available at: [https://www.benchchem.com/product/b018738#identifying-and-mitigating-sestamibi-imaging-artifacts]

Disclaimer & Data Validity:

The information provided in this document is for Research Use Only (RUO) and is strictly not intended for diagnostic or therapeutic procedures. While BenchChem strives to provide accurate protocols, we make no warranties, express or implied, regarding the fitness of this product for every specific experimental setup.

Technical Support: The protocols provided are for reference purposes. Unsure if this reagent suits your experiment? [[Contact our Ph.D. Support Team for a compatibility check](#)]

Need Industrial/Bulk Grade? [Request Custom Synthesis Quote](#)

BenchChem

Our mission is to be the trusted global source of essential and advanced chemicals, empowering scientists and researchers to drive progress in science and industry.

Contact

Address: 3281 E Guasti Rd

Ontario, CA 91761, United States

Phone: (601) 213-4426

Email: info@benchchem.com