

# Unveiling Liver Lesions: A Comparative Guide to Gadoxetate Disodium in Diagnostic Imaging

**Author:** BenchChem Technical Support Team. **Date:** December 2025

## Compound of Interest

Compound Name: *Gadoxetate Disodium*

Cat. No.: *B1674393*

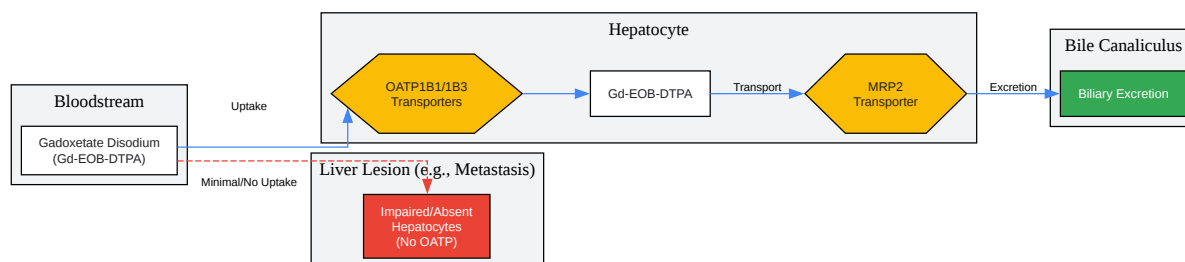
[Get Quote](#)

For researchers, scientists, and drug development professionals, the precise diagnosis of focal liver lesions is paramount. This guide provides an objective comparison of the diagnostic accuracy of **Gadoxetate Disodium** (Gd-EOB-DTPA) with other magnetic resonance imaging (MRI) contrast agents, supported by experimental data and detailed methodologies.

**Gadoxetate disodium**, marketed as Eovist® or Primovist®, is a gadolinium-based contrast agent specifically designed for liver imaging.<sup>[1]</sup> Its unique properties offer a dual-phase imaging capability, providing both dynamic and hepatobiliary phase information, which can enhance the detection and characterization of focal liver lesions.<sup>[2][3]</sup>

## Mechanism of Action

**Gadoxetate disodium**'s efficacy lies in its dual excretion pathway.<sup>[1][4]</sup> Initially, it distributes in the extracellular space, allowing for dynamic vascular imaging similar to conventional extracellular contrast agents.<sup>[5]</sup> Subsequently, it is selectively taken up by functional hepatocytes through organic anion-transporting polypeptides (OATPs), primarily OATP1B1 and OATP1B3.<sup>[4][5]</sup> This hepatocyte-specific uptake leads to a distinct hepatobiliary phase, typically 20 minutes post-injection, where healthy liver parenchyma enhances.<sup>[3][6]</sup> Most malignant lesions, lacking functional hepatocytes, do not take up the agent and thus appear as hypointense areas against the bright liver background.<sup>[4][7]</sup> Approximately 50% of the injected dose is excreted via the biliary system, while the other 50% is eliminated renally.<sup>[7][8]</sup>



[Click to download full resolution via product page](#)

Mechanism of **Gadoxetate Disodium** uptake and excretion in the liver.

## Comparative Diagnostic Accuracy

The diagnostic performance of **gadoxetate disodium**-enhanced MRI has been extensively compared to other contrast agents, primarily extracellular contrast agents (ECAs) and superparamagnetic iron oxide (SPIO) particles.

## Gadoxetate Disodium vs. Extracellular Contrast Agents (ECAs)

ECAs, such as gadobenate dimeglumine, distribute in the extracellular space and provide information based on tissue vascularity. While ECAs are effective, the additional hepatobiliary phase of **gadoxetate disodium** can offer superior lesion detection and characterization in many cases.

A meta-analysis comparing **gadoxetate disodium**-enhanced MRI (EOB-MRI) with ECA-enhanced MRI for the diagnosis of hepatocellular carcinoma (HCC) found that ECA-MRI had a significantly higher per-lesion sensitivity (0.76 vs. 0.63).[9] However, modified EOB-MRI protocols that extend the definition of "washout" to the transitional or hepatobiliary phase showed improved sensitivity.[9] Another study highlighted that for the differentiation of focal nodular hyperplasia (FNH) from hepatocellular adenoma (HCA), the hepatobiliary phase of

**gadoxetate disodium**-enhanced MRI demonstrated high accuracy, with sensitivities for both being 96%.[\[10\]](#)

In a direct comparison for characterizing focal liver lesions, one study found that gadobenate dimeglumine resulted in significantly higher sensitivity (ranging from 91.6% to 99.1% vs. 86.0% to 91.6% for gadoxetate) and specificity (87.5% to 90.5% vs. 79.7% to 83.6% for gadoxetate) for malignant/benign differentiation for two of three readers.[\[11\]](#) Conversely, a phase III clinical trial demonstrated that while the overall increase in sensitivity was comparable between **gadoxetate disodium** and gadobenate dimeglumine, **gadoxetate disodium** showed a significantly higher increase in sensitivity for patients with HCC and HCC with cirrhosis.[\[12\]](#)[\[13\]](#)

Contrast Agent	Lesion Type	Sensitivity	Specificity	Source
Gadoxetate Disodium	Hepatocellular Carcinoma (HCC)	63%	98%	<a href="#">[9]</a>
Extracellular Agents	Hepatocellular Carcinoma (HCC)	76%	96%	<a href="#">[9]</a>
Gadoxetate Disodium	Colorectal Liver Metastasis	93.1%	87.3%	<a href="#">[14]</a>
Gadobenate Dimeglumine	Malignant/Benign Differentiation	91.6% - 99.1%	87.5% - 90.5%	<a href="#">[11]</a>
Gadoxetate Disodium	Malignant/Benign Differentiation	86.0% - 91.6%	79.7% - 83.6%	<a href="#">[11]</a>
Gadoxetate Disodium	Focal Nodular Hyperplasia (FNH)	96%	-	<a href="#">[10]</a>
Gadoxetate Disodium	Hepatocellular Adenoma (HCA)	96%	-	<a href="#">[10]</a>

## Gadoxetate Disodium vs. Superparamagnetic Iron Oxide (SPIO)

SPIO particles are taken up by Kupffer cells in the liver, causing a signal drop in normal liver tissue on T2-weighted images, thereby increasing the conspicuity of lesions.

A study comparing **gadoxetate disodium** with SPIO for the detection of HCC found that **gadoxetate disodium**-enhanced MRI had a significantly higher area under the ROC curve (0.964 vs. 0.830) and sensitivity (90.7% vs. 84.7%).<sup>[15]</sup> In another comparison for the characterization of focal liver lesions, SPIO-enhanced MRI showed higher specificity (99% vs. 85%) and positive predictive value (96% vs. 68%) compared to gadolinium-enhanced MRI.<sup>[16]</sup>

Contrast Agent	Lesion Type	Sensitivity	Specificity	Accuracy	Source
Gadoxetate Disodium	Hepatocellular Carcinoma (HCC)	90.7%	-	-	<sup>[15]</sup>
SPIO	Hepatocellular Carcinoma (HCC)	84.7%	-	-	<sup>[15]</sup>
Gadolinium (Gd)	Focal Liver Lesions	79%	85%	83%	<sup>[16]</sup>
SPIO	Focal Liver Lesions	74%	99%	92%	<sup>[16]</sup>

## Experimental Protocols

A typical MRI protocol for the evaluation of focal liver lesions using **gadoxetate disodium** involves a comprehensive set of sequences performed before and after contrast administration.

**Patient Preparation:** No specific preparation is generally required, but fasting for 4-6 hours prior to the scan can reduce bowel motion artifacts.

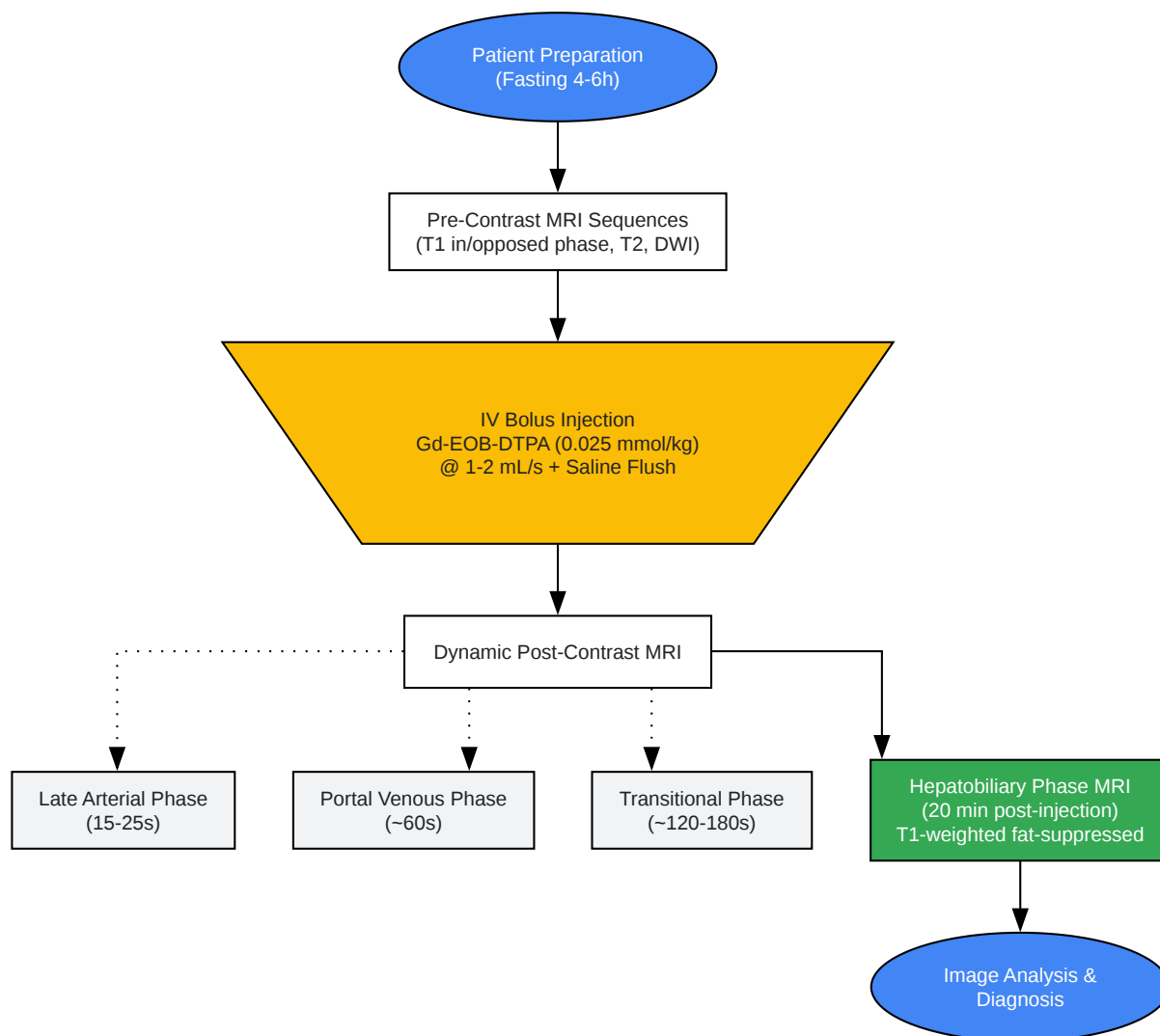
**Contrast Administration:**

- Dosage: 0.025 mmol/kg body weight (equivalent to 0.1 mL/kg).<sup>[6][8]</sup>

- Injection: Administered as an intravenous bolus at a rate of 1-2 mL/second, followed by a saline flush.[6]

#### Imaging Sequences:

- Pre-contrast:
  - T1-weighted in-phase and opposed-phase imaging to detect fat.[17]
  - T2-weighted imaging with fat suppression.[17]
  - Diffusion-weighted imaging (DWI).[17]
- Post-contrast (Dynamic Phases):
  - Late Arterial Phase: Acquired approximately 15-25 seconds post-injection to assess arterial hyperenhancement.[6][17]
  - Portal Venous Phase: Acquired at approximately 60 seconds post-injection.[6][17]
  - Transitional (Equilibrium) Phase: Acquired at approximately 120-180 seconds post-injection.[17]
- Hepatobiliary Phase:
  - Acquired 20 minutes post-injection.[6][17] This can be extended up to 120 minutes if necessary.[6] T1-weighted fat-suppressed sequences are crucial in this phase.



[Click to download full resolution via product page](#)

Typical experimental workflow for **Gadoxetate Disodium**-enhanced liver MRI.

## Conclusion

**Gadoxetate disodium**-enhanced MRI is a powerful tool for the diagnosis and characterization of focal liver lesions. Its unique hepatocyte-specific properties provide valuable information in

the hepatobiliary phase, which can improve diagnostic accuracy, particularly in differentiating certain benign lesions like FNH from malignant ones and in detecting small liver metastases. [18][19] While some studies suggest that ECAs may have higher sensitivity for HCC detection based on traditional criteria, the comprehensive evaluation offered by the dual-phase imaging of **gadoxetate disodium** makes it an indispensable agent in the armamentarium of liver imaging. The choice of contrast agent should be guided by the specific clinical question, lesion characteristics, and institutional expertise.

#### Need Custom Synthesis?

BenchChem offers custom synthesis for rare earth carbides and specific isotopic labeling.

Email: [info@benchchem.com](mailto:info@benchchem.com) or [Request Quote Online](#).

## References

- 1. What is Gadoxetate Disodium used for? [synapse.patsnap.com]
- 2. ajronline.org [ajronline.org]
- 3. Use of gadoxetate disodium for functional MRI based on its unique molecular mechanism - PMC [pmc.ncbi.nlm.nih.gov]
- 4. What is the mechanism of Gadoxetate Disodium? [synapse.patsnap.com]
- 5. discovery.researcher.life [discovery.researcher.life]
- 6. droracle.ai [droracle.ai]
- 7. Gadoxetate Disodium for Contrast Magnetic Resonance Imaging of the Liver - PMC [pmc.ncbi.nlm.nih.gov]
- 8. radiopaedia.org [radiopaedia.org]
- 9. Diagnostic performance of MRI using extracellular contrast agents versus gadoxetic acid for hepatocellular carcinoma: A systematic review and meta-analysis - PubMed [pubmed.ncbi.nlm.nih.gov]
- 10. ajronline.org [ajronline.org]
- 11. Intraindividual crossover comparison of gadobenate dimeglumine-enhanced and gadoxetate disodium-enhanced MRI for characterizing focal liver lesions - PMC [pmc.ncbi.nlm.nih.gov]

- 12. Diagnostic Efficacy and Safety of Gadoxetate Disodium vs Gadobenate Dimeglumine in Patients With Known or Suspected Focal Liver Lesions: Results of a Clinical Phase III Study - PMC [pmc.ncbi.nlm.nih.gov]
- 13. Diagnostic Efficacy and Safety of Gadoxetate Disodium vs Gadobenate Dimeglumine in Patients With Known or Suspected Focal Liver Lesions: Results of a Clinical Phase III Study - PubMed [pubmed.ncbi.nlm.nih.gov]
- 14. Diagnostic performance of CT, gadoxetate disodium-enhanced MRI, and PET/CT for the diagnosis of colorectal liver metastasis: Systematic review and meta-analysis - PubMed [pubmed.ncbi.nlm.nih.gov]
- 15. Comparison of gadoxetic acid-enhanced MRI and superparamagnetic iron oxide-enhanced MRI for the detection of hepatocellular carcinoma - PubMed [pubmed.ncbi.nlm.nih.gov]
- 16. Diagnostic accuracy of MR imaging to identify and characterize focal liver lesions: comparison between gadolinium and superparamagnetic iron oxide contrast media - Maurea - Quantitative Imaging in Medicine and Surgery [qims.amegroups.org]
- 17. droracle.ai [droracle.ai]
- 18. [PDF] Gadoxetate disodium-enhanced MRI of the liver: part 1, protocol optimization and lesion appearance in the noncirrhotic liver. | Semantic Scholar [semanticscholar.org]
- 19. Hepatobiliary contrast agents: differential diagnosis of focal hepatic lesions, pitfalls and other indications - PMC [pmc.ncbi.nlm.nih.gov]
- To cite this document: BenchChem. [Unveiling Liver Lesions: A Comparative Guide to Gadoxetate Disodium in Diagnostic Imaging]. BenchChem, [2025]. [Online PDF]. Available at: [https://www.benchchem.com/product/b1674393#diagnostic-accuracy-of-gadoxetate-disodium-for-focal-liver-lesions]

---

#### Disclaimer & Data Validity:

The information provided in this document is for Research Use Only (RUO) and is strictly not intended for diagnostic or therapeutic procedures. While BenchChem strives to provide accurate protocols, we make no warranties, express or implied, regarding the fitness of this product for every specific experimental setup.

**Technical Support:** The protocols provided are for reference purposes. Unsure if this reagent suits your experiment? [[Contact our Ph.D. Support Team for a compatibility check](#)]

**Need Industrial/Bulk Grade?** [Request Custom Synthesis Quote](#)



# BenchChem

Our mission is to be the trusted global source of essential and advanced chemicals, empowering scientists and researchers to drive progress in science and industry.

## Contact

Address: 3281 E Guasti Rd

Ontario, CA 91761, United States

Phone: (601) 213-4426

Email: [info@benchchem.com](mailto:info@benchchem.com)