

Technical Support Center: Overcoming Challenges in Arterial Phase Imaging with Gadoxetate Disodium

Author: BenchChem Technical Support Team. **Date:** December 2025

Compound of Interest

Compound Name: *Gadoxetate Disodium*

Cat. No.: *B1674393*

[Get Quote](#)

This technical support center provides troubleshooting guidance and frequently asked questions (FAQs) to address common challenges encountered during arterial phase imaging with **Gadoxetate Disodium**. The information is tailored for researchers, scientists, and drug development professionals to optimize their experimental outcomes.

Troubleshooting Guide

This guide addresses specific issues that may arise during arterial phase imaging with **Gadoxetate Disodium**, offering potential causes and actionable solutions.

| Problem | Potential Causes | Solutions |
|---------------------------------------|--|---|
| Weak Arterial Enhancement | <ul style="list-style-type: none"> - Small Administered Volume and Gadolinium Content: Gadoxetate Disodium has a lower gadolinium concentration and is administered in a smaller volume compared to conventional extracellular contrast agents.^[1] - Incorrect Injection Protocol: A fast injection rate can lead to a narrow contrast bolus, making it difficult to capture the optimal arterial phase.^{[1][2]} | <ul style="list-style-type: none"> - Modify Injection Protocol: <ul style="list-style-type: none"> - Slower Injection Rate: An injection rate of 1 mL/sec is often recommended to prolong the contrast bolus.^{[1][2][3]} - Higher Dose: Off-label use of a higher dose (e.g., fixed 10 mL or 20 mL, or 0.05 mmol/kg) may improve peak aortic enhancement, but this is still under debate.^[1] - Dilution: Diluting the contrast agent with saline can increase the injection volume and stretch the contrast bolus.^[2] - Utilize Subtraction Imaging: Subtraction of the unenhanced phase from the arterial phase can enhance the depiction of arterial enhancement.^{[1][4]} |
| Poor Arterial Phase Timing / Mismatch | <ul style="list-style-type: none"> - Narrow Time Window: The contrast bolus from Gadoxetate Disodium is narrower compared to extracellular agents, demanding more precise timing.^{[1][5]} - Use of Fixed Delay: A simple fixed delay for scanning is often inadequate due to individual patient variations.^[1] | <ul style="list-style-type: none"> - Employ Advanced Timing Techniques: <ul style="list-style-type: none"> - Bolus Tracking: This is a recommended method to individually tailor the scan delay.^[1] - Test Bolus: A small test injection can help determine the optimal scan delay for the main contrast injection.^[1] - Optimal Scan Delay: One study suggests an optimal scan delay of 7-12 seconds after peak aortic enhancement with a 1 mL/sec injection rate.^{[1][6]} |

Transient Severe Motion (TSM) Artifacts

- Physiological Response:
TSM is a transient dyspnea or impaired breath-holding ability that can occur in 5-22% of patients after Gadoxetate Disodium injection.[7][8] The exact mechanism is not fully understood.[7]

- Patient Screening and Management: - Identify High-Risk Patients: Risk factors include a previous TSM episode, allergy to iodinated contrast, low body weight, and COPD.[1][9] Consider using a conventional contrast agent for these patients.[1] - Oxygen Inhalation: Administering oxygen may improve image quality in patients with a prior history of TSM.[10] - Modify Injection Protocol: - Slower Injection Rate: A rate of 1 mL/sec may help.[9] - Dilution: Diluting the contrast agent may also mitigate TSM.[11] - Advanced Imaging Sequences: - Multiple Arterial Phase Acquisitions: This technique can help to acquire at least one motion-free arterial phase.[1][5][9][12] - Motion-Resistant Sequences: Utilize sequences that are less susceptible to motion artifacts.[1]

Frequently Asked Questions (FAQs)

Q1: Why is arterial phase imaging more challenging with **Gadoxetate Disodium** compared to other contrast agents?

A1: The primary challenges stem from the unique properties of **Gadoxetate Disodium**. It is administered at a lower dose (0.025 mmol/kg) and has a smaller gadolinium content compared to standard extracellular agents.[1][2] This results in a smaller and more transient contrast

bolus, making the timing of the arterial phase critical and arterial enhancement potentially weaker.[\[1\]](#)[\[5\]](#) Additionally, a phenomenon known as Transient Severe Motion (TSM), or transient dyspnea, can occur in a subset of patients, leading to significant motion artifacts during the arterial phase.[\[1\]](#)[\[7\]](#)[\[9\]](#)

Q2: What is Transient Severe Motion (TSM) and what are its risk factors?

A2: TSM is a temporary difficulty in holding one's breath that occurs shortly after the injection of **Gadoxetate Disodium**, leading to motion artifacts in the arterial phase images.[\[7\]](#)[\[8\]](#) The incidence is reported to be between 5% and 22%.[\[7\]](#) While the exact cause is not fully understood, identified risk factors include a history of a previous TSM episode, high-volume injection of gadoxetate, low body weight, a history of allergy to iodinated contrast media, and chronic obstructive pulmonary disease (COPD).[\[1\]](#)[\[9\]](#)

Q3: What are the recommended injection protocols to optimize arterial phase imaging?

A3: To compensate for the small contrast volume, a slower injection rate of 1 mL/s is often recommended to broaden the peak enhancement window.[\[1\]](#)[\[2\]](#) Some studies have explored off-label higher doses or fixed volumes (e.g., 10 mL or 20 mL) to increase arterial enhancement, though this is not standard practice.[\[1\]](#) Diluting the contrast agent with an equal volume of saline and injecting at 2 mL/s has also been shown to reduce artifacts compared to a slow injection of undiluted contrast.[\[11\]](#)

Q4: How can I ensure accurate timing of the arterial phase?

A4: Due to the narrow time window for optimal arterial phase imaging with **Gadoxetate Disodium**, a simple fixed delay is not recommended.[\[1\]](#) More sophisticated methods like bolus tracking or a test bolus are preferred to individualize the scan timing.[\[1\]](#) Research suggests that the optimal scan delay for hypervascular liver lesions is approximately 7-12 seconds after the peak aortic enhancement when using a slow injection protocol of 1 mL/s.[\[1\]](#)[\[6\]](#)

Q5: Are there any imaging techniques that can help mitigate the effects of TSM?

A5: Yes, several imaging strategies can be employed. Acquiring multiple arterial phases, sometimes with a higher temporal resolution, increases the probability of obtaining at least one diagnostic quality, motion-free image.[\[1\]](#)[\[5\]](#)[\[9\]](#) The use of motion-resistant or free-breathing imaging sequences can also be beneficial.[\[7\]](#) Furthermore, subtraction imaging, where the pre-

contrast images are subtracted from the arterial phase images, can improve the conspicuity of enhancing lesions.^{[1][4]}

Experimental Protocols

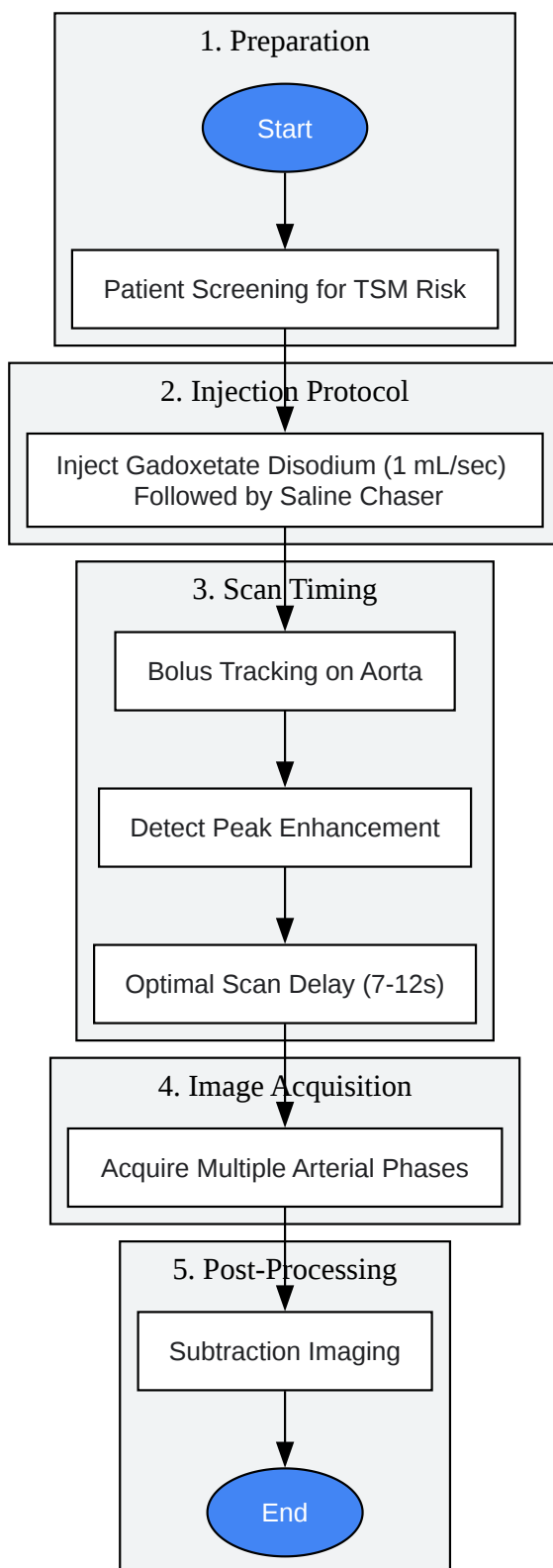
Optimized Injection and Imaging Protocol for Arterial Phase

This protocol is a synthesis of recommendations to enhance arterial phase quality and minimize artifacts.

- Patient Preparation and Screening:
 - Screen for risk factors for TSM (e.g., prior TSM, COPD, contrast allergies).^{[1][9]}
 - For high-risk patients, consider alternative contrast agents or implement mitigation strategies like oxygen administration.^{[1][10]}
- Contrast Administration:
 - Agent: **Gadoxetate Disodium** (0.25 mmol/mL).^[13]
 - Dosage: Standard 0.025 mmol/kg body weight.^{[2][13]}
 - Injection Rate: 1 mL/sec.^{[1][2]}
 - Saline Chaser: Follow the contrast injection with a 20 mL saline flush at the same injection rate.^[14]
- Arterial Phase Timing:
 - Method: Utilize a bolus tracking technique with the region of interest (ROI) placed in the abdominal aorta.^[1]
 - Scan Delay: Initiate the arterial phase acquisition 7-12 seconds after the detection of peak enhancement in the aorta.^{[1][6]}
- Image Acquisition:

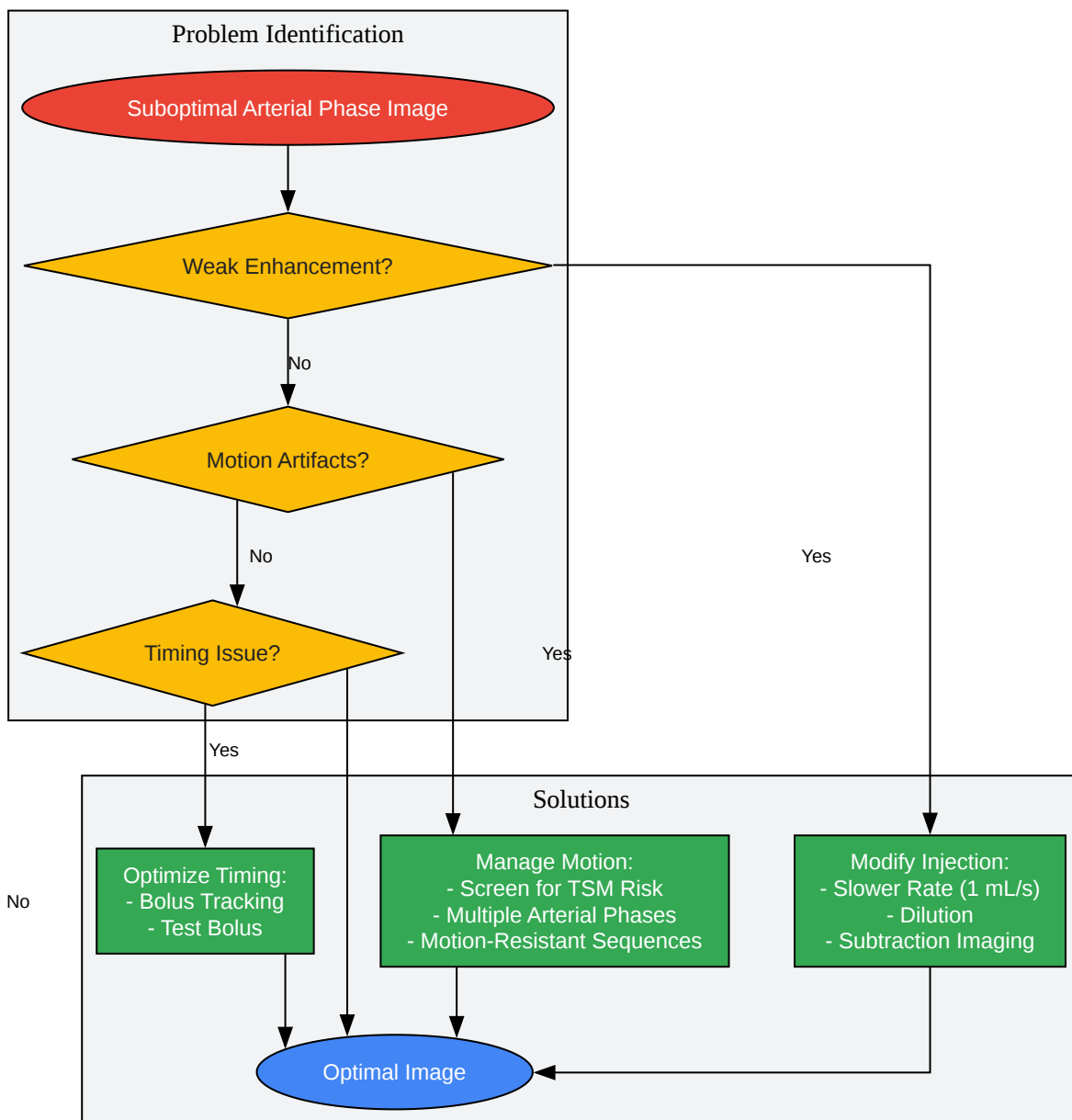
- Sequence: 3D T1-weighted gradient-echo sequence with fat suppression.[2]
- Strategy for TSM: Consider acquiring multiple arterial phases to increase the likelihood of a motion-free scan.[5][12]
- Post-Processing:
 - Perform digital subtraction of the unenhanced T1-weighted images from the arterial phase images to improve the visualization of arterial enhancement.[1][4]

Visualizations



[Click to download full resolution via product page](#)

Caption: Optimized workflow for arterial phase imaging with **Gadoxetate Disodium**.



[Click to download full resolution via product page](#)

Caption: Troubleshooting decision tree for suboptimal arterial phase imaging.

Need Custom Synthesis?

BenchChem offers custom synthesis for rare earth carbides and specific isotopic labeling.

Email: info@benchchem.com or [Request Quote Online](#).

References

- 1. Troubleshooting Arterial-Phase MR Images of Gadoxetate Disodium-Enhanced Liver - PMC [pmc.ncbi.nlm.nih.gov]
- 2. geiselmed.dartmouth.edu [geiselmed.dartmouth.edu]
- 3. Evaluation of transient respiratory motion artifact at gadoxetate disodium-enhanced MRI—Influence of different contrast agent application protocols | PLOS One [journals.plos.org]
- 4. Gadoxetate-Enhanced MRI as a Diagnostic Tool in the Management of Hepatocellular Carcinoma: Report from a 2020 Asia-Pacific Multidisciplinary Expert Meeting - PMC [pmc.ncbi.nlm.nih.gov]
- 5. Triple Arterial Phase MR Imaging with Gadoxetic Acid Using a Combination of Contrast Enhanced Time Robust Angiography, Keyhole, and Viewsharing Techniques and Two-Dimensional Parallel Imaging in Comparison with Conventional Single Arterial Phase - PMC [pmc.ncbi.nlm.nih.gov]
- 6. ajronline.org [ajronline.org]
- 7. Transient Severe Respiratory Motion Artifacts After Application of Gadoxetate Disodium: What We Currently Know - PubMed [pubmed.ncbi.nlm.nih.gov]
- 8. thieme-connect.com [thieme-connect.com]
- 9. radiopaedia.org [radiopaedia.org]
- 10. Reducing artifacts of gadoxetate disodium-enhanced MRI with oxygen inhalation in patients with prior episode of arterial phase motion: intra-individual comparison - PubMed [pubmed.ncbi.nlm.nih.gov]
- 11. researchgate.net [researchgate.net]
- 12. Evaluation of late arterial acquisition and image quality after gadoxetate disodium injection using the CDT-VIBE sequence - PMC [pmc.ncbi.nlm.nih.gov]
- 13. radiopaedia.org [radiopaedia.org]
- 14. Optimal Timing and Diagnostic Adequacy of Hepatocyte Phase Imaging with Gadoxetate-Enhanced Liver MRI - PMC [pmc.ncbi.nlm.nih.gov]

- To cite this document: BenchChem. [Technical Support Center: Overcoming Challenges in Arterial Phase Imaging with Gadoxetate Disodium]. BenchChem, [2025]. [Online PDF]. Available at: [<https://www.benchchem.com/product/b1674393#overcoming-challenges-in-arterial-phase-imaging-with-gadoxetate-disodium>]

Disclaimer & Data Validity:

The information provided in this document is for Research Use Only (RUO) and is strictly not intended for diagnostic or therapeutic procedures. While BenchChem strives to provide accurate protocols, we make no warranties, express or implied, regarding the fitness of this product for every specific experimental setup.

Technical Support: The protocols provided are for reference purposes. Unsure if this reagent suits your experiment? [[Contact our Ph.D. Support Team for a compatibility check](#)]

Need Industrial/Bulk Grade? [Request Custom Synthesis Quote](#)

BenchChem

Our mission is to be the trusted global source of essential and advanced chemicals, empowering scientists and researchers to drive progress in science and industry.

Contact

Address: 3281 E Guasti Rd
Ontario, CA 91761, United States
Phone: (601) 213-4426
Email: info@benchchem.com