

Technical Support Center: Deep Infiltrating Endometriosis Diagnosis via Transvaginal Sonography

Author: BenchChem Technical Support Team. **Date:** December 2025

Compound of Interest

Compound Name: FR 76830

Cat. No.: B1674034

[Get Quote](#)

This technical support center provides troubleshooting guides and frequently asked questions (FAQs) for researchers, scientists, and drug development professionals utilizing transvaginal sonography (TVS) for the diagnosis of deep infiltrating endometriosis (DIE).

Troubleshooting Guides

Issue: Difficulty Visualizing Posterior Compartment Structures

- Problem: Inadequate visualization of the uterosacral ligaments, rectovaginal septum, or rectosigmoid colon.
- Possible Causes:
 - Bowel Gas: Gas in the rectum or sigmoid colon can cause acoustic shadowing, obscuring underlying structures.
 - Inadequate Probe Pressure: Insufficient pressure with the transvaginal probe may not displace bowel loops effectively.
 - Patient Discomfort: Patient pain or tension can limit the examiner's ability to manipulate the probe for optimal views.

- Retroverted Uterus: A severely retroverted uterus can physically obstruct the view of the posterior compartment.
- Solutions:
 - Gentle Probe Pressure: Apply firm but gentle pressure on the posterior vaginal fornix to displace bowel and bring the probe closer to the structures of interest.
 - Patient Positioning: Consider placing a cushion under the patient's buttocks to tilt the pelvis, which may improve visualization.
 - Bowel Preparation: While not always mandatory, a mild bowel preparation may be considered in select cases to reduce gas and fecal matter. However, studies have shown no significant improvement in diagnostic accuracy with bowel preparation.[1]
 - "Sliding Sign" Assessment: Evaluate the mobility between the posterior uterine wall and the anterior rectal wall. A negative "sliding sign" (lack of movement) is a soft marker for adhesions and potential DIE in the posterior compartment.[2][3]

Issue: Suspected Bladder Endometriosis Not Visualized

- Problem: Clinical suspicion of bladder DIE, but no visible lesions on TVS.
- Possible Causes:
 - Over or Under-distended Bladder: An empty bladder makes the walls difficult to assess, while an overly full bladder can compress small nodules and hinder transvaginal views.[4]
 - Small Lesion Size: Small endometriotic nodules may not be readily apparent on ultrasound.[5][6]
 - Lesion Location: Lesions located at the dome of the bladder can be missed by the transvaginal approach.
- Solutions:
 - Optimal Bladder Filling: The patient should have a partially full bladder. This provides an acoustic window without overly distending the organ.

- Transabdominal Scan: If bladder involvement is strongly suspected, a complementary transabdominal scan with a full bladder may be beneficial.
- "Tenderness-Guided" Approach: Pay close attention to areas of patient-reported tenderness during the examination, as this can guide the sonographer to potential small lesions.[\[2\]](#)

Frequently Asked Questions (FAQs)

Q1: What are the primary limitations of transvaginal sonography in diagnosing deep infiltrating endometriosis?

A1: The main limitations of TVS in diagnosing DIE include:

- Operator Dependence: The accuracy of the examination is highly dependent on the skill and experience of the operator.[\[6\]](#)[\[7\]](#)
- Location-Specific Accuracy: TVS has varying accuracy depending on the anatomical location of the DIE lesions. It is generally more accurate for lesions in the rectosigmoid and bladder but less so for the uterosacral ligaments, vagina, and rectovaginal septum.[\[8\]](#)[\[9\]](#)
- Limited Field-of-View: TVS is not suitable for diagnosing lesions located high in the pelvis, such as the upper rectosigmoid, or for detecting extra-pelvic endometriosis.[\[9\]](#)
- Small Lesions: Small endometriotic nodules can be challenging to visualize and may be missed.[\[6\]](#)

Q2: How does the diagnostic accuracy of TVS for DIE vary by pelvic compartment?

A2: The diagnostic accuracy of TVS for DIE is not uniform across all pelvic locations. Generally, it demonstrates high accuracy for rectosigmoid and bladder endometriosis. However, its sensitivity can be lower for lesions involving the uterosacral ligaments, vagina, and rectovaginal septum. For parametrial involvement, TVS shows high specificity but low sensitivity.[\[8\]](#)[\[9\]](#)[\[10\]](#)

Q3: Is bowel preparation necessary before a TVS for suspected DIE?

A3: While poor bowel preparation can theoretically limit ultrasound wave penetration, studies have generally not found a significant improvement in the sensitivity, specificity, or accuracy of

TVS for DIE when bowel preparation is used.[1][11] Therefore, it is not considered a mandatory step in the standard protocol.

Q4: What is the "sliding sign" and why is it important in the assessment of DIE?

A4: The "sliding sign" is a dynamic assessment of organ mobility during a TVS examination.[2][3] It is used to evaluate for adhesions between the uterus and the rectum (posterior compartment) and the uterus and the bladder (anterior compartment). A negative sliding sign, indicating that the organs are not moving freely against each other, suggests the presence of adhesions, which can be a marker for DIE.

Q5: When should an alternative imaging modality, such as MRI, be considered?

A5: Magnetic Resonance Imaging (MRI) should be considered in the following scenarios:

- When there is a strong clinical suspicion of DIE, but the TVS examination is negative.[9]
- For the assessment of multifocal bowel lesions or lesions located high in the rectosigmoid colon, which are beyond the field of view of TVS.[9]
- In centers where there is a lack of expertise in performing specialized TVS for endometriosis.[9]
- For a more comprehensive preoperative mapping of the extent of the disease.

Data Presentation

Table 1: Diagnostic Accuracy of Transvaginal Sonography for Deep Infiltrating Endometriosis by Anatomical Location

Anatomical Location	Sensitivity (%)	Specificity (%)
Posterior Compartment		
Rectosigmoid	85 - 87.2	96 - 96.8
Uterosacral Ligaments	23 - 70.9	86 - 95.9
Rectovaginal Septum	28.6 - 59	89 - 99.3
Pouch of Douglas	72 - 92	83 - 100
Anterior Compartment		
Bladder	66.7 - 71.4	100
Other Locations		
Vagina	29.4 - 50	97.2 - 100
Parametrium	31	98

Data compiled from multiple sources. Ranges reflect variability across different studies.[\[8\]](#)[\[10\]](#)[\[12\]](#)[\[13\]](#)[\[14\]](#)

Experimental Protocols

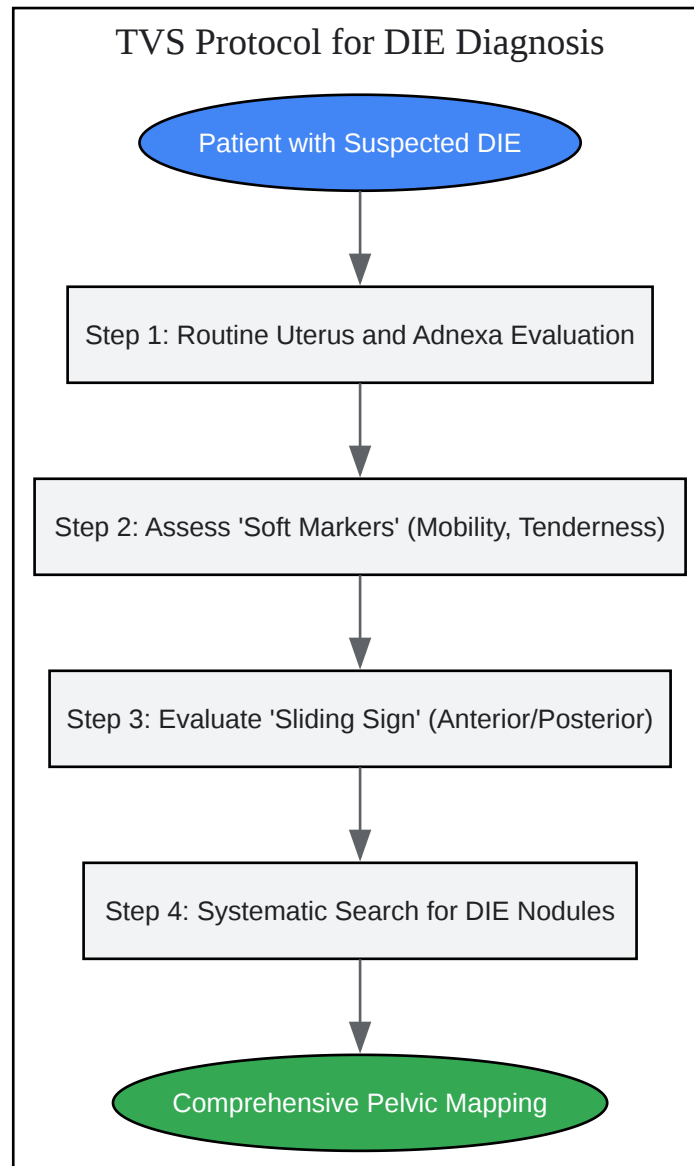
Protocol: Systematic Transvaginal Sonography for the Assessment of Deep Infiltrating Endometriosis (Based on IDEA Consensus)

This protocol outlines a standardized approach to TVS for the diagnosis of DIE, as recommended by the International Deep Endometriosis Analysis (IDEA) group.[\[4\]](#)[\[5\]](#)

- Step 1: Routine Evaluation of Uterus and Adnexa:
 - Perform a standard transvaginal ultrasound to assess the uterus for any abnormalities, such as adenomyosis, and to examine the ovaries for endometriomas. Note the uterine position (anteverted, retroverted).
- Step 2: Assessment of "Soft Markers":

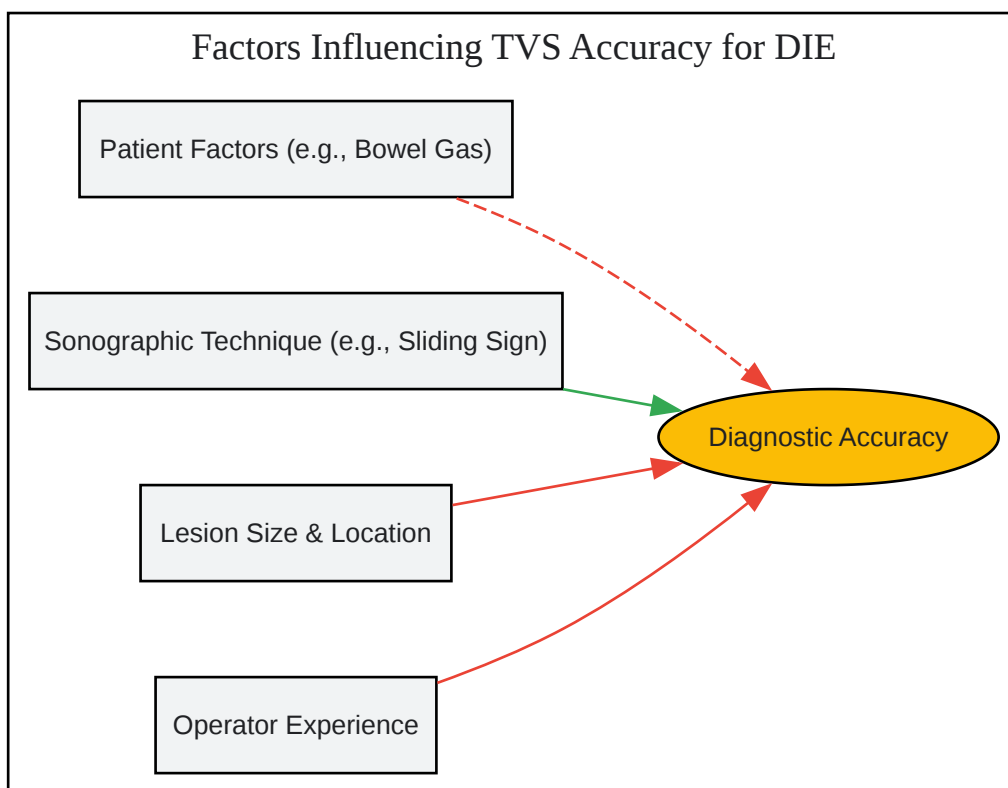
- Ovarian Mobility: Gently apply pressure with the transvaginal probe and the free hand on the abdomen to assess if the ovaries are mobile or fixed to surrounding structures.
- Site-Specific Tenderness: Note any areas of tenderness elicited by the ultrasound probe, as this can indicate the location of endometriotic nodules.
- Step 3: Assessment of the "Sliding Sign":
 - Posterior Compartment: Place the transducer in the posterior vaginal fornix and observe for the sliding motion between the anterior rectal wall and the posterior cervix/uterus. A lack of movement suggests obliteration of the pouch of Douglas.
 - Anterior Compartment: With the transducer in the anterior fornix, assess the movement between the uterus and the posterior wall of the bladder.
- Step 4: Assessment of Anterior and Posterior Compartments for DIE Nodules:
 - Posterior Compartment:
 - Uterosacral Ligaments (USLs): Scan laterally from the cervix to visualize the USLs, looking for hypoechoic nodules or thickening.
 - Vaginal Fornix: Examine the posterior vaginal wall for any nodules.
 - Rectovaginal Septum: Assess the area between the posterior vaginal wall and the anterior rectal wall.
 - Rectosigmoid Colon: Systematically examine the anterior and posterior walls of the rectum and sigmoid colon, looking for hypoechoic nodules with or without muscularis propria involvement.
 - Anterior Compartment:
 - Bladder: With a partially filled bladder, carefully examine the bladder wall, particularly the base and dome, for any nodules.
 - Vesicouterine Pouch: Assess the potential space between the bladder and the uterus.

Visualizations



[Click to download full resolution via product page](#)

Caption: Standardized workflow for transvaginal sonography in diagnosing deep infiltrating endometriosis.



[Click to download full resolution via product page](#)

Caption: Key factors influencing the diagnostic accuracy of transvaginal sonography for deep infiltrating endometriosis.

Need Custom Synthesis?

BenchChem offers custom synthesis for rare earth carbides and specific isotopic labeling.

Email: info@benchchem.com or [Request Quote Online](#).

References

- 1. Current Status of Transvaginal Ultrasound Accuracy in the Diagnosis of Deep Infiltrating Endometriosis | EndoNews [endonews.com]
- 2. pubs.rsna.org [pubs.rsna.org]
- 3. Diagnosis of Deep Infiltrating Endometriosis Using Transvaginal Ultrasonography - PMC [pmc.ncbi.nlm.nih.gov]

- 4. radiopaedia.org [radiopaedia.org]
- 5. Transvaginal ultrasound in deep endometriosis: pictorial essay - PMC [pmc.ncbi.nlm.nih.gov]
- 6. Preoperative ultrasound diagnosis of deep endometriosis: importance of the examiner's expertise and lesion size - PMC [pmc.ncbi.nlm.nih.gov]
- 7. Ultrasound diagnosis of endometriosis: One Size Does-Not-Fit-All | EndoNews [endonews.com]
- 8. Diagnostic accuracy of transvaginal sonography for deep pelvic endometriosis - PubMed [pubmed.ncbi.nlm.nih.gov]
- 9. Transvaginal Ultrasound in the Diagnosis and Assessment of Endometriosis—An Overview: How, Why, and When - PMC [pmc.ncbi.nlm.nih.gov]
- 10. Diagnostic accuracy of transvaginal sonography for detecting parametrial involvement in women with deep endometriosis: systematic review and meta-analysis - PMC [pmc.ncbi.nlm.nih.gov]
- 11. Assessing The Role and Accuracy of Ultrasonographic Imaging in The Diagnosis of Deep Infiltrating Endometriosis: A Cross-Sectional Study - PMC [pmc.ncbi.nlm.nih.gov]
- 12. static1.squarespace.com [static1.squarespace.com]
- 13. researchgate.net [researchgate.net]
- 14. Frontiers | Diagnosis of Deep Infiltrating Endometriosis Using Transvaginal Ultrasonography [frontiersin.org]
- To cite this document: BenchChem. [Technical Support Center: Deep Infiltrating Endometriosis Diagnosis via Transvaginal Sonography]. BenchChem, [2025]. [Online PDF]. Available at: [https://www.benchchem.com/product/b1674034#limitations-of-transvaginal-sonography-in-diagnosing-deep-infiltrating-endometriosis]

Disclaimer & Data Validity:

The information provided in this document is for Research Use Only (RUO) and is strictly not intended for diagnostic or therapeutic procedures. While BenchChem strives to provide accurate protocols, we make no warranties, express or implied, regarding the fitness of this product for every specific experimental setup.

Technical Support: The protocols provided are for reference purposes. Unsure if this reagent suits your experiment? [[Contact our Ph.D. Support Team for a compatibility check](#)]

Need Industrial/Bulk Grade? [Request Custom Synthesis Quote](#)

BenchChem

Our mission is to be the trusted global source of essential and advanced chemicals, empowering scientists and researchers to drive progress in science and industry.

Contact

Address: 3281 E Guasti Rd
Ontario, CA 91761, United States
Phone: (601) 213-4426
Email: info@benchchem.com