

# Non-Invasive Fertility Potential Evaluation: An In-depth Technical Guide Using Ultrasonography

**Author:** BenchChem Technical Support Team. **Date:** December 2025

## Compound of Interest

Compound Name: FR 76830

Cat. No.: B1674034

[Get Quote](#)

For Researchers, Scientists, and Drug Development Professionals

This technical guide provides a comprehensive overview of the principles and applications of non-invasive ultrasonography in the evaluation of female fertility potential. It is designed to equip researchers, scientists, and professionals in drug development with the knowledge to effectively utilize ultrasound technology in their respective fields. This document details the experimental protocols for key ultrasonographic techniques, presents quantitative data for the assessment of fertility markers, and illustrates the underlying biological signaling pathways.

## Ovarian Reserve Assessment

Ovarian reserve, a cornerstone of female fertility, refers to the quantity and quality of oocytes. Its non-invasive assessment is crucial for predicting reproductive potential and guiding fertility treatments.

### Antral Follicle Count (AFC)

The Antral Follicle Count (AFC) is a fundamental ultrasound marker for ovarian reserve, reflecting the primordial follicle pool.<sup>[1]</sup> Antral follicles are small, fluid-filled sacs within the ovaries, each containing an immature egg that has the potential to mature.<sup>[1][2]</sup>

#### 1.1.1 Experimental Protocol: Transvaginal Ultrasound for Antral Follicle Count

This protocol outlines the standardized procedure for performing a transvaginal ultrasound to determine the Antral Follicle Count.

### I. Patient Preparation:

- Schedule the examination during the early follicular phase of the menstrual cycle (typically days 2, 3, or 4), as this is when the antral follicles are most visible and have not yet been stimulated by natural hormones.[1][3]
- Instruct the patient to empty their bladder immediately before the procedure to ensure optimal visualization of the pelvic organs.

### II. Equipment and Settings:

- Utilize a high-frequency transvaginal ultrasound transducer (minimum 7 MHz) for clear visualization of small follicles.[4]
- Optimize the ultrasound settings (e.g., gain, focus, and depth) to achieve a clear and high-contrast image of the ovarian parenchyma.

### III. Scanning Procedure:

- Gently insert the lubricated transvaginal probe into the vagina.
- Systematically scan both ovaries in both the longitudinal and sagittal planes.
- Identify and count all antral follicles measuring 2-10 mm in diameter in both ovaries.[2][5] A meticulous approach should be taken to avoid double-counting or missing follicles.
- Record the number of follicles for each ovary separately and then calculate the total AFC.

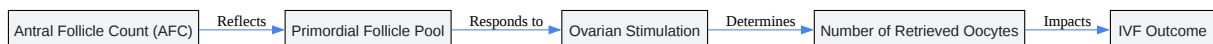
#### 1.1.2 Data Presentation: Antral Follicle Count and IVF Outcomes

The AFC is a strong predictor of ovarian response to stimulation and IVF success. The following table summarizes the correlation between AFC and IVF outcomes based on a comprehensive review of clinical data.

Antral Follicle Count (AFC)	Ovarian Reserve Classification	Predicted Ovarian Response	Associated IVF Outcomes
< 5	Very Low	Poor response to stimulation	Lower chance of IVF success, higher cycle cancellation rates.[6]
5 - 9	Low	Suboptimal or poor response	Reduced number of oocytes retrieved.[2]
10 - 20	Normal	Adequate response	Good prognosis for IVF success.[2]
> 20	High	High response	Increased risk of Ovarian Hyperstimulation Syndrome (OHSS).[6]

### 1.1.3 Logical Relationship: AFC and Ovarian Response

The number of antral follicles directly reflects the pool of primordial follicles that can be recruited and stimulated during an IVF cycle. A higher AFC generally indicates a greater number of oocytes that can be retrieved, thus increasing the chances of obtaining viable embryos for transfer.



[Click to download full resolution via product page](#)

Caption: Logical workflow from AFC to IVF outcome.

## Ovarian Volume

Three-dimensional (3D) ultrasound allows for a more accurate and reproducible measurement of ovarian volume compared to 2D methods. Ovarian volume can be an indicator of ovarian reserve, although it is considered a less reliable predictor than AFC.

### 1.2.1 Experimental Protocol: 3D Ultrasound for Ovarian Volume Measurement

This protocol details the acquisition and analysis of 3D ultrasound data for ovarian volume assessment.

#### I. Patient Preparation:

- Similar to AFC, the examination is ideally performed in the early follicular phase.
- The patient should have an empty bladder.

#### II. Equipment and Settings:

- Utilize a 3D-capable transvaginal ultrasound transducer.
- Optimize the 2D image of the ovary in a longitudinal plane, ensuring the entire ovary is visible.

#### III. 3D Volume Acquisition:

- Activate the 3D acquisition mode.
- Define the region of interest (ROI) to encompass the entire ovary.
- Initiate the automated volume sweep. The transducer will automatically acquire a series of 2D images.

#### IV. Volume Analysis:

- Once the 3D volume is acquired, use the machine's built-in software for analysis.
- Manually or semi-automatically trace the contour of the ovary on sequential planes to calculate the volume.
- The software will then automatically calculate the ovarian volume in cubic centimeters (cm<sup>3</sup>).

## Uterine Receptivity Assessment

Endometrial receptivity is the window of time when the uterine lining is receptive to embryo implantation. Ultrasound provides valuable insights into the morphological and physiological characteristics of the endometrium.

## Endometrial Thickness and Pattern

Endometrial thickness and its sonographic pattern are key indicators of uterine receptivity. A trilaminar, or "triple-line," pattern is considered optimal for implantation.<sup>[7]</sup>

### 2.1.1 Experimental Protocol: Transvaginal Ultrasound for Endometrial Assessment

This protocol describes the standardized method for measuring endometrial thickness and evaluating its pattern.

#### I. Patient Preparation:

- The timing of the scan is critical and is typically performed on the day of human chorionic gonadotropin (hCG) administration in IVF cycles.<sup>[8]</sup>
- The patient should have an empty bladder.

#### II. Equipment and Settings:

- Use a high-frequency transvaginal ultrasound transducer.
- Obtain a clear sagittal view of the uterus.

#### III. Measurement and Evaluation:

- Measure the endometrial thickness at its thickest point, from the anterior to the posterior myometrial-endometrial interface.
- Characterize the endometrial pattern as one of the following:
  - Pattern A (Trilaminar): A triple-line pattern with a central hyperechoic line and two outer hypoechoic layers. This is considered the most favorable pattern for implantation.<sup>[9]</sup>

- Pattern B (Isoechogenic): An intermediate pattern with the same echogenicity as the myometrium and a poorly defined central line.[9]
- Pattern C (Hyperechogenic): A uniformly bright endometrium.[9]

### 2.1.2 Data Presentation: Endometrial Thickness and IVF Outcomes

The following table summarizes the relationship between endometrial thickness on the day of hCG administration and clinical pregnancy rates in IVF cycles.

Endometrial Thickness	Clinical Pregnancy Rate	Implantation Rate
≤ 7 mm	Significantly Lower[10]	Significantly Lower[10]
> 7 mm to ≤ 14 mm	Higher[8]	Higher[8]
> 14 mm	Highest[10]	Highest[10]

Note: While a thicker endometrium is generally associated with better outcomes, excessively thick endometrium may not always be favorable.

## Uterine and Ovarian Blood Flow (Doppler Ultrasonography)

Doppler ultrasonography is a non-invasive technique used to assess blood flow in the uterine and ovarian arteries, providing functional information about uterine receptivity and ovarian response.[11]

### 2.2.1 Experimental Protocol: Transvaginal Doppler of Uterine and Ovarian Arteries

This protocol details the procedure for performing Doppler velocimetry of the uterine and ovarian arteries.

#### I. Patient Preparation:

- The examination can be performed at various points in the menstrual cycle, but for predicting IVF outcomes, it is often done on the day of hCG administration or embryo transfer.

- The patient should have an empty bladder.

## II. Equipment and Settings:

- Utilize a transvaginal ultrasound transducer with color and pulsed-wave Doppler capabilities.
- Set the color Doppler gain to a level that visualizes blood flow without excessive noise.
- The pulsed-wave Doppler gate should be set to 2 mm.
- The angle of insonation should be kept below 50 degrees to ensure accurate velocity measurements.[\[12\]](#)

## III. Scanning Procedure:

- Uterine Arteries:
  - Obtain a sagittal view of the uterus and cervix.
  - Move the probe laterally to identify the uterine artery at the level of the internal cervical os.
  - Place the pulsed-wave Doppler gate over the vessel and obtain at least three consecutive, stable waveforms.
  - Measure the Pulsatility Index (PI) and Resistance Index (RI).
- Ovarian Stromal Blood Flow:
  - Visualize the ovary in a longitudinal or transverse plane.
  - Activate the power Doppler mode to identify blood flow within the ovarian stroma.
  - Place the pulsed-wave Doppler gate within a stromal vessel and obtain at least three stable waveforms.
  - Measure the Peak Systolic Velocity (PSV).

### 2.2.2 Data Presentation: Doppler Indices and Pregnancy Outcomes

Lower impedance (lower PI and RI) in the uterine arteries is generally associated with better uterine perfusion and higher pregnancy rates.

Doppler Parameter	Association with Clinical Pregnancy
Uterine Artery Pulsatility Index (PI)	A lower mean PI is associated with a higher clinical pregnancy rate in ART cycles. <a href="#">[13]</a>
Uterine Artery Resistance Index (RI)	A lower RI is generally indicative of better uterine perfusion.
Ovarian Stromal Peak Systolic Velocity (PSV)	Higher PSV (e.g., $\geq 10$ cm/s) after pituitary suppression has been associated with a better ovarian response and higher clinical pregnancy rates. <a href="#">[14]</a>

## Uterine Cavity and Fallopian Tube Assessment

Structural abnormalities of the uterus and fallopian tubes can significantly impact fertility. Sonohysterography is a specialized ultrasound technique for detailed evaluation of the uterine cavity and fallopian tube patency.

### Sonohysterography (Saline Infusion Sonography - SIS)

SIS involves instilling sterile saline into the uterine cavity to provide a clear view of the endometrial lining and detect abnormalities such as polyps, fibroids, and adhesions.[\[15\]](#)

#### 3.1.1 Experimental Protocol: Sonohysterography

This protocol outlines the steps for performing a sonohysterography procedure.

##### I. Patient Preparation:

- Schedule the procedure in the early follicular phase (days 4-7) after menstruation has ceased, when the endometrium is thin.[\[8\]](#)
- Ensure the patient is not pregnant and has no active pelvic infection.
- The patient should empty her bladder.



## II. Equipment and Procedure:

- Perform a baseline transvaginal ultrasound to assess the uterus and ovaries.
- Insert a sterile speculum into the vagina to visualize the cervix.
- Cleanse the cervix with an antiseptic solution.
- Insert a thin, flexible catheter through the cervix into the uterine cavity.
- Inflate the balloon at the catheter tip with 1-2 mL of sterile saline to secure it in place.[\[16\]](#)
- Remove the speculum and re-insert the transvaginal ultrasound probe.
- Slowly instill 5-30 mL of warm, sterile saline into the uterine cavity while performing real-time ultrasound imaging.[\[8\]](#)
- Systematically evaluate the entire uterine cavity in both sagittal and coronal planes.
- For tubal patency assessment, a mixture of saline and air can be injected, and the passage of microbubbles through the fallopian tubes is observed.

## Signaling Pathways in Fertility

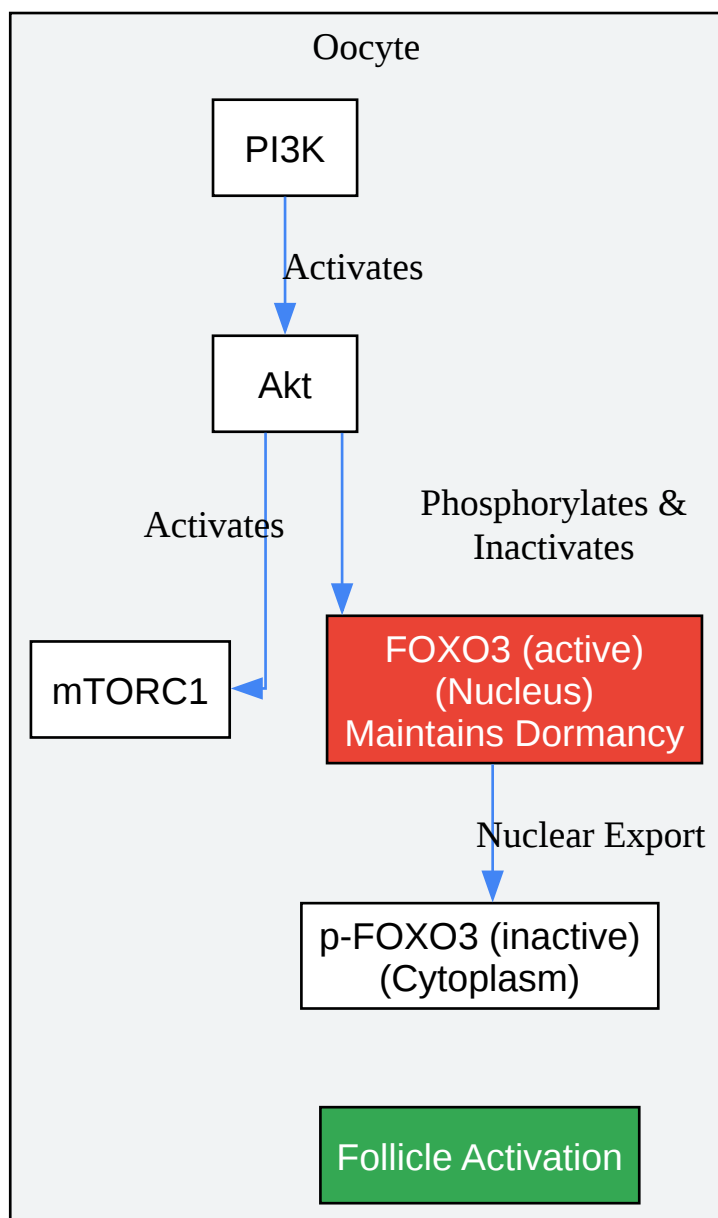
Understanding the molecular signaling pathways that govern follicular development and endometrial receptivity is crucial for developing novel therapeutic strategies.

### Signaling Pathways in Ovarian Follicle Development

Several key signaling pathways orchestrate the complex process of follicular development, from primordial follicle activation to ovulation.

#### 4.1.1 PI3K/Akt/mTOR Pathway in Primordial Follicle Activation

The PI3K/Akt/mTOR pathway is a central regulator of primordial follicle activation. Activation of this pathway in the oocyte leads to the phosphorylation and nuclear export of the transcription factor FOXO3, which in its active nuclear form, maintains follicular dormancy.[\[13\]](#)[\[17\]](#)

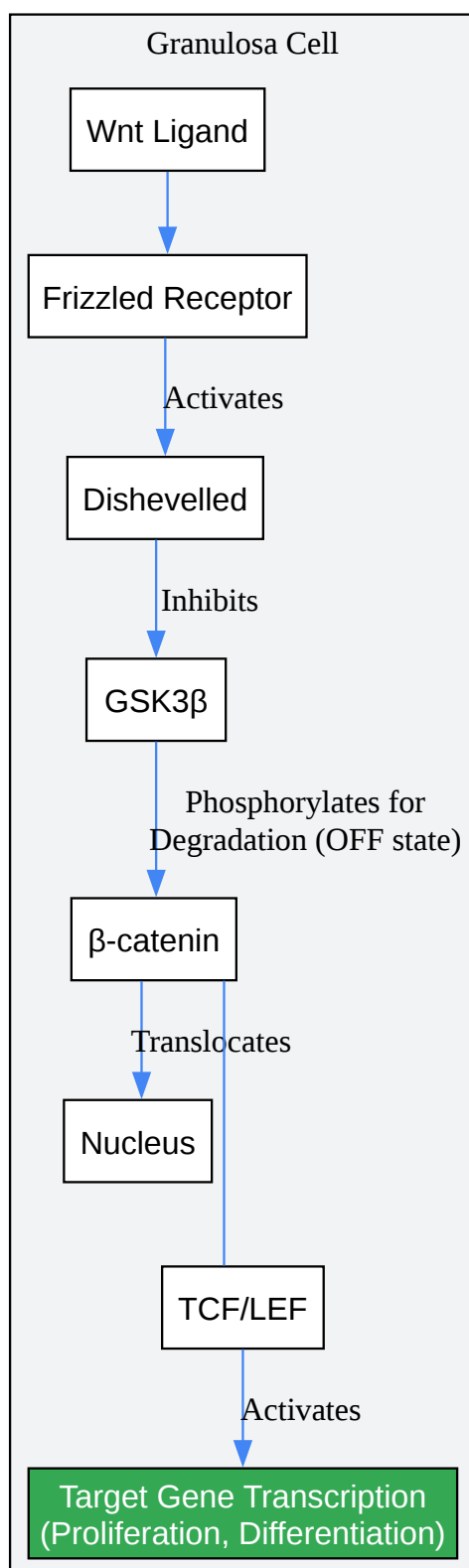


[Click to download full resolution via product page](#)

Caption: PI3K/Akt/mTOR pathway in oocyte activation.

#### 4.1.2 Wnt/ $\beta$ -catenin Signaling in Granulosa Cells

Wnt signaling plays a critical role in granulosa cell proliferation and differentiation. In the canonical pathway, Wnt ligands bind to Frizzled receptors, leading to the stabilization and nuclear translocation of  $\beta$ -catenin, which then activates target gene transcription.<sup>[18][19]</sup>

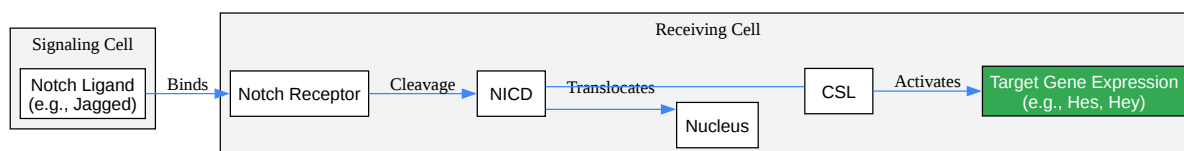


[Click to download full resolution via product page](#)

Caption: Wnt/β-catenin signaling in granulosa cells.

### 4.1.3 Notch Signaling in Follicular Development

Notch signaling, a form of juxtacrine signaling, is involved in granulosa cell proliferation and differentiation.[9][20] The interaction between Notch receptors and ligands on adjacent cells leads to the cleavage and nuclear translocation of the Notch intracellular domain (NICD), which activates target gene expression.[15]

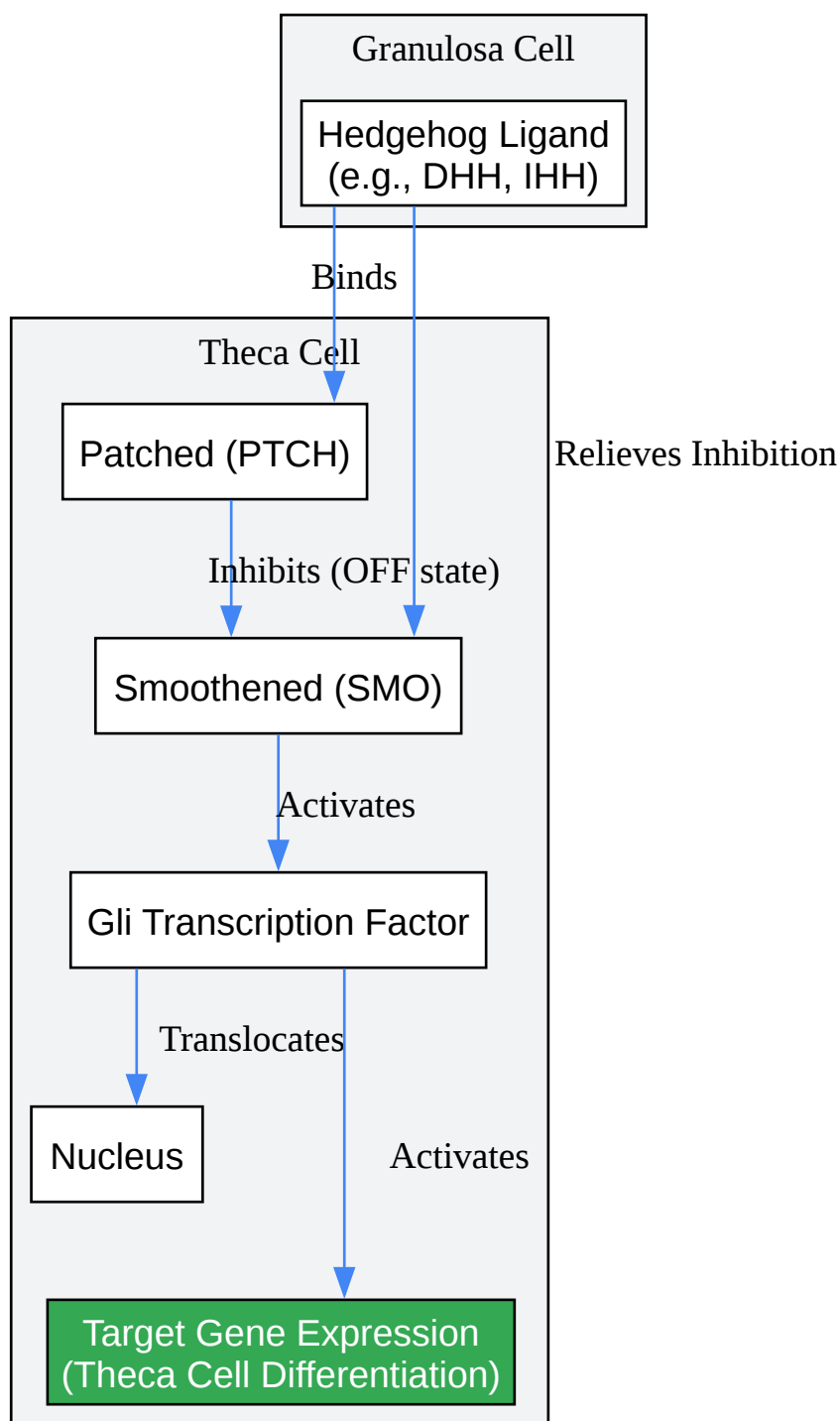


[Click to download full resolution via product page](#)

Caption: Notch signaling pathway in follicular cells.

### 4.1.4 Hedgehog Signaling in Theca Cell Development

Hedgehog signaling is crucial for the development and function of theca cells, which are responsible for androgen production. Granulosa cells secrete Hedgehog ligands that act on adjacent theca cells.[2][21]



[Click to download full resolution via product page](#)

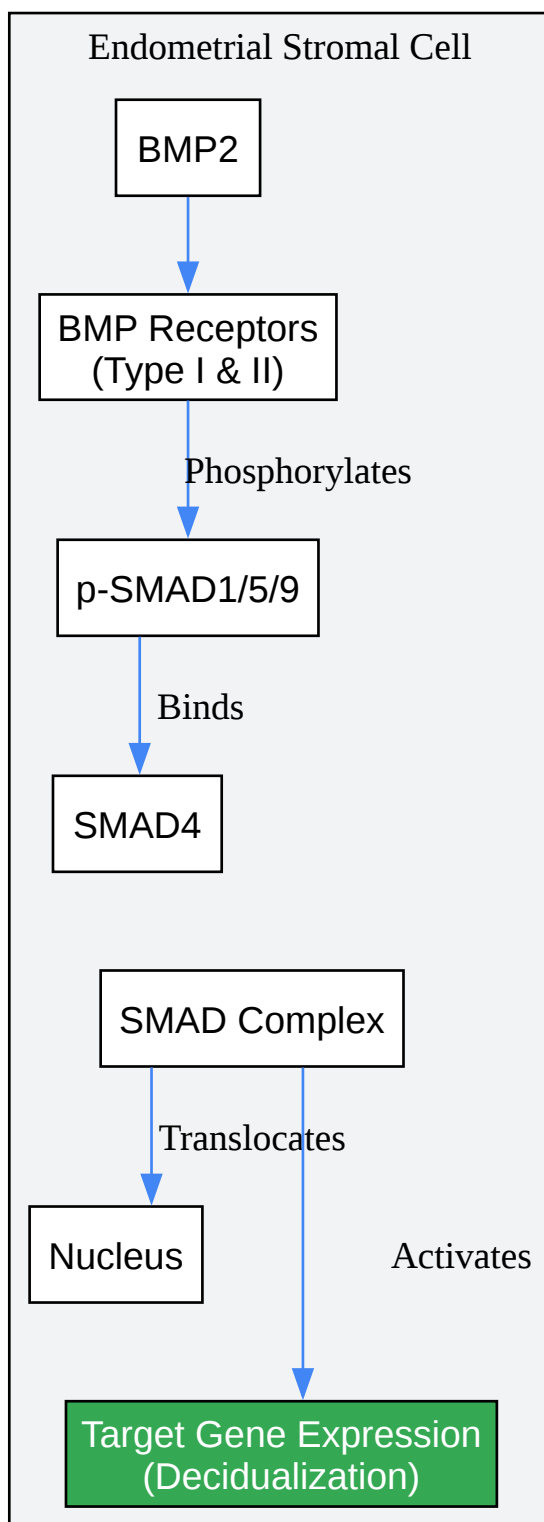
Caption: Hedgehog signaling in theca cell development.

## Signaling Pathways in Endometrial Receptivity

The establishment of a receptive endometrium is a complex process involving the coordinated action of various signaling molecules.

#### 4.2.1 BMP Signaling in Endometrial Decidualization

Bone Morphogenetic Protein (BMP) signaling, particularly BMP2, is essential for the decidualization of endometrial stromal cells, a critical step for implantation. BMP2 signals through its receptors to activate the SMAD signaling pathway.[\[22\]](#)[\[23\]](#)

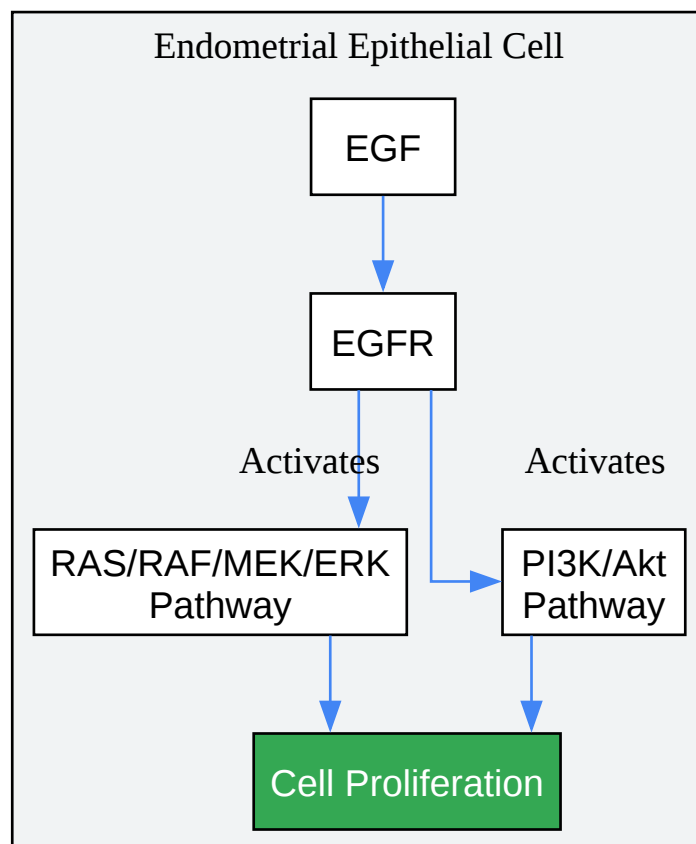


[Click to download full resolution via product page](#)

Caption: BMP signaling in endometrial decidualization.

#### 4.2.2 EGF Signaling in Endometrial Proliferation

Epidermal Growth Factor (EGF) and its receptor (EGFR) play a key role in regulating endometrial cell proliferation, a prerequisite for the development of a receptive endometrium.



[Click to download full resolution via product page](#)

Caption: EGF signaling in endometrial proliferation.

## Conclusion

Non-invasive ultrasonography is an indispensable tool in the evaluation of female fertility potential. The techniques and protocols outlined in this guide provide a robust framework for researchers, scientists, and drug development professionals to accurately assess key fertility parameters. By integrating quantitative data with an understanding of the underlying molecular signaling pathways, the application of ultrasonography can be further optimized to advance the field of reproductive medicine and facilitate the development of novel fertility treatments.



**Need Custom Synthesis?**

BenchChem offers custom synthesis for rare earth carbides and specific isotopic labeling.

Email: [info@benchchem.com](mailto:info@benchchem.com) or [Request Quote Online](#).

## References

- 1. Ultrasound-assessed endometrial receptivity measures for the prediction of in vitro fertilization-embryo transfer clinical pregnancy outcomes: A meta-analysis and systematic review - PMC [pmc.ncbi.nlm.nih.gov]
- 2. academic.oup.com [academic.oup.com]
- 3. researchgate.net [researchgate.net]
- 4. How to do a 3D uterus ultrasound? - PMC [pmc.ncbi.nlm.nih.gov]
- 5. [PDF] A Role of PI3K/Akt Signaling in Oocyte Maturation and Early Embryo Development | Semantic Scholar [semanticscholar.org]
- 6.  $\beta$ -Catenin regulates ovarian granulosa cell cycle and proliferation in laying hens by interacting with TCF4 - PMC [pmc.ncbi.nlm.nih.gov]
- 7. researchgate.net [researchgate.net]
- 8. Frontiers | ID3 mediates BMP2-induced downregulation of ICAM1 expression in human endometrial stromal cells and decidual cells [frontiersin.org]
- 9. The role of Notch signaling in the mammalian ovary - PMC [pmc.ncbi.nlm.nih.gov]
- 10. PI3K/PTEN/AKT Signaling Pathways in Germ Cell Development and Their Involvement in Germ Cell Tumors and Ovarian Dysfunctions - PMC [pmc.ncbi.nlm.nih.gov]
- 11. Association of Pre-Implantation Uterine Artery Doppler with Clinical Pregnancy in Assisted Reproductive Technology: A Systematic Review and Meta-Analysis [mdpi.com]
- 12. Analysis of the uterine artery pulsatility index on the day of endometrial transformation and pregnancy outcomes of patients undergoing frozen-thawed embryo transfer - PMC [pmc.ncbi.nlm.nih.gov]
- 13. Association of Pre-Implantation Uterine Artery Doppler with Clinical Pregnancy in Assisted Reproductive Technology: A Systematic Review and Meta-Analysis - PMC [pmc.ncbi.nlm.nih.gov]
- 14. Value of ovarian stromal blood flow velocity measurement after pituitary suppression in the prediction of ovarian responsiveness and outcome of in vitro fertilization treatment -

PubMed [pubmed.ncbi.nlm.nih.gov]

- 15. researchgate.net [researchgate.net]
- 16. Notch Signaling Regulates Differentiation and Steroidogenesis in Female Mouse Ovarian Granulosa Cells - PMC [pmc.ncbi.nlm.nih.gov]
- 17. The Relationship Between Uterine Artery two-dimensional Color Doppler Measurement and Pregnancy Outcome: A Prospective Observational Study - PMC [pmc.ncbi.nlm.nih.gov]
- 18. WNT signaling in pre-granulosa cells is required for ovarian folliculogenesis and female fertility - PMC [pmc.ncbi.nlm.nih.gov]
- 19. The role of WNT signaling in adult ovarian folliculogenesis - PMC [pmc.ncbi.nlm.nih.gov]
- 20. Notch Signaling Regulates Differentiation and Steroidogenesis in Female Mouse Ovarian Granulosa Cells - PubMed [pubmed.ncbi.nlm.nih.gov]
- 21. mdpi.com [mdpi.com]
- 22. Bmp2 Is Critical for the Murine Uterine Decidual Response - PMC [pmc.ncbi.nlm.nih.gov]
- 23. Impaired bone morphogenetic protein signaling pathways disrupt decidualization in endometriosis - PMC [pmc.ncbi.nlm.nih.gov]
- To cite this document: BenchChem. [Non-Invasive Fertility Potential Evaluation: An In-depth Technical Guide Using Ultrasonography]. BenchChem, [2025]. [Online PDF]. Available at: [https://www.benchchem.com/product/b1674034#non-invasive-evaluation-of-fertility-potential-using-ultrasonography]

---

#### Disclaimer & Data Validity:

The information provided in this document is for Research Use Only (RUO) and is strictly not intended for diagnostic or therapeutic procedures. While BenchChem strives to provide accurate protocols, we make no warranties, express or implied, regarding the fitness of this product for every specific experimental setup.

**Technical Support:** The protocols provided are for reference purposes. Unsure if this reagent suits your experiment? [[Contact our Ph.D. Support Team for a compatibility check](#)]

**Need Industrial/Bulk Grade?** [Request Custom Synthesis Quote](#)

# BenchChem

Our mission is to be the trusted global source of essential and advanced chemicals, empowering scientists and researchers to drive progress in science and industry.

## Contact

Address: 3281 E Guasti Rd

Ontario, CA 91761, United States

Phone: (601) 213-4426

Email: [info@benchchem.com](mailto:info@benchchem.com)