

Basic understanding of transvaginal ultrasound for pelvic organ assessment

Author: BenchChem Technical Support Team. **Date:** December 2025

Compound of Interest

Compound Name: FR 76830

Cat. No.: B1674034

[Get Quote](#)

A Technical Guide to Transvaginal Ultrasound for Pelvic Organ Assessment

For Researchers, Scientists, and Drug Development Professionals

This in-depth technical guide provides a comprehensive overview of the principles and applications of transvaginal ultrasound (TVUS) for the assessment of female pelvic organs. It is designed to equip researchers, scientists, and drug development professionals with a foundational understanding of this critical imaging modality, including detailed methodologies, quantitative data for analysis, and standardized procedural workflows.

Fundamental Principles of Transvaginal Ultrasound

Transvaginal ultrasound is a specialized imaging technique that utilizes a high-frequency ultrasound transducer inserted into the vagina to visualize the female reproductive organs with high resolution.[1][2] By positioning the transducer in close proximity to the pelvic structures, TVUS overcomes the limitations of transabdominal ultrasound, such as signal attenuation by the abdominal wall, providing superior anatomic detail.[1] This method is indispensable for a thorough evaluation of the uterus, endometrium, ovaries, fallopian tubes, and surrounding pelvic anatomy.[1][3]

The procedure involves the emission of high-frequency sound waves from the transducer, which travel through the tissues and are reflected back.[4] The returning echoes are processed

by the ultrasound machine to generate a real-time, two-dimensional or three-dimensional image. Doppler ultrasound, a complementary technique, can be employed to assess blood flow within the pelvic organs by detecting the frequency shift of the ultrasound waves reflected from moving red blood cells.[5]

Standardized Protocol for Pelvic Organ Assessment

A systematic and standardized approach is crucial for a comprehensive and reproducible transvaginal ultrasound examination. The following protocol outlines the key steps for a basic pelvic ultrasound examination.[6]

Patient Preparation and Transducer Handling

Prior to the examination, the patient should be informed about the procedure and provide consent.[1] The bladder should be emptied to optimize visualization of the pelvic organs.[2] The transvaginal transducer, typically with a frequency range of 5-12 MHz, is covered with a sterile probe cover and lubricating gel before gentle insertion into the vagina.[1][6]

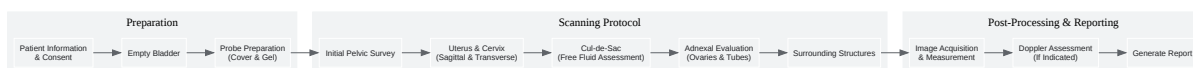Systematic Scanning Technique

The examination begins with a general survey of the pelvis. The transducer is manipulated to obtain images in both the sagittal (longitudinal) and coronal (transverse) planes.[1] A standardized five-step approach ensures all pelvic structures are thoroughly evaluated:

- **Bladder Assessment:** The bladder is initially assessed for any abnormalities.
- **Uterus and Cervix Evaluation:** The uterus is examined in the midsagittal plane to measure its length and anteroposterior diameter.[6] The transducer is then swept from side to side to visualize the entire myometrium and endometrium. The cervix is also evaluated in both sagittal and transverse planes.[1]
- **Cul-de-Sac Examination:** The posterior cul-de-sac (Pouch of Douglas) is inspected for the presence of free fluid or any masses.[3]
- **Adnexal Assessment:** Each ovary is identified and imaged in two planes. Ovarian volume is calculated, and the number and size of any follicles are documented.[7]

- **Surrounding Structures:** The adnexal regions are carefully examined for any masses or other abnormalities.

The following diagram illustrates the general workflow of a standardized transvaginal ultrasound examination.



[Click to download full resolution via product page](#)

Standardized Transvaginal Ultrasound Examination Workflow

Quantitative Assessment of Pelvic Organs

Quantitative measurements obtained from transvaginal ultrasound are essential for diagnosing pathologies and monitoring treatment responses in clinical trials. The following tables summarize key quantitative data for various pelvic organs.

Uterine and Ovarian Dimensions

Normal uterine and ovarian volumes vary with age and menstrual cycle phase.

Organ	Parameter	Premenopausal	Postmenopausal
Uterus	Length	5.0 - 8.0 cm[8]	Varies, generally smaller
Volume	Mean: 25.5 ± 27.0 cm ³ [9]	Varies, generally smaller	
Ovary	Volume (Nulliparous)	< 9.0 mL[2]	< 6.0 mL
Volume (Parous)	< 15.0 mL[2]	< 6.0 mL	
Volume (Mean)	Right: 4.5 ± 4.7 cm ³ , Left: 4.0 ± 4.1 cm ³ [9]	Varies, generally smaller	

Endometrial Thickness

Endometrial thickness is a critical parameter, particularly in the evaluation of abnormal uterine bleeding and in fertility assessments.^[10]

Menstrual Phase	Typical Thickness (mm)
Menstruation	2 - 4 ^[10]
Early Proliferative	5 - 7 ^[10]
Late Proliferative	Up to 11 ^[10]
Secretory	7 - 16 ^[10]
Postmenopausal	
- With Bleeding	< 5 ^[10]
- Without Bleeding	< 11 ^[10]
- On Tamoxifen	< 5 ^[10]

Key Clinical Applications and Experimental Protocols

Transvaginal ultrasound is a cornerstone in the diagnosis and management of numerous gynecological conditions.

Endometrial Assessment

Objective: To evaluate the thickness and morphology of the endometrium for the diagnosis of conditions such as endometrial hyperplasia, polyps, and carcinoma.^[11]

Experimental Protocol:

- **Patient Positioning:** The patient is placed in the dorsal lithotomy position.
- **Transducer Insertion:** A high-frequency transvaginal transducer is inserted into the vagina.

- **Image Acquisition:** The uterus is identified in the midsagittal plane. The endometrial thickness is measured as the maximum distance between the two echogenic lines of the myometrial-endometrial interface, including both endometrial layers.^[10] Care is taken to exclude any intrauterine fluid from the measurement.^[10]
- **Morphological Evaluation:** The echotexture of the endometrium is assessed for homogeneity, the presence of cysts, or focal thickening.

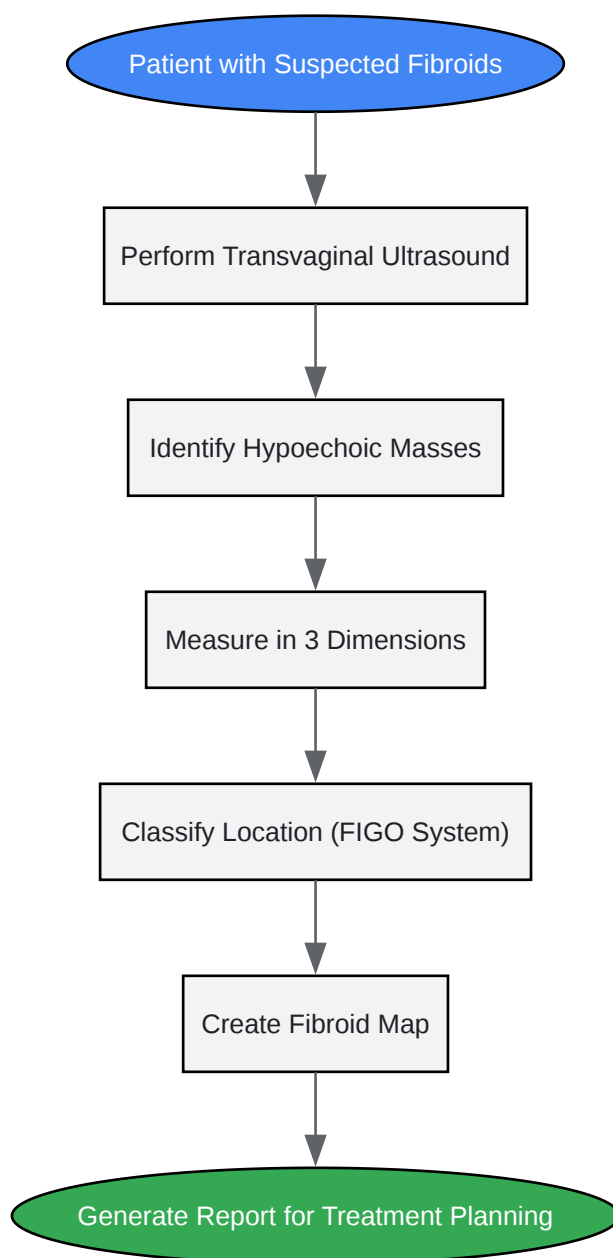
Uterine Fibroid Mapping

Objective: To accurately determine the number, size, and location of uterine fibroids (leiomyomas) for diagnosis and surgical planning.^{[4][12]}

Experimental Protocol:

- **Systematic Uterine Survey:** The entire uterus is scanned in both sagittal and transverse planes.
- **Fibroid Identification and Measurement:** Each identified fibroid is measured in three orthogonal dimensions (longitudinal, anteroposterior, and transverse).^[12]
- **Localization and Classification:** The location of each fibroid is documented according to the International Federation of Gynecology and Obstetrics (FIGO) classification system (e.g., submucosal, intramural, subserosal).^[12]
- **Doppler Assessment (Optional):** Color or power Doppler can be used to assess the vascularity of the fibroids.

The following diagram illustrates the logical process for uterine fibroid assessment.



[Click to download full resolution via product page](#)

Logical Workflow for Uterine Fibroid Assessment

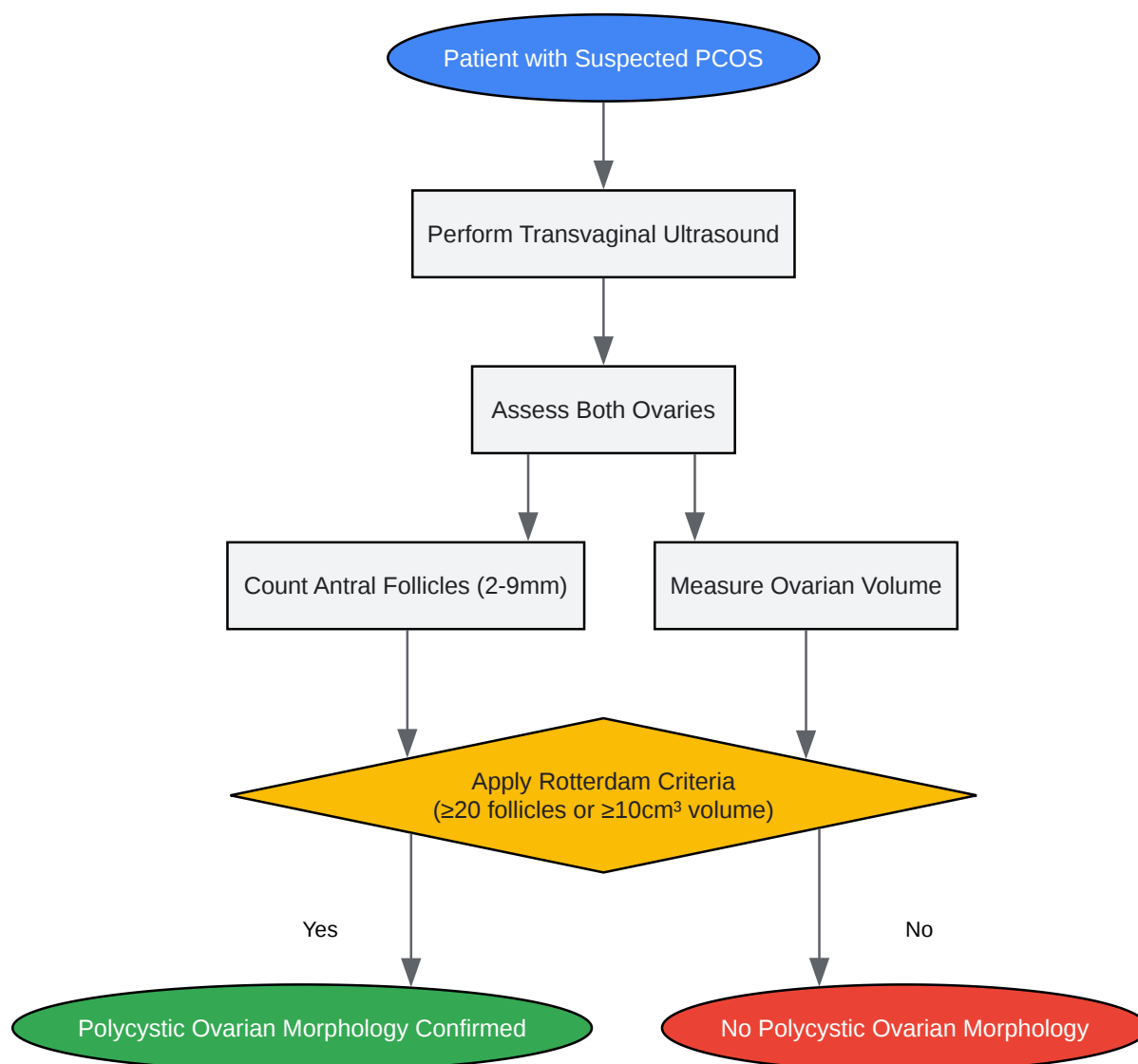Polycystic Ovary Syndrome (PCOS) Diagnosis

Objective: To assess ovarian morphology for the diagnosis of Polycystic Ovary Syndrome (PCOS) based on established criteria.[13][14]

Experimental Protocol:

- Ovarian Visualization: Both ovaries are systematically scanned.
- Follicle Count: The number of antral follicles measuring 2-9 mm in diameter is counted in each ovary.[13]
- Ovarian Volume Measurement: The ovarian volume is calculated using the simplified formula for a prolate ellipsoid: $\text{Volume} = 0.523 \times \text{length} \times \text{width} \times \text{height}$. [13]
- Diagnostic Criteria Application: The findings are evaluated against the Rotterdam criteria, where polycystic ovarian morphology is defined by the presence of ≥ 20 follicles per ovary and/or an ovarian volume of $\geq 10 \text{ cm}^3$ on either ovary.[15]

The diagnostic algorithm for PCOS using transvaginal ultrasound is depicted below.



[Click to download full resolution via product page](#)

Diagnostic Algorithm for PCOS via Transvaginal Ultrasound

Follicular Tracking in Fertility Treatment

Objective: To monitor the growth of ovarian follicles in natural or stimulated cycles to determine the optimal time for intercourse, insemination, or oocyte retrieval.[16]

Experimental Protocol:

- **Baseline Scan:** A baseline scan is typically performed on day 2 or 3 of the menstrual cycle to assess the antral follicle count.
- **Serial Monitoring:** Serial transvaginal ultrasound scans are performed every 1-3 days to monitor the growth of the follicles.[\[17\]](#)
- **Follicle Measurement:** The mean diameter of the dominant follicle(s) is measured at each visit. Follicles are expected to grow 1-3 mm per day.[\[16\]](#)
- **Endometrial Assessment:** The thickness and pattern of the endometrium are also monitored. An endometrial thickness of at least 8 mm is generally considered receptive for implantation. [\[16\]](#)
- **Timing of Intervention:** When the dominant follicle reaches a mature size (typically 18-24 mm), the timing for intervention (e.g., hCG trigger shot, oocyte retrieval) is determined.[\[16\]](#)

Advanced Techniques: 3D and Doppler Ultrasound

Three-Dimensional (3D) Ultrasound

3D transvaginal ultrasound allows for the acquisition of a volume of data, which can then be reconstructed and viewed in any plane, including the coronal plane, which is not achievable with 2D ultrasound. This is particularly valuable for:

- **Congenital Uterine Anomalies:** Providing a detailed view of the uterine fundal contour.
- **Submucosal Fibroids:** Accurately assessing the degree of myometrial extension.
- **Intrauterine Device (IUD) Localization:** Precisely determining the position of an IUD.

Doppler Ultrasound

Doppler ultrasound provides information about blood flow and vascularization. In the context of pelvic assessment, it is used to:

- **Characterize Ovarian Masses:** Differentiating between benign and malignant masses based on their vascular patterns.

- Assess Uterine Fibroid Vascularity: Evaluating the blood supply to fibroids, which may have implications for treatment response.[12]
- Diagnose Ovarian Torsion: The absence of blood flow within the ovary is a key sign of torsion.[7]
- Evaluate Pelvic Venous Disorders: Identifying pelvic varicosities and venous reflux.[5]

Conclusion

Transvaginal ultrasound is a powerful and indispensable tool in the field of gynecological research and drug development. Its ability to provide high-resolution images of the pelvic organs allows for precise quantitative measurements and detailed morphological assessment. A thorough understanding of the standardized protocols, quantitative data, and various clinical applications outlined in this guide is essential for obtaining accurate and reproducible results in both clinical and research settings. The continued advancement of ultrasound technology, including 3D imaging and Doppler applications, will further enhance its diagnostic capabilities and its role in advancing women's health.

Need Custom Synthesis?

BenchChem offers custom synthesis for rare earth carbides and specific isotopic labeling.

Email: info@benchchem.com or [Request Quote Online](#).

References

- 1. Sonography Transvaginal Assessment, Protocols, and Interpretation - StatPearls - NCBI Bookshelf [ncbi.nlm.nih.gov]
- 2. radiopaedia.org [radiopaedia.org]
- 3. Normal Anatomy of the Female Pelvis and Transvaginal Sonography | Radiology Key [radiologykey.com]
- 4. Uterine fibroids - Diagnosis and treatment - Mayo Clinic [mayoclinic.org]
- 5. Transvaginal ultrasound approach for diagnosing pelvic venous disorders [pubmed.ncbi.nlm.nih.gov]
- 6. glowm.com [glowm.com]

- 7. droracle.ai [droracle.ai]
- 8. Normative values of the internal genital organs of the female pelvis in transvaginal and transabdominal ultrasound - PubMed [pubmed.ncbi.nlm.nih.gov]
- 9. Normative values for ultrasound measurements of the female pelvic organs throughout childhood and adolescence - PubMed [pubmed.ncbi.nlm.nih.gov]
- 10. radiopaedia.org [radiopaedia.org]
- 11. Endometrial thickness cut-off value by transvaginal ultrasonography for screening of endometrial pathology in premenopausal and postmenopausal women - PMC [pmc.ncbi.nlm.nih.gov]
- 12. Reporting of uterine fibroids on ultrasound examinations: an illustrated report template focused on surgical planning - PMC [pmc.ncbi.nlm.nih.gov]
- 13. droracle.ai [droracle.ai]
- 14. Polycystic ovary syndrome - Wikipedia [en.wikipedia.org]
- 15. mdpi.com [mdpi.com]
- 16. Understanding the Basics of Follicular Tracking - International Ultrasound Services [iuslondon.co.uk]
- 17. TRANSVAGINAL SONOGRAPHIC STUDY OF FOLLICULAR DYNAMICS IN SPONTANEOUS AND CLOMIPHENE CITRATE CYCLES - PMC [pmc.ncbi.nlm.nih.gov]
- To cite this document: BenchChem. [Basic understanding of transvaginal ultrasound for pelvic organ assessment]. BenchChem, [2025]. [Online PDF]. Available at: [https://www.benchchem.com/product/b1674034#basic-understanding-of-transvaginal-ultrasound-for-pelvic-organ-assessment]

Disclaimer & Data Validity:

The information provided in this document is for Research Use Only (RUO) and is strictly not intended for diagnostic or therapeutic procedures. While BenchChem strives to provide accurate protocols, we make no warranties, express or implied, regarding the fitness of this product for every specific experimental setup.

Technical Support: The protocols provided are for reference purposes. Unsure if this reagent suits your experiment? [[Contact our Ph.D. Support Team for a compatibility check](#)]

Need Industrial/Bulk Grade? [Request Custom Synthesis Quote](#)

BenchChem

Our mission is to be the trusted global source of essential and advanced chemicals, empowering scientists and researchers to drive progress in science and industry.

Contact

Address: 3281 E Guasti Rd

Ontario, CA 91761, United States

Phone: (601) 213-4426

Email: info@benchchem.com