

Comparative analysis of FMISO PET and MRI for tumor characterization

Author: BenchChem Technical Support Team. **Date:** December 2025

Compound of Interest

Compound Name: Fluoromisonidazole

Cat. No.: B1672914

[Get Quote](#)

A Comparative Analysis of FMISO PET and MRI for Tumor Characterization

In the landscape of oncological research and drug development, the precise characterization of the tumor microenvironment is paramount for predicting treatment response and developing novel therapeutic strategies. Among the various imaging modalities, Positron Emission Tomography (PET) with the tracer ^{18}F -**Fluoromisonidazole** (FMISO) and multiparametric Magnetic Resonance Imaging (MRI) have emerged as powerful tools for non-invasively assessing key tumor characteristics. This guide provides a comparative analysis of FMISO PET and various MRI techniques, offering insights into their respective strengths, methodologies, and applications in tumor characterization, supported by experimental data.

FMISO PET: A Window into Tumor Hypoxia

Tumor hypoxia, a state of low oxygen tension, is a critical factor associated with tumor progression, metastasis, and resistance to therapy.[1] ^{18}F -FMISO PET is a widely utilized imaging technique that provides a quantitative measure of hypoxia in solid tumors.[1][2]

Mechanism of Action: FMISO is a 2-nitroimidazole compound that, once administered intravenously, passively diffuses into tissues.[3] In hypoxic cells, where the partial pressure of oxygen is low, FMISO undergoes bioreduction by nitroreductases and becomes covalently bound to intracellular macromolecules, leading to its accumulation.[2][3] In normoxic cells, the reduced FMISO is readily reoxidized and diffuses out of the cell.[3] The degree of FMISO uptake, therefore, is directly proportional to the level of hypoxia.[4]

Multiparametric MRI: A Multi-faceted View of Tumor Biology

Multiparametric MRI (mpMRI) combines several advanced MRI sequences to provide a comprehensive assessment of tumor pathophysiology, including vascularity, cellularity, and metabolism.^[5]

- **Dynamic Contrast-Enhanced MRI (DCE-MRI):** This technique assesses tumor perfusion and vascular permeability by monitoring the pharmacokinetics of a gadolinium-based contrast agent as it passes through the tumor vasculature.^{[6][7]} Key parameters derived from DCE-MRI, such as K_{trans} (volume transfer constant), provide insights into blood flow and vessel leakiness, which are often altered in tumors.^{[8][9]}
- **Diffusion-Weighted Imaging (DWI):** DWI measures the random motion of water molecules within tissue.^[10] In densely packed cellular environments, such as in many tumors, the diffusion of water is restricted.^{[11][12]} The Apparent Diffusion Coefficient (ADC) is a quantitative parameter derived from DWI that is inversely correlated with tumor cellularity.^[11]
- **Magnetic Resonance Spectroscopy (MRS):** MRS is a non-invasive technique that provides information about the biochemical composition of tissues.^{[13][14]} By detecting the signals from various metabolites, such as choline, creatine, and N-acetylaspartate, MRS can offer insights into cellular proliferation, membrane turnover, and metabolic activity within the tumor.^{[15][16]}

Comparative Analysis: FMISO PET vs. MRI

While both FMISO PET and mpMRI provide valuable information for tumor characterization, they assess different aspects of the tumor microenvironment. FMISO PET directly measures hypoxia, a specific and crucial driver of tumor aggressiveness and treatment resistance.^[1] In contrast, mpMRI techniques provide surrogate markers that are often correlated with hypoxia but are not direct measures of oxygen tension. For instance, altered perfusion and high cellularity, as measured by DCE-MRI and DWI respectively, can be associated with hypoxic regions, but this is not always a direct one-to-one relationship.^{[17][18]}

A study comparing quantitative MRI with FMISO PET/CT in oropharynx cancers found significant differences in the quantitative MRI parameters (ADC, T1 mapping, and T2 mapping)

between hypoxic and normoxic subvolumes as defined by FMISO PET.[\[17\]](#)[\[18\]](#) This suggests that mpMRI can help identify intra-tumoral hypoxic sub-volumes, although FMISO PET remains the gold standard for direct hypoxia imaging.[\[18\]](#)[\[19\]](#)[\[20\]](#)

Quantitative Data Summary

The following tables summarize key quantitative parameters obtained from FMISO PET and various MRI techniques for tumor characterization.

FMISO PET Parameter	Typical Value in Hypoxic Tumors	Description	Reference
Tumor-to-Blood Ratio (TBR)	> 1.2 - 1.4	Ratio of FMISO uptake in the tumor to that in the blood pool, indicating relative hypoxia.	[4] [21]
Maximum Standardized Uptake Value (SUVmax)	Variable (e.g., mean of 2.3 in one study)	A semi-quantitative measure of tracer uptake, normalized to injected dose and body weight.	[17]
Hypoxic Volume (HV)	Variable (e.g., mean of 40.2 mL in one study)	The volume of the tumor with a TBR above a certain threshold, representing the extent of hypoxia.	[4]

MRI Parameter	Technique	Typical Finding in Aggressive Tumors	Description	Reference
Ktrans (Volume Transfer Constant)	DCE-MRI	Elevated	Reflects capillary permeability and blood flow.	[8]
Ve (Extracellular Extravascular Volume Fraction)	DCE-MRI	Variable	Represents the volume of the extravascular, extracellular space.	[6]
Apparent Diffusion Coefficient (ADC)	DWI	Decreased	Inversely correlates with tumor cellularity.	[10][11]
Choline (Cho) / N-acetylaspartate (NAA) ratio	MRS	Elevated	Indicates increased cell membrane turnover and decreased neuronal integrity.	[13][14]
Lactate Peak	MRS	Present	Suggests anaerobic metabolism, often associated with hypoxia.	[15][16]

Experimental Protocols

Detailed methodologies are crucial for the reproducibility and interpretation of imaging studies. Below are representative experimental protocols for FMISO PET and key mpMRI sequences.

FMISO PET Protocol

- Patient Preparation: Patients are typically not required to fast.[4] Venous access is established for tracer injection and, if required, blood sampling.[22]
- Tracer Injection: ^{18}F -FMISO is injected intravenously at a dose of approximately 3.7 MBq/kg (0.1 mCi/kg).[4][22]
- Uptake Period: A waiting period of 2 to 4 hours allows for the accumulation of FMISO in hypoxic tissues.[2][23]
- Image Acquisition: A PET/CT scan of the tumor region is acquired. Static emission scans are typically performed for 10-20 minutes.[4][24]
- Image Analysis: Tumor-to-blood ratios (TBR) are calculated by normalizing the tumor uptake to the activity in a large blood pool (e.g., aorta or heart). A TBR threshold of 1.2 to 1.4 is commonly used to define hypoxic regions.[21]

Multiparametric MRI Protocol

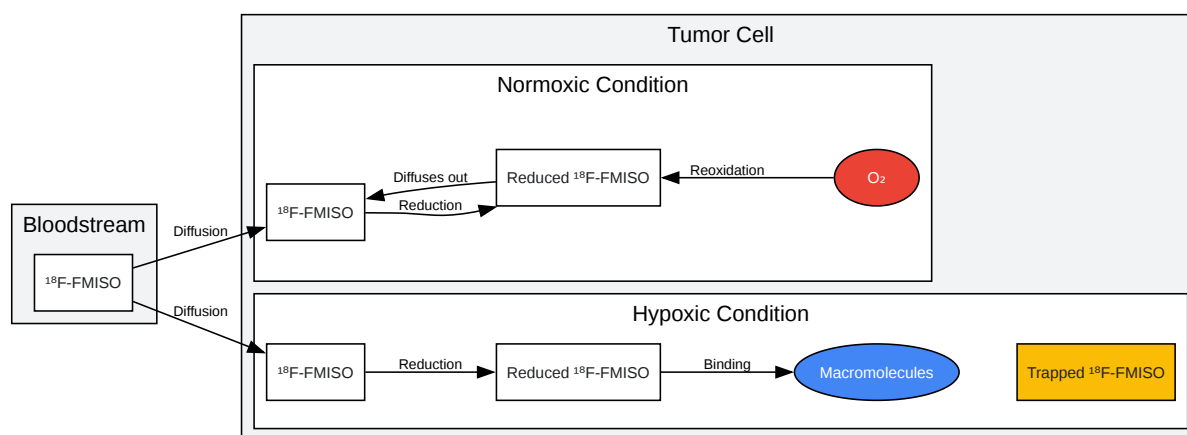
A typical mpMRI protocol for tumor characterization includes the following sequences:[25]

- T2-Weighted Imaging (T2W): Provides anatomical details of the tumor and surrounding tissues.
- Diffusion-Weighted Imaging (DWI):
 - Sequence: Echo-planar imaging (EPI) sequence.
 - b-values: A minimum of two b-values are used (e.g., 0 and 1000 s/mm²).[10]
 - Analysis: ADC maps are generated to quantify the degree of water diffusion restriction.
- Dynamic Contrast-Enhanced (DCE)-MRI:
 - Sequence: A fast T1-weighted gradient-echo sequence is used.[26]
 - Contrast Agent: A bolus of a gadolinium-based contrast agent is injected intravenously at a rate of 2-4 mL/s.[5]

- Acquisition: A series of images are acquired before, during, and after the contrast injection with a temporal resolution of 5-10 seconds for approximately 5 minutes.[6]
- Analysis: Pharmacokinetic models are applied to the dynamic data to generate parametric maps of Ktrans, Ve, etc.[27]
- Magnetic Resonance Spectroscopy (MRS):
 - Localization: A voxel of interest is placed over the tumor region.
 - Sequence: Single-voxel spectroscopy (SVS) or multi-voxel chemical shift imaging (CSI) can be used.[16]
 - Analysis: The resulting spectra are analyzed to identify and quantify the peaks of various metabolites.

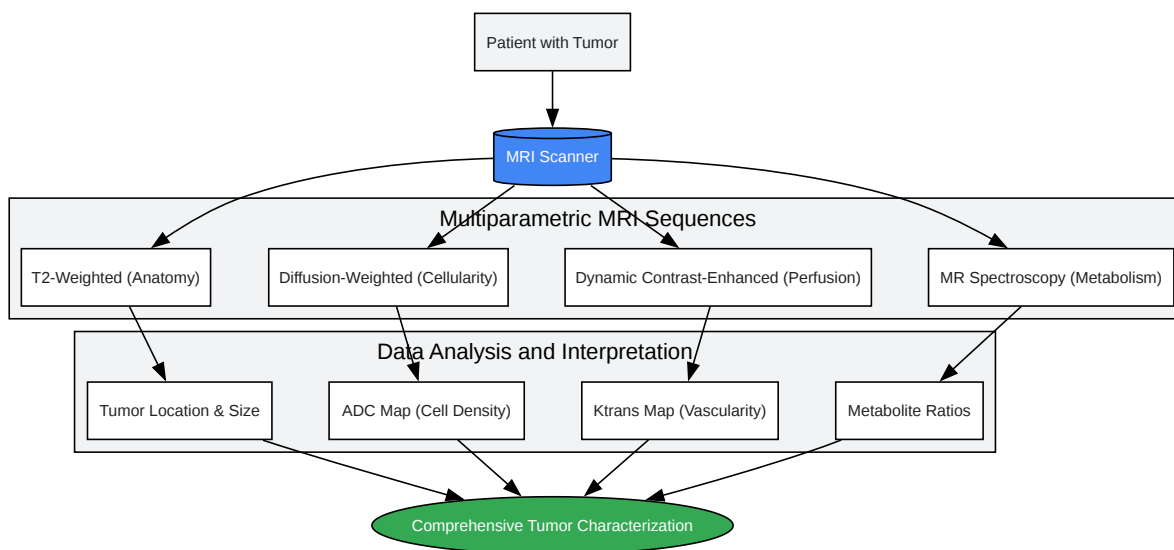
Visualizing the Concepts

To better illustrate the underlying principles and workflows, the following diagrams are provided.



[Click to download full resolution via product page](#)

Caption: Mechanism of ^{18}F -FMISO uptake in normoxic versus hypoxic tumor cells.



[Click to download full resolution via product page](#)

Caption: Workflow for multiparametric MRI in tumor characterization.

Conclusion

Both FMISO PET and multiparametric MRI are indispensable tools in the arsenal of tumor imaging. FMISO PET offers a direct and quantitative assessment of tumor hypoxia, a key determinant of treatment response. Multiparametric MRI, on the other hand, provides a broader, multi-faceted view of the tumor's anatomical and physiological characteristics. The choice of imaging modality, or a combination thereof, will depend on the specific clinical or research question being addressed. For researchers and drug development professionals, an understanding of the principles, protocols, and comparative performance of these techniques is

essential for designing robust studies and accurately interpreting their outcomes. The integration of these advanced imaging techniques holds great promise for advancing personalized cancer therapy.

Need Custom Synthesis?

BenchChem offers custom synthesis for rare earth carbides and specific isotopic labeling.

Email: info@benchchem.com or [Request Quote Online](#).

References

- 1. 18F-Fluoromisonidazole in tumor hypoxia imaging - PMC [pmc.ncbi.nlm.nih.gov]
- 2. F18 Fluoromisonidazole for Imaging Tumor Hypoxia: Imaging the Microenvironment for Personalized Cancer Therapy - PMC [pmc.ncbi.nlm.nih.gov]
- 3. The Roles of Hypoxia Imaging Using 18F-Fluoromisonidazole Positron Emission Tomography in Glioma Treatment - PMC [pmc.ncbi.nlm.nih.gov]
- 4. Tumor Hypoxia Imaging with [F-18] Fluoromisonidazole Positron Emission Tomography in Head and Neck Cancer - PMC [pmc.ncbi.nlm.nih.gov]
- 5. DCE-MRI, DW-MRI, and MRS in Cancer: Challenges and Advantages of Implementing Qualitative and Quantitative Multi-parametric Imaging in the Clinic - PMC [pmc.ncbi.nlm.nih.gov]
- 6. Dynamic Contrast-Enhanced MRI in the Evaluation of Soft Tissue Tumors and Tumor-Like Lesions: Technical Principles and Clinical Applications - PMC [pmc.ncbi.nlm.nih.gov]
- 7. Perfusion Magnetic Resonance Imaging: A Comprehensive Update on Principles and Techniques - PMC [pmc.ncbi.nlm.nih.gov]
- 8. 5 Perfusion Imaging: Dynamic Contrast-Enhanced T1-Weighted MRI (DCE-MRI) Perfusion | Radiology Key [radiologykey.com]
- 9. Diffusion-weighted magnetic resonance imaging for tumour response assessment: why, when and how? - PMC [pmc.ncbi.nlm.nih.gov]
- 10. Diffusion-Weighted Imaging in Oncology: An Update - PMC [pmc.ncbi.nlm.nih.gov]
- 11. aacrjournals.org [aacrjournals.org]
- 12. The role of diffusion weighted magnetic resonance imaging in oncologic settings - Bozgeyik - Quantitative Imaging in Medicine and Surgery [qims.amegroups.org]

- 13. Imaging Tumor Metabolism using in vivo MR Spectroscopy - PMC [pmc.ncbi.nlm.nih.gov]
- 14. Magnetic Resonance Spectroscopy, MR spectroscopy [mayfieldclinic.com]
- 15. Frontiers | Emerging MR Imaging and Spectroscopic Methods to Study Brain Tumor Metabolism [frontiersin.org]
- 16. Magnetic resonance spectroscopic imaging for detecting metabolic changes in glioblastoma after anti-angiogenic therapy—a systematic literature review - PMC [pmc.ncbi.nlm.nih.gov]
- 17. Quantitative MRI to Characterize Hypoxic Tumors in Comparison to FMISO PET/CT for Radiotherapy in Oropharynx Cancers - PMC [pmc.ncbi.nlm.nih.gov]
- 18. Quantitative MRI to Characterize Hypoxic Tumors in Comparison to FMISO PET/CT for Radiotherapy in Oropharynx Cancers - PubMed [pubmed.ncbi.nlm.nih.gov]
- 19. Quantitative MRI to Characterize Hypoxic Tumors in Comparison to FMISO PET/CT for Radiotherapy in Oropharynx Cancers [ouci.dntb.gov.ua]
- 20. researchgate.net [researchgate.net]
- 21. Multiparametric Imaging of Tumor Hypoxia and Perfusion with 18F-Fluoromisonidazole Dynamic PET in Head and Neck Cancer - PMC [pmc.ncbi.nlm.nih.gov]
- 22. Hypoxia Imaging with [F-18] FMISO-PET in Head and Neck Cancer: Potential for Guiding Intensity Modulated Radiation Therapy in Overcoming Hypoxia-Induced Treatment Resistance - PMC [pmc.ncbi.nlm.nih.gov]
- 23. Imaging Hypoxia with 18F-Fluoromisonidazole: Challenges in Moving to a More Complicated Analysis - PMC [pmc.ncbi.nlm.nih.gov]
- 24. Delineation techniques of tumor hypoxia volume with 18F-FMISO PET imaging | IEEE Conference Publication | IEEE Xplore [ieeexplore.ieee.org]
- 25. epos.myesr.org [epos.myesr.org]
- 26. asnr.org [asnr.org]
- 27. radiopaedia.org [radiopaedia.org]
- To cite this document: BenchChem. [Comparative analysis of FMISO PET and MRI for tumor characterization]. BenchChem, [2025]. [Online PDF]. Available at: [https://www.benchchem.com/product/b1672914#comparative-analysis-of-fmiso-pet-and-mri-for-tumor-characterization]

Disclaimer & Data Validity:

The information provided in this document is for Research Use Only (RUO) and is strictly not intended for diagnostic or therapeutic procedures. While BenchChem strives to provide accurate protocols, we make no warranties, express or implied, regarding the fitness of this product for every specific experimental setup.

Technical Support: The protocols provided are for reference purposes. Unsure if this reagent suits your experiment? [[Contact our Ph.D. Support Team for a compatibility check](#)]

Need Industrial/Bulk Grade? [Request Custom Synthesis Quote](#)

BenchChem

Our mission is to be the trusted global source of essential and advanced chemicals, empowering scientists and researchers to drive progress in science and industry.

Contact

Address: 3281 E Guasti Rd
Ontario, CA 91761, United States
Phone: (601) 213-4426
Email: info@benchchem.com