

# Image artifacts associated with early Diodone urography

**Author:** BenchChem Technical Support Team. **Date:** December 2025

## Compound of Interest

Compound Name: Diodone

Cat. No.: B1670706

[Get Quote](#)

## Technical Support Center: Early Diodone Urography

This technical support center provides troubleshooting guidance for researchers, scientists, and drug development professionals working with historical data or protocols involving early **Diodone** (also known as Iodopyracet or Diodrast) urography. The information addresses common image quality issues and artifacts encountered during this historical imaging technique.

## Frequently Asked Questions (FAQs) & Troubleshooting

**Q1:** Why is the visualization of the renal parenchyma (nephrogram) faint or inconsistent in my early-phase urograms?

**A1:** A faint or poor nephrogram was a common issue in early **Diodone** urography and could be attributed to several factors:

- **Contrast Agent Properties:** **Diodone**, an early ionic monomer, provided lower contrast compared to modern agents. Its concentration and rapid excretion profile might not have been sufficient for dense and sustained parenchymal opacification.

- **Injection Technique:** A slow or inconsistent intravenous injection rate could lead to inadequate peak concentration of the contrast medium in the renal arteries. Conversely, an overly rapid injection was sometimes thought to cause vascular spasm, further reducing renal blood flow and contrast delivery.
- **Patient's Physiological State:** Dehydration could lead to reduced renal blood flow and glomerular filtration rate, resulting in a poor nephrogram. Severe dehydration was a contraindication for the procedure.<sup>[1]</sup> Uremia could also compromise the quality of the study due to poor contrast concentration.<sup>[1]</sup>
- **Timing of Radiographs:** The timing for capturing the nephrographic phase is critical. Images taken too early or too late would miss the peak parenchymal enhancement. This phase typically occurs within the first 1-3 minutes post-injection.<sup>[2]</sup>

Q2: My urogram images are obscured by dark, irregular shadows, particularly over the kidneys and ureters. What is causing this artifact?

A2: This is most likely due to overlying bowel gas and feces. This was one of the most significant disadvantages of excretory urography, limiting the evaluation of the upper urinary tract.<sup>[3]</sup>

- **Cause:** Gas and fecal matter in the intestines absorb X-rays differently than the surrounding soft tissues, creating shadows that can superimpose on the urinary tract structures.
- **Historical Solutions:**
  - **Patient Preparation:** Patients were often advised to undergo bowel preparation, which could include laxatives, to clear the colon.<sup>[4]</sup> However, the efficacy of this was debated, and it carried the risk of dehydrating the patient.<sup>[3]</sup>
  - **Radiographic Technique:** Taking oblique-angle radiographs could sometimes project the kidney or ureter away from the overlying bowel shadows.<sup>[2]</sup>

Q3: The collecting system (calyces, renal pelvis, and ureters) is poorly opacified or not visible at all. How can this be troubleshooted?

A3: Incomplete or non-opacification of the collecting system is a frequent problem with several potential causes:

- **Poor Renal Function:** The patient's kidneys must be able to filter and excrete the **Diodone** for the collecting system to be visualized.[1] In cases of severe renal impairment, excretion could be significantly delayed or absent.
- **Urinary Tract Obstruction:** A severe obstruction (e.g., from a kidney stone) can significantly delay the excretion of contrast medium.[5] In such cases, delayed images, sometimes up to 24 hours post-injection, were necessary to identify the site of obstruction.[5]
- **Inadequate Patient Hydration:** While severe dehydration was avoided, some level of fluid restriction was thought to help concentrate the contrast medium in the urine, leading to better opacification. Finding the right balance was key.
- **Technique:**
  - **Abdominal Compression:** A compression band was often applied over the lower abdomen after the initial radiographs. This would partially obstruct the ureters, causing the renal pelvis and calyces to distend and fill more completely with the contrast agent, improving their visualization.[3] However, compression was contraindicated in cases of severe abdominal pain, trauma, or suspected aortic aneurysm.[3]
  - **Patient Positioning:** For visualizing the distal ureters, placing the patient in a prone position could be helpful, as the iodinated contrast is heavier than urine and would gravitate to the dependent portions of the ureters.[2][5]

Q4: The entire radiograph appears blurred, lacking sharp detail of the renal outlines and collecting system. What leads to this artifact?

A4: Generalized image blur is typically a motion artifact.

- **Cause:** Any movement by the patient during the X-ray exposure, including breathing, will result in a blurred image.[3] Exposure times in early radiography were longer than today, making studies more susceptible to motion artifacts.
- **Historical Solutions:**

- Patient Instruction: Patients were instructed to hold their breath during the brief moment of X-ray exposure.
- Immobilization: In some cases, straps or other devices might have been used to help the patient remain still.

## Experimental Protocols

### Representative Protocol for Early Diodone Intravenous Pyelography (IVP)

This protocol is a synthesized representation of typical procedures from the era of **Diodone** urography, based on descriptions of intravenous pyelography.

- Patient Preparation:
  - Patients were often asked to follow a diet and take laxatives for 1-2 days prior to the examination to reduce bowel gas and feces.[4]
  - Fluid intake may have been restricted for several hours before the procedure to promote concentration of the contrast medium in the urine.
  - The patient was required to empty their bladder immediately before the procedure began. [2]
- Preliminary Radiograph:
  - A preliminary plain X-ray of the abdomen, often called a KUB (Kidneys, Ureters, Bladder), was taken before contrast injection.[2]
  - Purpose: To check the radiographic exposure settings and to visualize any radiopaque structures, like calcifications or stones, that could be obscured by the contrast medium.[3]
- Contrast Administration:
  - A sterile solution of **Diodone** (35% solution was common) was injected intravenously. The exact dosage would vary based on institutional protocols and patient weight.

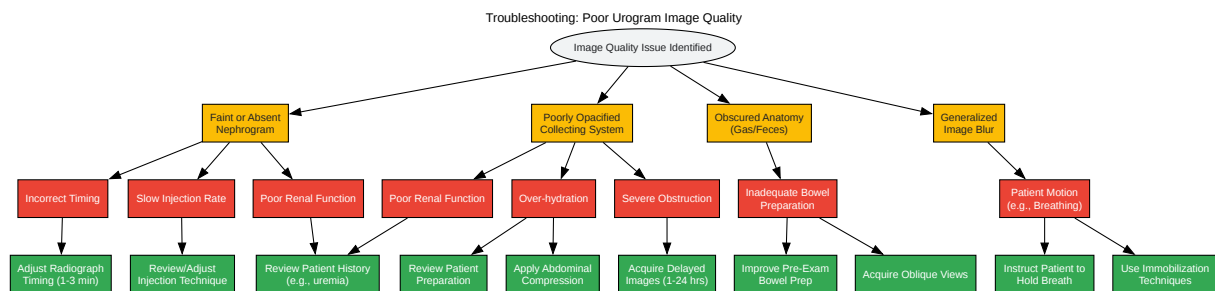
- The injection was typically administered over several minutes. A rapid bolus injection was sometimes used to improve the density of opacification.[3]
- Radiographic Series:
  - A series of X-ray images were taken at specific time intervals after the injection to capture the different phases of contrast excretion.
  - The exact timing could be adjusted based on the clinical question and the patient's condition.

Radiograph Timing (Post-Injection)	Phase Captured	Purpose
1-3 minutes	Nephrographic Phase	To assess renal parenchyma and contour.[2]
5-10 minutes	Pyelographic Phase	To visualize the calyces, renal pelvis, and upper ureters.[3]
15-20 minutes	Ureteral & Bladder Phase	To show the full course of the ureters and the filling of the bladder.[3]
Post-Micturition	Bladder Emptying	To assess bladder emptying and visualize the lower ureters without being obscured by a full bladder.[5]
Delayed (1-24 hours)	As needed for obstruction	To determine the level and severity of a urinary tract obstruction if initial images show delayed excretion.[5]

Note: Quantitative data on the frequency of specific artifacts from the era of early **Diodone** urography is not available in peer-reviewed literature. The troubleshooting advice is based on qualitative descriptions of the limitations of the technology at the time.

## Visual Troubleshooting Guides

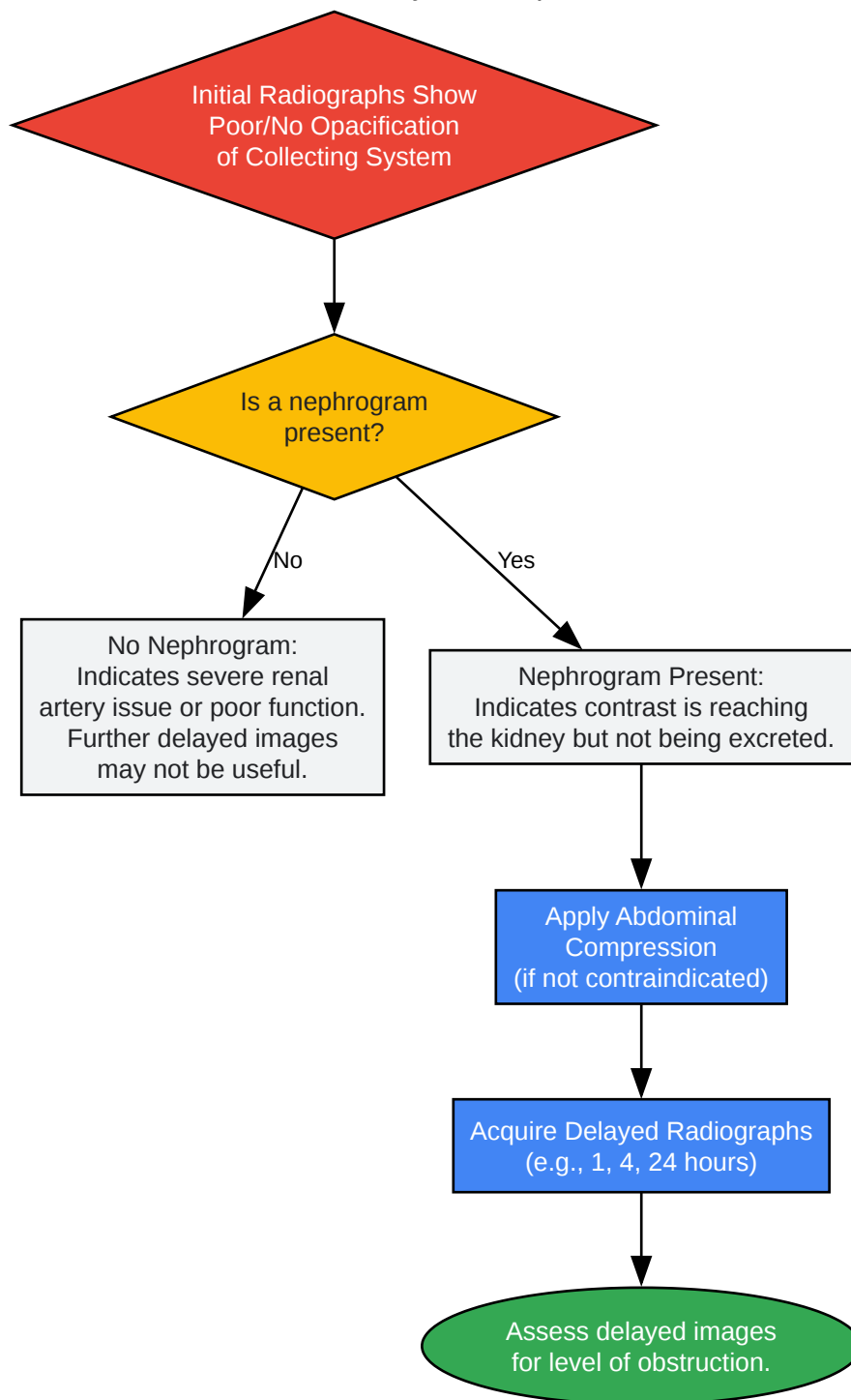
The following diagrams illustrate the logical workflow for identifying and addressing common image quality problems during early urography.



[Click to download full resolution via product page](#)

Caption: Workflow for diagnosing common image quality artifacts.

## Decision Pathway: Non-Opacification



[Click to download full resolution via product page](#)

Caption: Troubleshooting workflow for a non-opacified collecting system.

**Need Custom Synthesis?**

BenchChem offers custom synthesis for rare earth carbides and specific isotopic labeling.

Email: [info@benchchem.com](mailto:info@benchchem.com) or [Request Quote Online](#).

## References

- 1. AVID - Intravenous Urography (IVU) [vmcavid.umn.edu]
- 2. Intravenous Pyelogram - StatPearls - NCBI Bookshelf [ncbi.nlm.nih.gov]
- 3. Conventional uro-radiology with excretory urography: a forgotten art? - PMC [pmc.ncbi.nlm.nih.gov]
- 4. wecaregolp.com [wecaregolp.com]
- 5. radiopaedia.org [radiopaedia.org]
- To cite this document: BenchChem. [Image artifacts associated with early Diodone urography]. BenchChem, [2025]. [Online PDF]. Available at: [https://www.benchchem.com/product/b1670706#image-artifacts-associated-with-early-diodone-urography]

---

**Disclaimer & Data Validity:**

The information provided in this document is for Research Use Only (RUO) and is strictly not intended for diagnostic or therapeutic procedures. While BenchChem strives to provide accurate protocols, we make no warranties, express or implied, regarding the fitness of this product for every specific experimental setup.

**Technical Support:** The protocols provided are for reference purposes. Unsure if this reagent suits your experiment? [[Contact our Ph.D. Support Team for a compatibility check](#)]

**Need Industrial/Bulk Grade?** [Request Custom Synthesis Quote](#)



# BenchChem

Our mission is to be the trusted global source of essential and advanced chemicals, empowering scientists and researchers to drive progress in science and industry.

## Contact

Address: 3281 E Guasti Rd  
Ontario, CA 91761, United States  
Phone: (601) 213-4426  
Email: [info@benchchem.com](mailto:info@benchchem.com)