

# A Comparative Analysis: Revisiting Diodone-Based Imaging in Light of Modern Techniques

**Author:** BenchChem Technical Support Team. **Date:** December 2025

## Compound of Interest

Compound Name: Diodone

Cat. No.: B1670706

[Get Quote](#)

For researchers, scientists, and drug development professionals, understanding the evolution of diagnostic imaging is crucial for contextualizing historical data and appreciating the advancements that shape current research. This guide provides a detailed comparison of **Diodone**, a historical radiocontrast agent, with the modern imaging techniques that have largely superseded it, supported by available data and experimental protocols.

**Diodone**, an iodine-based, high-osmolarity contrast medium, was a cornerstone of radiological examinations such as intravenous urography and angiography for many decades.[1] Its ability to opacify blood vessels and the urinary tract provided invaluable diagnostic information. However, the advent of lower osmolarity contrast agents and advanced imaging modalities like Computed Tomography (CT), Magnetic Resonance Imaging (MRI), and nuclear scintigraphy has revolutionized the field, offering improved safety, enhanced image quality, and greater functional insights.[2] This guide cross-references the findings from the **Diodone** era with the capabilities of today's technology.

## Quantitative Comparison of Imaging Parameters

The shift from **Diodone**-based techniques to modern methods is most evident in the quantitative improvements in safety and radiation management. High-osmolarity contrast media, like **Diodone**, were associated with a higher incidence of adverse reactions compared to modern low- and iso-osmolar agents.[3],[4] Furthermore, while conventional urography was the standard, CT urography, despite its higher radiation dose, has become a primary diagnostic tool due to its superior anatomical detail.[5]

Parameter	Diodone-Based Technique (Conventional Urography/Angiography)	Modern Iodinated Contrast (LOCM/IOCM) in CT	Modern Gadolinium-Based Contrast in MRI	Modern Radiopharmaceuticals in Nuclear Medicine
Adverse Reaction Rate (Systemic)	5-12% (High-Osmolarity Class)[3]	1-3% (Low-Osmolarity Class)[3]	Generally lower than iodinated agents, but risk of Nephrogenic Systemic Fibrosis in renal impairment.	Rare, typically related to allergies.
Effective Radiation Dose (Urography)	~9.7 mSv[6]	~14.8 mSv (can be optimized)[6]	0 mSv	Varies by radiopharmaceutical (e.g., 99mTc-DTPA ~3-5 mSv)
Diagnostic Accuracy (Angiography)	Lower sensitivity and specificity for fine vascular details.	High sensitivity (approaching 100%) and specificity for coronary artery disease.[7]	High accuracy for vascular imaging without ionizing radiation.	Primarily for functional assessment (e.g., perfusion), not detailed anatomy.
Patient Comfort (Injection)	Higher incidence of pain and heat sensation due to high osmolality. [8]	Significantly improved comfort with low- and iso-osmolar agents. [9]	Generally well-tolerated.	No significant injection-site discomfort.

## Experimental Protocols: A Look Back and Forward

The methodologies for imaging have evolved significantly, reflecting technological advancements and a greater emphasis on patient safety and comfort.

# Historical Protocol: Diodone-Based Intravenous Urography (IVU)

This protocol is representative of the techniques used in the mid-20th century.

## 1. Patient Preparation:

- Patients were often required to fast for several hours to reduce bowel gas, which could obscure the urinary tract on radiographs.[\[8\]](#)
- Laxatives were sometimes administered the day before the procedure to cleanse the bowel.[\[8\]](#)
- A preliminary blood test to check renal function was necessary.
- A thorough history of allergies, particularly to iodine, was taken.[\[8\]](#)

## 2. Contrast Administration:

- A sterile solution of **Diodone** was injected intravenously.
- The injection was typically administered as a rapid bolus.[\[1\]](#)
- Dosage was often calculated based on patient weight.

## 3. Imaging Sequence:

- A plain abdominal radiograph (KUB - Kidneys, Ureters, Bladder) was taken before contrast injection to check for calcifications and assess bowel preparation.[\[10\]](#)
- A series of timed radiographs followed the injection to capture different phases of renal excretion:
  - 1-3 minutes: Nephrogram phase, showing renal parenchymal enhancement.[\[1\]](#),[\[10\]](#)
  - 5-15 minutes: Pyelogram phase, visualizing the calyces, renal pelvis, and ureters as they fill with opacified urine.[\[1\]](#),[\[11\]](#)

- Post-voiding: A final image taken after the patient emptied their bladder to assess for residual urine and bladder abnormalities.[12]
- Abdominal compression was sometimes applied to distend the upper collecting systems for better visualization.[1]

## Modern Protocol: CT Urography

### 1. Patient Preparation:

- Similar to historical protocols, patients may be asked to fast for a few hours before the exam. [13]
- Adequate hydration is encouraged.
- A blood test to assess renal function (eGFR) is standard practice.
- A detailed allergy history is crucial.

### 2. Contrast Administration:

- A low- or iso-osmolar non-ionic iodinated contrast agent is administered intravenously using a power injector at a controlled rate.
- A saline chaser is often used to ensure the full contrast dose reaches the central circulation.

### 3. Imaging Sequence:

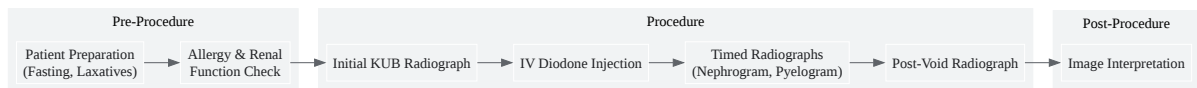
- CT urography protocols typically involve multiphasic imaging:
  - Unenhanced Phase: A low-dose scan is performed before contrast administration to detect calculi.
  - Nephrographic Phase (approx. 90-100 seconds post-injection): This phase provides optimal enhancement of the renal parenchyma, ideal for detecting renal masses.
  - Excretory (Delayed) Phase (approx. 5-15 minutes post-injection): This phase captures the excretion of contrast through the collecting systems, ureters, and bladder, providing

detailed anatomical mapping.

- 3D reconstructions and multiplanar reformats are generated from the acquired data for comprehensive evaluation.

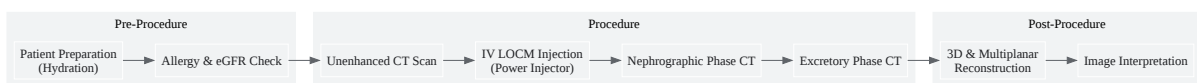
## Visualizing the Evolution of Imaging Workflows

The following diagrams illustrate the procedural flow of historical **Diodone**-based urography and modern CT urography, as well as a simplified representation of a signaling pathway potentially involved in contrast media reactions.



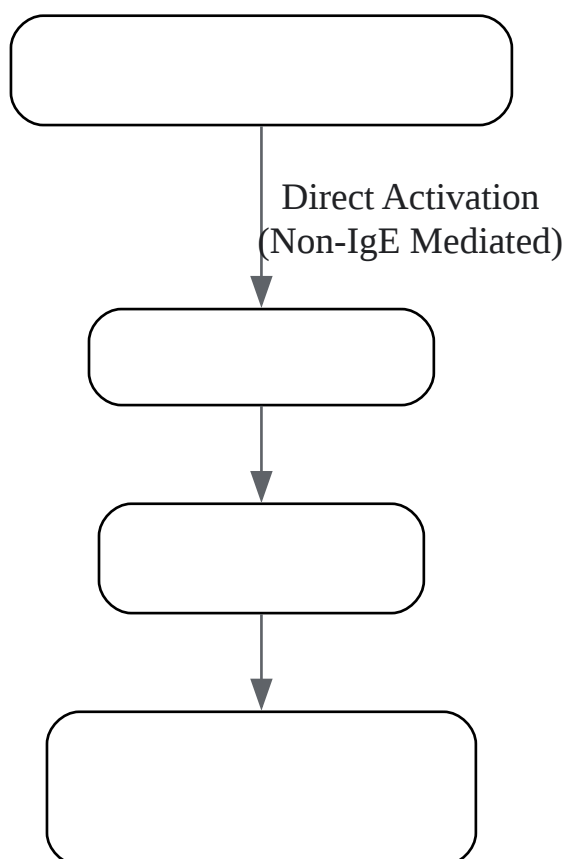
[Click to download full resolution via product page](#)

### *Historical Intravenous Urography (IVU) Workflow.*



[Click to download full resolution via product page](#)

### *Modern Computed Tomography Urography (CTU) Workflow.*



[Click to download full resolution via product page](#)

*Simplified Pathway of a Non-Allergic Contrast Reaction.*

## Conclusion

The transition from **Diodone**-based imaging to modern techniques represents a paradigm shift in diagnostic radiology. While **Diodone** was instrumental in its time, contemporary methods offer a superior safety profile, greater patient comfort, and unparalleled image detail and functional information. For researchers analyzing historical data, it is imperative to consider the limitations inherent in **Diodone**-based studies, such as lower spatial resolution and the physiological effects of high-osmolarity contrast agents. This comparative guide serves as a tool to bridge the gap between past and present, enabling a more informed interpretation of historical findings in the context of today's advanced diagnostic capabilities.

### Need Custom Synthesis?

BenchChem offers custom synthesis for rare earth carbides and specific isotopic labeling.

Email: [info@benchchem.com](mailto:info@benchchem.com) or [Request Quote Online](#).

## References

- 1. urology-textbook.com [urology-textbook.com]
- 2. INTRAVENOUS UROGRAPHY | PDF [slideshare.net]
- 3. hopkinsmedicine.org [hopkinsmedicine.org]
- 4. IVP Preparation Instructions | White-Wilson Medical Center [white-wilson.com]
- 5. my.clevelandclinic.org [my.clevelandclinic.org]
- 6. patient.info [patient.info]
- 7. Intravenous Pyelogram - StatPearls - NCBI Bookshelf [ncbi.nlm.nih.gov]
- 8. Intravenous pyelogram - Mayo Clinic [mayoclinic.org]
- 9. Urography [radiologyinfo.org]
- 10. radiopaedia.org [radiopaedia.org]
- 11. CT Urography Preparations– Southwest Medical Imaging [esmil.com]
- 12. Low-Tube-Voltage CT Urography Using Low-Concentration-Iodine Contrast Media and Iterative Reconstruction: A Multi-Institutional Randomized Controlled Trial for Comparison with Conventional CT Urography - PMC [pmc.ncbi.nlm.nih.gov]
- 13. diva-portal.org [diva-portal.org]
- To cite this document: BenchChem. [A Comparative Analysis: Revisiting Diodone-Based Imaging in Light of Modern Techniques]. BenchChem, [2025]. [Online PDF]. Available at: [https://www.benchchem.com/product/b1670706#cross-referencing-diodone-based-findings-with-modern-techniques]

---

### Disclaimer & Data Validity:

The information provided in this document is for Research Use Only (RUO) and is strictly not intended for diagnostic or therapeutic procedures. While BenchChem strives to provide accurate protocols, we make no warranties, express or implied, regarding the fitness of this product for every specific experimental setup.

**Technical Support:** The protocols provided are for reference purposes. Unsure if this reagent suits your experiment? [[Contact our Ph.D. Support Team for a compatibility check](#)]

**Need Industrial/Bulk Grade?** [Request Custom Synthesis Quote](#)

# BenchChem

Our mission is to be the trusted global source of essential and advanced chemicals, empowering scientists and researchers to drive progress in science and industry.

## Contact

Address: 3281 E Guasti Rd

Ontario, CA 91761, United States

Phone: (601) 213-4426

Email: [info@benchchem.com](mailto:info@benchchem.com)