

How to minimize the risk of retinal tears during a posterior sclerotomy.

Author: BenchChem Technical Support Team. **Date:** December 2025

Compound of Interest

Compound Name: CP-67015

Cat. No.: B1669555

[Get Quote](#)

Technical Support Center: Posterior Sclerotomy

This technical support center provides researchers, scientists, and drug development professionals with detailed guidance on minimizing the risk of retinal tears during posterior sclerotomy procedures.

Frequently Asked Questions (FAQs)

Q1: What are the primary causes of retinal tears during a posterior sclerotomy?

A1: Retinal tears during a posterior sclerotomy primarily occur due to vitreous traction at the sclerotomy site. This can be initiated by several factors during the procedure, including:

- **Improper Trocar-Cannula Insertion:** A non-beveled or perpendicular insertion can create a larger, less stable wound, increasing the risk of vitreous prolapse and subsequent traction.^[1]
- **Vitreous Incarceration:** Vitreous gel can become trapped in the sclerotomy wound upon instrument withdrawal, leading to traction on the vitreous base and potentially causing a tear.^{[2][3]} Valved cannulas can help prevent this.^[3]
- **Sudden Decompression of the Globe:** Rapid changes in intraocular pressure can cause the vitreous to shift and exert traction on the retina.
- **Pre-existing Vitreoretinal Adhesions:** In eyes with strong vitreoretinal adhesions, the mechanical stress of instrument insertion and manipulation can be transmitted to the retina,

causing a tear.[4][5][6]

Q2: What is the significance of the sclerotomy incision technique in preventing retinal tears?

A2: The incision technique is critical. A beveled or biplanar incision is preferred over a straight, perpendicular one.[1] This creates a self-sealing wound that is more stable and less prone to leakage and vitreous incarceration.[1] An oblique sclerotomy technique has also been shown to result in no intraoperative leakage after cannula removal in a series of 36 sclerotomies.

Q3: How does the choice of instrumentation affect the risk of retinal tears?

A3: Smaller gauge vitrectomy systems (23, 25, and 27-gauge) are generally associated with a lower risk of iatrogenic retinal breaks compared to the older 20-gauge systems.[7] This is due to the smaller incision size and the use of trocar-cannula systems that provide a more controlled entry and exit for instruments.[8] Valved cannulas are particularly beneficial as they minimize vitreous egress and incarceration in the sclerotomies.[3]

Q4: What is the "stop-and-slide" technique for trocar insertion?

A4: The "stop-and-slide" technique is a modification for trocar insertion, particularly useful in delicate eyes such as those in infants with retinopathy of prematurity.[9][10] The trocar is inserted only until the cannula just penetrates the sclera. The surgeon then stops and slides the cannula over the trocar into the vitreous cavity before retracting the trocar.[9][10] This technique prevents the full length of the sharp trocar from entering the eye, thereby reducing the risk of inadvertent retinal injury.[9][10] In a study of 52 eyes where this technique was used, there were no instances of iatrogenic retinal breaks during trocar insertion.[9][10]

Troubleshooting Guide

Issue	Possible Cause	Recommended Action
Vitreous Prolapse at Sclerotomy Site	Poorly constructed wound; High intraocular pressure	Create a beveled, self-sealing incision. [1] Lower the intraocular pressure before instrument withdrawal. Consider using valved cannulas to prevent vitreous egress. [3]
Observed Retinal Tear Near Sclerotomy	Vitreous traction from instrument insertion/withdrawal	Immediately address the tear with endolaser photocoagulation or cryopexy to prevent progression to retinal detachment. [11] [12] Prophylactic laser treatment posterior to sclerotomy wounds may be considered. [13]
Difficulty with Trocar Insertion	Tough sclera (e.g., in pediatric patients)	Use patience and controlled pressure. For particularly tough sclera, a two-step entry with an MVR blade followed by the cannula may be considered.
Postoperative Hypotony	Leaking sclerotomy wound	Ensure proper wound construction with a beveled incision. [1] If a leak is present, it should be sutured.

Data Presentation

Table 1: Summary of Techniques to Minimize Retinal Tear Risk During Posterior Sclerotomy

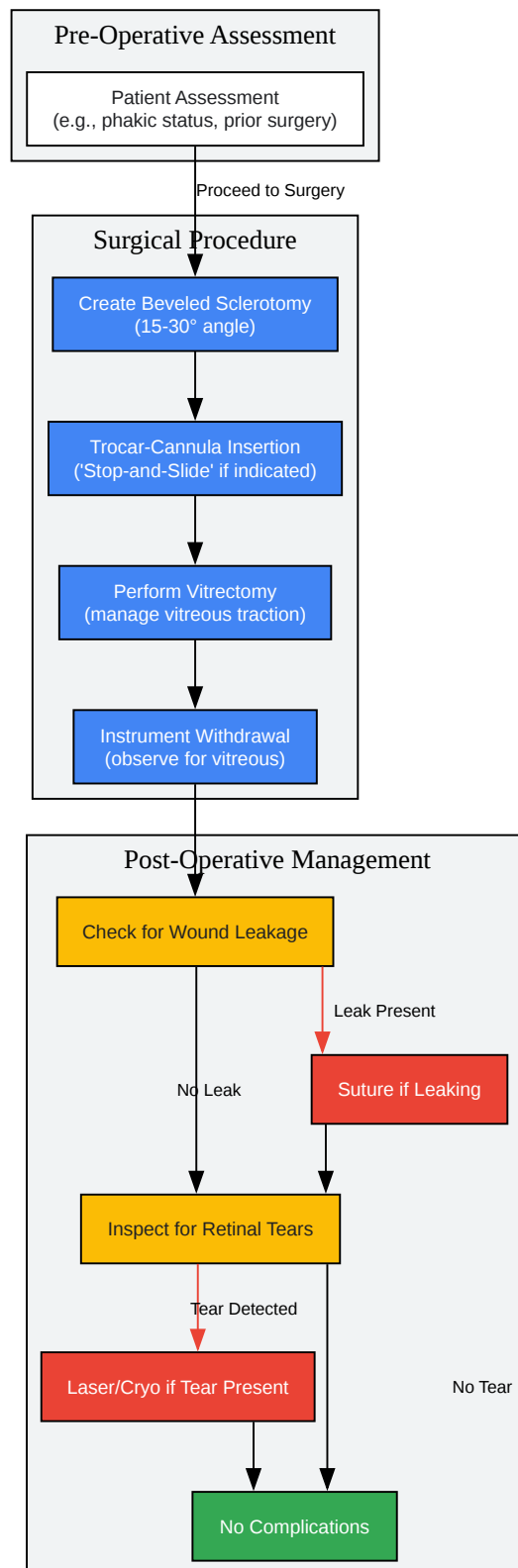
Technique/Instrument	Principle of Risk Reduction	Supporting Evidence/Rationale
Beveled/Biplanar Sclerotomy Incision	Creates a self-sealing wound, reducing vitreous incarceration and leakage.[1]	A biplanar incision is preferred as it reduces the chances of wound leak, hypotony, and gas leak, and aids in self-sealing. [1]
Small Gauge Vitrectomy (23, 25, 27g)	Smaller incisions cause less trauma to the sclera and vitreous base.	Microincision vitrectomy surgery (MIVS) is preferred for retinal detachments as the port cannulae minimize the chance of retinal incarceration.[2]
Trocar-Cannula System	Provides a protected and stable entry point for instruments, minimizing direct scleral injury.[8]	The cannula protects the sclera from direct injury by the instruments.[8]
Valved Cannulas	Prevents the egress of vitreous through the cannulas during instrument exchange, reducing the risk of vitreous incarceration.[3]	Valved cannulae may prevent vitreous egress through the cannulae and incarceration in the sclerotomies.[3]
"Stop-and-Slide" Trocar Insertion	Limits the intraocular penetration of the sharp trocar, preventing inadvertent retinal damage.[9][10]	In a series of 52 pediatric eyes, this technique resulted in no iatrogenic retinal breaks.[9][10]
Management of Vitreous Traction	Releasing vitreous traction is key to preventing tears.	A posterior vitreous detachment (PVD) should be ensured or induced.[2]
Controlled Intraocular Pressure	Avoids sudden shifts in the vitreous that can cause traction.	Lowering the IOP during peripheral vitreous shaving makes scleral indentation easier and safer.[14]

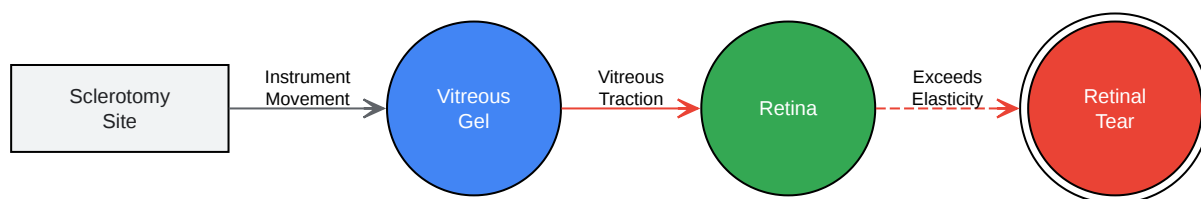
Experimental Protocols

Protocol 1: Beveled Trocar-Cannula Insertion for Posterior Sclerotomy

- **Preparation:** Ensure adequate anesthesia and asepsis. Position the eye and stabilize it with forceps.
- **Sclerotomy Site Selection:** Mark the sclerotomy sites, typically 3.0-3.5 mm posterior to the limbus in pseudophakic/aphakic eyes and 3.5-4.0 mm in phakic eyes.[3]
- **Conjunctival Displacement:** Displace the conjunctiva over the intended sclerotomy site.
- **Trocar Insertion Angle:** Insert the trocar-cannula at a 15-30 degree angle to the scleral surface to create a beveled incision.
- **Biplanar Entry:** Advance the trocar parallel to the scleral surface for approximately 1.5-2.0 mm, then change the angle to perpendicular to the sclera to enter the vitreous cavity.
- **Cannula Placement:** Ensure the cannula is fully seated in the sclera.
- **Instrument Exchange:** When using non-valved cannulas, place a plug in the cannula during instrument exchange to prevent vitreous prolapse. With valved cannulas, this is not necessary.[3]
- **Cannula Removal:** At the conclusion of the procedure, gently remove the cannulas while observing for any vitreous incarceration. If present, it should be excised.
- **Wound Closure:** The self-sealing nature of the beveled incision should prevent leakage. If leakage is observed, a suture should be placed.

Mandatory Visualization





[Click to download full resolution via product page](#)

Need Custom Synthesis?

BenchChem offers custom synthesis for rare earth carbides and specific isotopic labeling.

Email: info@benchchem.com or [Request Quote Online](#).

References

- 1. actascientific.com [actascientific.com]
- 2. vrsurgeryonline.com [vrsurgeryonline.com]
- 3. vrsurgeryonline.com [vrsurgeryonline.com]
- 4. Managing vitreomacular traction | Ophthalmology Management [ophthalmologymanagement.com]
- 5. reviewofophthalmology.com [reviewofophthalmology.com]
- 6. A Review of Current Management of Vitreomacular Traction and Macular Hole - PMC [pmc.ncbi.nlm.nih.gov]
- 7. Know Your Retinal Surgery Toolbox | Retinal Physician [retinalphysician.com]
- 8. eophtha.com [eophtha.com]
- 9. 'Stop-and-Slide' technique for trocar insertion during lens-sparing vitrectomy for retinopathy of prematurity - PMC [pmc.ncbi.nlm.nih.gov]
- 10. researchgate.net [researchgate.net]
- 11. Procedures to Treat Retinal Tears & Retinal Detachments | NYU Langone Health [nyulangone.org]
- 12. droracle.ai [droracle.ai]

- 13. Prophylactic Laser Treatment Posterior to Pars Plana Vitrectomy Sclerotomy Wounds During Macular Surgery - PubMed [pubmed.ncbi.nlm.nih.gov]
- 14. assets.bmctoday.net [assets.bmctoday.net]
- To cite this document: BenchChem. [How to minimize the risk of retinal tears during a posterior sclerotomy.]. BenchChem, [2025]. [Online PDF]. Available at: [https://www.benchchem.com/product/b1669555#how-to-minimize-the-risk-of-retinal-tears-during-a-posterior-sclerotomy]

Disclaimer & Data Validity:

The information provided in this document is for Research Use Only (RUO) and is strictly not intended for diagnostic or therapeutic procedures. While BenchChem strives to provide accurate protocols, we make no warranties, express or implied, regarding the fitness of this product for every specific experimental setup.

Technical Support: The protocols provided are for reference purposes. Unsure if this reagent suits your experiment? [[Contact our Ph.D. Support Team for a compatibility check](#)]

Need Industrial/Bulk Grade? [Request Custom Synthesis Quote](#)

BenchChem

Our mission is to be the trusted global source of essential and advanced chemicals, empowering scientists and researchers to drive progress in science and industry.

Contact

Address: 3281 E Guasti Rd

Ontario, CA 91761, United States

Phone: (601) 213-4426

Email: info@benchchem.com