

# "minimizing artifacts in iodocholesterol-based imaging experiments"

**Author:** BenchChem Technical Support Team. **Date:** December 2025

## Compound of Interest

Compound Name: *Iodocholesterol*

Cat. No.: *B1628986*

[Get Quote](#)

## Technical Support Center: Iodocholesterol-Based Imaging

This technical support center provides troubleshooting guides and frequently asked questions (FAQs) to help researchers, scientists, and drug development professionals minimize artifacts in **iodocholesterol**-based imaging experiments, particularly those using <sup>131</sup>I-6 $\beta$ -iodomethyl-19-norcholesterol (NP-59).

## Frequently Asked Questions (FAQs) & Troubleshooting Guides

Q1: What are the most common sources of artifacts in **iodocholesterol** imaging?

A1: Artifacts in **iodocholesterol** imaging can be broadly categorized as patient-related, technical, or radiopharmaceutical-related.[1][2] The most frequently encountered artifacts include:

- **Bowel Activity:** The liver excretes radio-labeled cholesterol derivatives, which then appear in the colon, potentially obscuring the adrenal glands.[3][4]
- **Patient Motion:** Movement during image acquisition can lead to blurred or misaligned images, reducing diagnostic accuracy.[1]

- **Soft Tissue Attenuation:** The gamma rays emitted by the radiotracer can be absorbed or scattered by overlying soft tissues, leading to artificially reduced counts in certain areas.[1]
- **Radiopharmaceutical Extravasation:** If the radiotracer is not properly injected into the vein, it can accumulate at the injection site, leading to artifacts.[2]
- **Contamination:** External contamination of the patient or equipment with the radiotracer can create false hot spots.[2]

Q2: How can I minimize interference from bowel activity on my adrenal scintigraphy images?

A2: Minimizing bowel activity is crucial for clear visualization of the adrenal glands. A simple and effective method is to implement a bowel preparation protocol. The use of a mild laxative, such as bisacodyl, has been shown to significantly reduce background activity from the bowel. [3][4] One study demonstrated that with bisacodyl, interfering activity was present less frequently three days post-injection (22% vs. 59% without) and five days post-injection (23% vs. 35% without).[3][4]

Q3: What is the purpose of dexamethasone suppression in NP-59 imaging protocols?

A3: Dexamethasone suppression is a critical step in many **iodocholesterol** imaging protocols, particularly for differentiating between different types of adrenal lesions.[5][6] Dexamethasone suppresses the pituitary-adrenal axis, reducing the uptake of NP-59 in normal adrenal tissue.[5][7] This enhances the visualization of adrenal tumors that are not under the control of this axis, such as aldosterone-producing adenomas.[5][8]

Q4: My images are blurry and the adrenal glands are difficult to delineate. What could be the cause and how can I fix it?

A4: Blurry images are often a result of patient motion during the scan.[1] To mitigate this, it is important to ensure the patient is comfortable and well-informed about the need to remain still during the imaging procedure.[1] Additionally, using SPECT (Single Photon Emission Computed Tomography) or SPECT/CT imaging can help to improve image resolution and reduce the impact of motion artifacts compared to planar imaging.[6][7]

Q5: I am observing asymmetric uptake in the adrenal glands. How do I interpret this?

A5: Asymmetrical uptake can be indicative of a unilateral adrenal adenoma.[8] However, it can also be observed in patients with macronodules in cases of Primary Pigmented Nodular Adrenocortical Disease (PPNAD).[9] The interpretation of asymmetric uptake should always be done in conjunction with clinical and biochemical findings.[10] SPECT/CT can be particularly useful in these cases to provide both functional and anatomical information, helping to differentiate between adenomas and nodular hyperplasia.[6]

Q6: Can medications or patient conditions affect the uptake of **iodocholesterol**?

A6: Yes, several factors can influence the biodistribution of **iodocholesterol**. For instance, hypercholesterolemia has been shown to decrease the adrenal uptake of NP-59.[11] Additionally, various antihypertensive medications, such as glucocorticoids, diuretics, and spironolactone, should be discontinued for a period before the study as they can interfere with the results.[7]

## Data Presentation

Table 1: Efficacy of Bowel Preparation with Bisacodyl in Reducing Interfering Bowel Activity in NP-59 Scintigraphy

Days After Injection	Percentage of Patients with Interfering Activity (With Bisacodyl)	Percentage of Patients with Interfering Activity (Without Bisacodyl)
3	22%	59%
5	23%	35%

Source: Adapted from Shapiro B, Nakajo M, Gross MD, et al. J Nucl Med. 1983.[3][4]

Table 2: Diagnostic Accuracy of NP-59 Imaging in Primary Aldosteronism

Imaging Modality	Sensitivity	Specificity	Positive Predictive Value	Negative Predictive Value	Accuracy
NP-59 Planar Imaging	-	-	-	-	-
NP-59 SPECT/CT	85.0%	60.0%	89.5%	-	Significantly improved vs. planar

Source: Adapted from Wu MH, et al. and Chen YC, et al.[5][7]

## Experimental Protocols

### Protocol 1: Patient Preparation for NP-59 Adrenal Scintigraphy

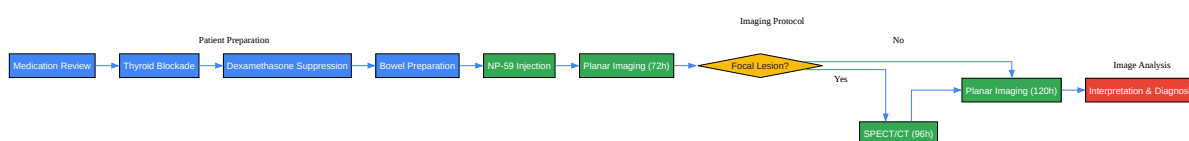
This protocol is a general guideline and may need to be adapted based on institutional policies and specific clinical indications.

- **Medication Review:** Discontinue interfering medications such as glucocorticoids, diuretics, spironolactone,  $\beta$ -blockers, and calcium channel blockers for at least 3 weeks prior to the study.[7]
- **Thyroid Blockade:** Administer a Lugol's solution (1 mL daily) for 3 days before and 5 days after the NP-59 injection to block thyroidal uptake of free  $^{131}\text{I}$ .[7]
- **Dexamethasone Suppression (if indicated):** For differentiating certain adrenal pathologies, administer oral dexamethasone (e.g., 8 mg daily in divided doses) for 3 days before and 5 days after the NP-59 injection.[7]
- **Bowel Preparation:** To reduce background activity, administer a mild laxative (e.g., bisacodyl 5 or 10 mg nightly) starting the evening before the NP-59 injection and continuing until imaging is complete.[3][4]

### Protocol 2: NP-59 SPECT/CT Imaging

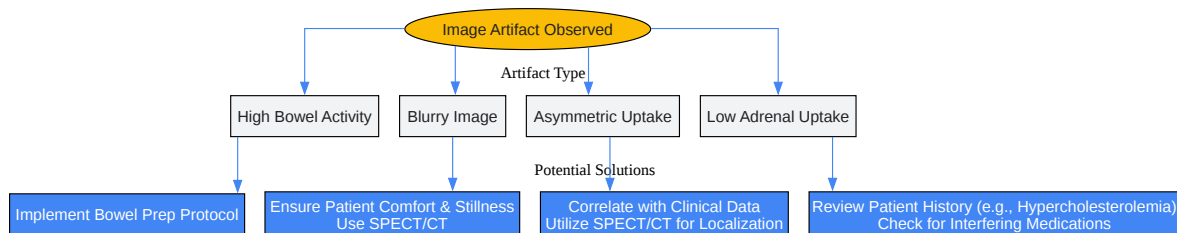
- Radiotracer Administration: Administer 37 MBq (1 mCi) of NP-59 via a slow intravenous injection.[7]
- Imaging Schedule:
  - Acquire initial anterior and posterior planar images at 72 hours post-injection.[7]
  - If a focal lesion is identified, proceed with SPECT/CT.[7]
  - Repeat planar imaging and SPECT/CT at 96 hours post-injection.[7]
  - Acquire final anterior and posterior planar images at 120 hours post-injection.[7]
- SPECT/CT Acquisition Parameters: Specific acquisition parameters will vary depending on the equipment used. It is essential to follow the manufacturer's recommendations and institutional protocols for optimal image quality.

## Mandatory Visualization



[Click to download full resolution via product page](#)

Caption: Workflow for **Iodocholesterol**-Based Imaging Experiments.



[Click to download full resolution via product page](#)

### Need Custom Synthesis?

BenchChem offers custom synthesis for rare earth carbides and specific isotopic labeling.

Email: [info@benchchem.com](mailto:info@benchchem.com) or [Request Quote Online](#).

## References

- 1. Recognizing and preventing artifacts with SPECT and PET imaging | Radiology Key [radiologykey.com]
- 2. Nuclear Medicine Artifacts - StatPearls - NCBI Bookshelf [ncbi.nlm.nih.gov]
- 3. Value of bowel preparation in adrenocortical scintigraphy with NP-59 - PubMed [pubmed.ncbi.nlm.nih.gov]
- 4. Value of bowel preparation in adrenocortical scintigraphy with NP-59 (Journal Article) | OSTI.GOV [osti.gov]
- 5. Diagnostic value of adrenal iodine-131 6-beta-iodomethyl-19-norcholesterol scintigraphy for primary aldosteronism: a retrospective study at a medical center in North Taiwan - PMC [pmc.ncbi.nlm.nih.gov]
- 6. hkjr.org [hkjr.org]
- 7. jnm.snmjournals.org [jnm.snmjournals.org]

- 8. Adrenal imaging with 131I-19-iodocholesterol in the diagnostic evaluation of patients with aldosteronism - PubMed [pubmed.ncbi.nlm.nih.gov]
- 9. Hormonal, Radiological, NP-59 Scintigraphy, and Pathological Correlations in Patients With Cushing's Syndrome Due to Primary Pigmented Nodular Adrenocortical Disease (PPNAD) - PubMed [pubmed.ncbi.nlm.nih.gov]
- 10. jnm.snmjournals.org [jnm.snmjournals.org]
- 11. The influence of hypercholesterolaemia on the adrenal uptake and metabolic handling of 131I-6 beta-iodomethyl-19-norcholesterol (NP-59) - PubMed [pubmed.ncbi.nlm.nih.gov]
- To cite this document: BenchChem. ["minimizing artifacts in iodocholesterol-based imaging experiments"]. BenchChem, [2025]. [Online PDF]. Available at: [https://www.benchchem.com/product/b1628986#minimizing-artifacts-in-iodocholesterol-based-imaging-experiments]

---

#### Disclaimer & Data Validity:

The information provided in this document is for Research Use Only (RUO) and is strictly not intended for diagnostic or therapeutic procedures. While BenchChem strives to provide accurate protocols, we make no warranties, express or implied, regarding the fitness of this product for every specific experimental setup.

**Technical Support:** The protocols provided are for reference purposes. Unsure if this reagent suits your experiment? [[Contact our Ph.D. Support Team for a compatibility check](#)]

**Need Industrial/Bulk Grade?** [Request Custom Synthesis Quote](#)

## BenchChem

Our mission is to be the trusted global source of essential and advanced chemicals, empowering scientists and researchers to drive progress in science and industry.

#### Contact

Address: 3281 E Guasti Rd  
Ontario, CA 91761, United States  
Phone: (601) 213-4426  
Email: [info@benchchem.com](mailto:info@benchchem.com)