

Histopathological Changes in the Gut Associated with Cannabinoid Hyperemesis Syndrome: A Technical Guide

Author: BenchChem Technical Support Team. **Date:** December 2025

Compound of Interest

Compound Name: CHS-111

Cat. No.: B15615455

[Get Quote](#)

For Researchers, Scientists, and Drug Development Professionals

Abstract

Cannabinoid Hyperemesis Syndrome (CHS) is a paradoxical condition characterized by cyclical nausea, vomiting, and abdominal pain in chronic cannabis users. While the systemic pathophysiology involving the endocannabinoid system is increasingly understood, the specific histopathological changes within the gastrointestinal tract remain poorly defined. This technical guide synthesizes the available, albeit limited, evidence on the gut histopathology in CHS, provides detailed experimental protocols for future investigations, and visualizes the key signaling pathways implicated in the syndrome's gastrointestinal manifestations. Current literature, primarily based on case reports, suggests that the histopathological findings in the gut of CHS patients are often minimal and nonspecific, typically characterized as "mild gastritis" or "mild inflammation" with an otherwise "unrevealing histology". This guide aims to provide a comprehensive resource for researchers and clinicians to standardize future investigations into the gut pathology of CHS, facilitating a deeper understanding of the disease and the identification of potential therapeutic targets.

Introduction

Cannabinoid Hyperemesis Syndrome (CHS) presents a clinical enigma, as cannabis is well-known for its antiemetic properties. The syndrome is defined by a history of chronic cannabis

use, recurrent episodes of severe nausea and vomiting, and the characteristic learned behavior of compulsive hot water bathing for symptom relief. The pathophysiology is thought to involve the complex dose-dependent and chronic-exposure effects of cannabinoids on the endocannabinoid system (ECS), which plays a crucial role in regulating gut motility, nausea, and vomiting. While systemic mechanisms are the primary focus of current research, a thorough understanding of the local tissue-level changes in the gut is essential for a complete picture of the syndrome and for the development of targeted therapies.

Endoscopic examinations of CHS patients are often performed to rule out other causes of nausea and vomiting, and biopsies are frequently collected. However, detailed histopathological analyses of these biopsies are rarely reported in the literature. This guide addresses this gap by summarizing the existing qualitative data, presenting standardized protocols for future research, and outlining the relevant signaling pathways.

Qualitative Histopathological Findings in the Gut

The available literature on the histopathology of the gut in CHS is sparse and consists mainly of case reports. A consistent finding across these reports is the lack of significant or pathognomonic histological abnormalities.

- **Gastric Mucosa:** The most frequently reported finding in gastric biopsies of CHS patients is "mild gastritis". In some cases, the histology is described as entirely "unrevealing". This "mild gastritis" is typically characterized by a slight increase in chronic inflammatory cells, such as lymphocytes and plasma cells, in the lamina propria. Features of active inflammation, such as neutrophils infiltrating the epithelium or forming crypt abscesses, are generally absent. Significant architectural distortion, atrophy, or metaplasia are not typically associated with CHS.
- **Esophageal Mucosa:** Esophageal biopsies in one case series revealed "mild inflammation". This is a nonspecific finding that could be attributed to various factors, including gastroesophageal reflux, which can be secondary to recurrent vomiting.
- **Duodenal and Colonic Mucosa:** There is a notable lack of reports on the histopathological findings in the small and large intestines of CHS patients. The focus of the limited existing literature has been on the upper gastrointestinal tract.

In summary, the current evidence suggests that CHS is not associated with a distinct, severe inflammatory or damaging histopathological phenotype in the gut mucosa. The observed changes are mild and nonspecific, which may suggest that the gastrointestinal symptoms are primarily driven by functional rather than structural alterations at the mucosal level.

Quantitative Data on Histopathological Changes

A systematic review of the literature reveals a significant absence of quantitative studies on the histopathological changes in the gut associated with CHS. To date, no studies have been published that provide specific cell counts, measurements of mucosal thickness, or other quantitative morphometric analyses of gut biopsies from CHS patients. The table below summarizes the lack of available quantitative data for key histopathological parameters.

Histopathological Parameter	Finding in CHS Patients	Source(s)
Inflammatory Cell Infiltrate (Neutrophils, Eosinophils, Lymphocytes, Mast Cells)	No quantitative data available. Described qualitatively as "mild" or "slight increase" in chronic inflammatory cells.	
Epithelial Damage (Erosion, Ulceration, Apoptosis)	No quantitative data available. Generally reported as absent.	
Crypt Architecture (Distortion, Atrophy)	No quantitative data available. Generally reported as normal.	
Mucosal Thickness	No quantitative data available.	
Goblet Cell Density	No quantitative data available.	
Enteroendocrine Cell Counts	No quantitative data available.	

This lack of quantitative data represents a critical gap in our understanding of CHS and highlights the need for systematic, controlled studies employing standardized histopathological scoring and morphometric analysis.

Experimental Protocols

To facilitate standardized future research, this section provides detailed methodologies for the histological and immunohistochemical analysis of gut biopsies.

Tissue Collection and Processing

- **Biopsy Acquisition:** Obtain endoscopic biopsies from the gastric antrum, gastric body, duodenum, and colon.
- **Fixation:** Immediately fix biopsies in 10% neutral buffered formalin for 18-24 hours at room temperature.
- **Processing:** Dehydrate the fixed tissue through a series of graded ethanol solutions, clear with xylene, and embed in paraffin wax.
- **Sectioning:** Cut 4-5 μm thick sections using a microtome and mount on positively charged glass slides.

Hematoxylin and Eosin (H&E) Staining

- **Deparaffinization and Rehydration:**
 - Xylene: 2 changes, 5 minutes each.
 - 100% Ethanol: 2 changes, 3 minutes each.
 - 95% Ethanol: 1 change, 3 minutes.
 - 70% Ethanol: 1 change, 3 minutes.
 - Running tap water: 5 minutes.
- **Staining:**
 - Harris's Hematoxylin: 5 minutes.
 - Running tap water: 5 minutes.
 - 0.3% Acid Alcohol: 3-5 dips.

- Running tap water: 5 minutes.
- Scott's Tap Water Substitute: 1 minute.
- Running tap water: 2 minutes.
- Eosin Y: 1-2 minutes.
- Dehydration and Mounting:
 - 95% Ethanol: 2 changes, 3 minutes each.
 - 100% Ethanol: 2 changes, 3 minutes each.
 - Xylene: 2 changes, 3 minutes each.
 - Mount with a permanent mounting medium.

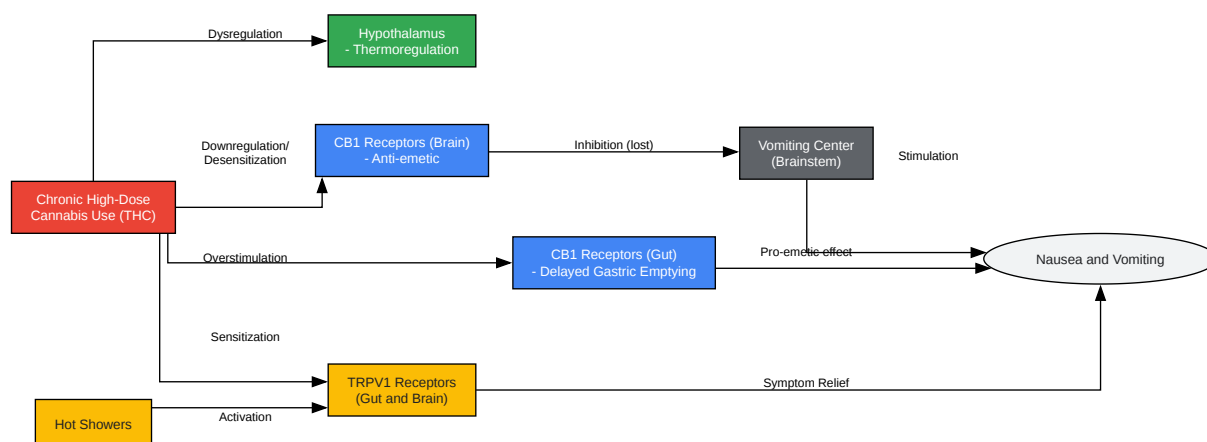
Immunohistochemistry (IHC) for CB1 and TRPV1 Receptors

- Deparaffinization and Rehydration: As described for H&E staining.
- Antigen Retrieval: Perform heat-induced epitope retrieval using a citrate buffer (pH 6.0) or EDTA buffer (pH 9.0) in a pressure cooker or water bath at 95-100°C for 20-30 minutes. Allow slides to cool to room temperature.
- Peroxidase Block: Incubate sections in 3% hydrogen peroxide for 10 minutes to block endogenous peroxidase activity. Rinse with phosphate-buffered saline (PBS).
- Blocking: Incubate sections with a protein block (e.g., 5% normal goat serum in PBS) for 30-60 minutes to prevent nonspecific antibody binding.
- Primary Antibody Incubation: Incubate sections with primary antibodies against CB1 and TRPV1 (diluted according to manufacturer's instructions) overnight at 4°C in a humidified chamber.
- Secondary Antibody and Detection:

- Rinse with PBS.
- Incubate with a biotinylated secondary antibody for 30-60 minutes.
- Rinse with PBS.
- Incubate with a streptavidin-horseradish peroxidase (HRP) conjugate for 30 minutes.
- Rinse with PBS.
- Chromogen Development: Apply diaminobenzidine (DAB) chromogen and monitor for color development under a microscope.
- Counterstaining, Dehydration, and Mounting: Counterstain with hematoxylin, dehydrate, and mount as described for H&E staining.

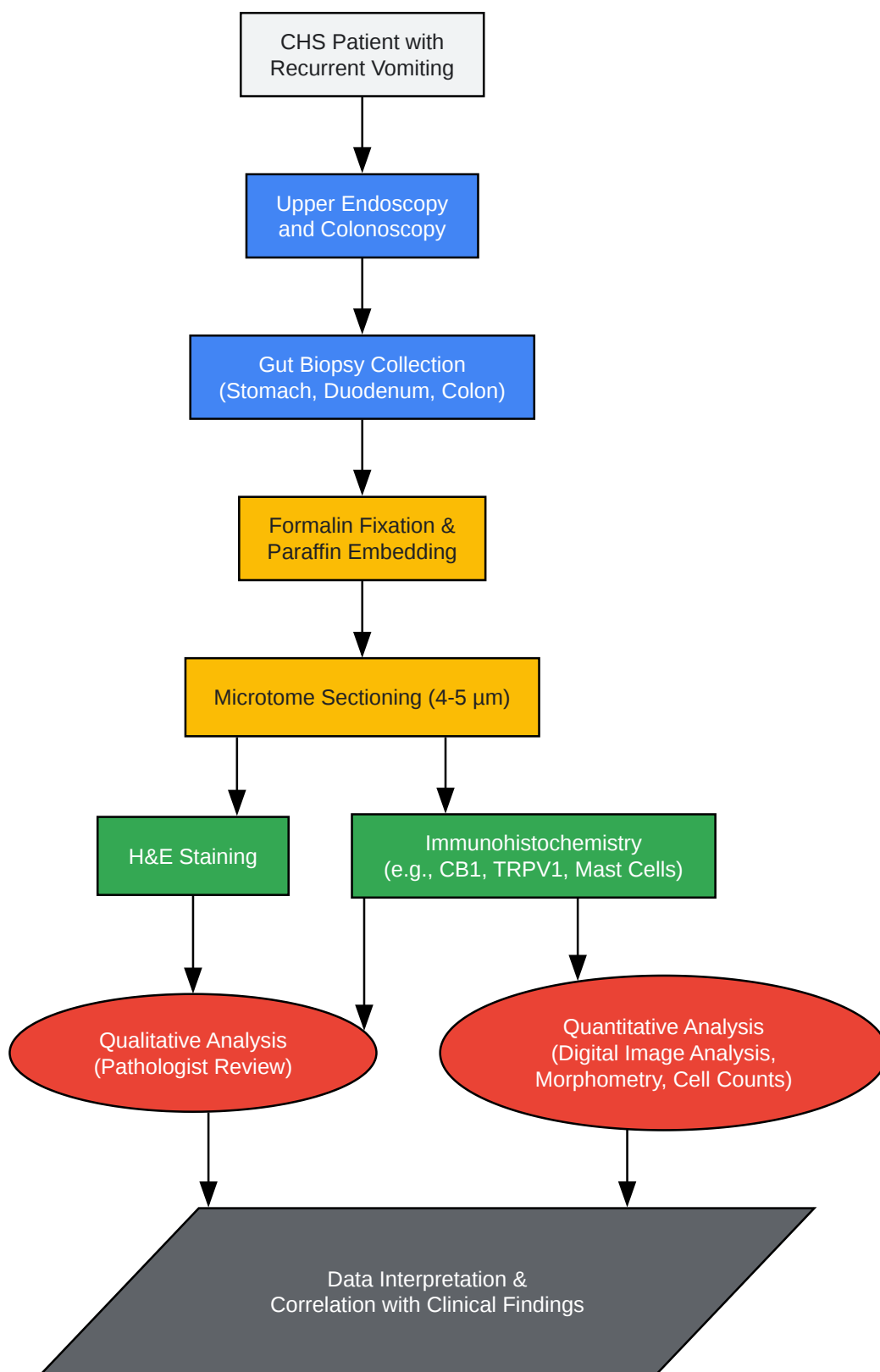
Signaling Pathways and Experimental Workflows

While the direct histopathological evidence in the gut is limited, the systemic pathophysiology of CHS is thought to involve the dysregulation of cannabinoid and other receptor systems. The following diagrams illustrate these hypothesized pathways and a general workflow for investigating the histopathology of CHS.



[Click to download full resolution via product page](#)

Caption: Hypothesized signaling pathways in CHS.



[Click to download full resolution via product page](#)

Caption: Experimental workflow for CHS gut histopathology.

Conclusion and Future Directions

The current understanding of the histopathological changes in the gut associated with CHS is limited, with available evidence pointing towards nonspecific, mild inflammatory changes. This suggests that the severe gastrointestinal symptoms of CHS may be primarily driven by neurogenic and functional alterations within the gut-brain axis rather than by significant mucosal injury. The lack of quantitative data is a major gap in the field.

Future research should focus on:

- **Prospective, controlled studies:** Systematically collecting and analyzing gut biopsies from a well-characterized cohort of CHS patients and appropriate control groups.
- **Quantitative morphometric analysis:** Employing digital pathology and automated image analysis to obtain objective, quantitative data on cell populations, mucosal architecture, and the expression of key receptors like CB1 and TRPV1.
- **Molecular and genetic studies:** Investigating gene expression profiles and genetic polymorphisms in gut tissue to identify potential susceptibility factors and novel therapeutic targets.

By adopting standardized protocols and focusing on quantitative and molecular analyses, the research community can move beyond the current descriptive and often "unrevealing" findings to a more precise understanding of the gut's role in the pathophysiology of Cannabinoid Hyperemesis Syndrome. This will be instrumental in the development of effective, targeted therapies for this challenging condition.

- **To cite this document:** BenchChem. [Histopathological Changes in the Gut Associated with Cannabinoid Hyperemesis Syndrome: A Technical Guide]. BenchChem, [2025]. [Online PDF]. Available at: [<https://www.benchchem.com/product/b15615455#histopathological-changes-in-the-gut-associated-with-chs>]

Disclaimer & Data Validity:

The information provided in this document is for Research Use Only (RUO) and is strictly not intended for diagnostic or therapeutic procedures. While BenchChem strives to provide

accurate protocols, we make no warranties, express or implied, regarding the fitness of this product for every specific experimental setup.

Technical Support: The protocols provided are for reference purposes. Unsure if this reagent suits your experiment? [[Contact our Ph.D. Support Team for a compatibility check](#)]

Need Industrial/Bulk Grade? [Request Custom Synthesis Quote](#)

BenchChem

Our mission is to be the trusted global source of essential and advanced chemicals, empowering scientists and researchers to drive progress in science and industry.

Contact

Address: 3281 E Guasti Rd
Ontario, CA 91761, United States
Phone: (601) 213-4426
Email: info@benchchem.com