

Comparative Assessment of Hemostatic Agents for Liver Tissue: A Pathological Perspective

Author: BenchChem Technical Support Team. **Date:** December 2025

Compound of Interest

Compound Name: *Ferric sulfate*

Cat. No.: *B154349*

[Get Quote](#)

For Immediate Release

In the critical landscape of surgical hemostasis, particularly in the context of hepatic procedures, the choice of a hemostatic agent carries significant implications for patient outcomes. This guide provides a comprehensive comparison of **ferric sulfate** with other leading hemostatic alternatives, focusing on their pathological impact on liver tissue. Intended for researchers, scientists, and drug development professionals, this document synthesizes experimental data to offer an objective analysis of performance, supported by detailed methodologies and quantitative comparisons.

Executive Summary

Effective hemostasis in liver surgery is a paramount challenge due to the organ's high vascularity and friable parenchyma. While traditional methods like suturing are often employed, a variety of topical hemostatic agents have been developed to provide more rapid and efficient bleeding control. This guide delves into the pathological assessment of liver tissue following the application of **ferric sulfate** and compares its effects with those of other prevalent agents, including gelatin-thrombin matrices, collagen-thrombin powders, and fibrin sealants. The comparative analysis is based on key performance indicators such as hemostasis time and blood loss, alongside a microscopic examination of the tissue response, including inflammation, necrosis, and granulation tissue formation.

Hemostatic Performance: A Quantitative Comparison

The efficacy of a hemostatic agent is primarily determined by its ability to rapidly control bleeding and minimize blood loss. Experimental studies in animal models provide crucial quantitative data to compare these parameters across different agents.

| Hemostatic Agent | Animal Model | Hemostasis Time (seconds) | Blood Loss | Source |
|----------------------------------|--------------|---|---|--------|
| Ferric Sulfate (50%) | Rat | 8 ± 2.16 | Not Reported | [1] |
| Ferric Sulfate (25%) | Rat | 14.5 ± 3.4 | Not Reported | [1] |
| Ferric Sulfate (15%) | Rat | 23.2 ± 4.75 | Not Reported | [1] |
| Zinc Chloride (50%) | Rat | 15.80 ± 1.75 | Not Reported | [2] |
| Simple Suture | Rat | 89.9 ± 7.41 | Not Reported | [1] |
| Gelatin-Thrombin Matrix (Smooth) | Porcine | Significantly lower than PCCT at all time points | Significantly lower than PCCT at all time points | [3][4] |
| Collagen-Thrombin Powder (PCCT) | Porcine | Significantly higher than SmGM at all time points | Significantly higher than SmGM at all time points | [3][4] |
| Fibrin Sealant | Rat | Shorter than primary suture | Less than primary suture | [5][6] |
| Ankaferd Blood Stopper (ABS) | Rat | Lower than OC and CA | Lowest among ABS, OC, and CA | [7] |
| Oxidized Cellulose (OC) | Rat | Higher than ABS | Higher than ABS | [7] |
| Calcium Alginate (CA) | Rat | Higher than ABS and OC | Higher than ABS and OC | [7] |

Pathological Assessment of Liver Tissue

The ideal hemostatic agent should not only be effective in controlling bleeding but also be biocompatible, causing minimal tissue damage and promoting normal wound healing. The following table summarizes the pathological findings associated with different hemostatic agents.

| Hemostatic Agent | Inflammation | Necrosis | Granulation Tissue | Other Findings | Source |
|------------------------------|---|---|---|--|---------------|
| Ferric Sulfate | Minor to mild inflammatory infiltration at lower concentrations; moderate inflammation with neutrophils at higher concentrations.[1][8] | Not explicitly quantified, but acidic nature causes protein coagulation.[9][10] | Not explicitly detailed. | Creates a barrier of coagulated proteins.[9][10] | [1][8][9][10] |
| Simple Suture | Mild to moderate inflammatory infiltration.[1] | Can cause parenchymal and ischemic injury.[11] | Not explicitly detailed. | Risk of exacerbating liver rupture and causing more tissue injury.[11] | [1][11] |
| Fibrin Sealant | Less inflammation compared to primary suture.[5][6] | Less tissue damage compared to suture.[5][6] | Promotes better wound healing and regeneration.[5][6] | Causes fewer intra-abdominal adhesions.[5][6] | [5][6] |
| Ankaferd Blood Stopper (ABS) | Higher scores than CA and OC, but not statistically significant.[7] | Significantly less necrosis than OC.[7] | Higher scores than CA and OC, but not statistically significant.[7] | Triggers protein agglutination cascade.[7] | [7] |
| Oxidized Cellulose (OC) | Significantly different inflammatory status | More necrosis than ABS.[7] | No significant difference between groups.[7] | Functions through hydrophobic effects.[7] | [7] |

compared to

CA.[7]

Liquid form:

Dense fibrous

tissue

capsule.

Algan

Hemostatic

Agent (AHA)

Powder form:

Moderate

lymphocyte

infiltration.

[12]

Not reported.

Powder form:

Late

granulation

tissue

observed.[12]

Powder form

showed some [12]

remnants.[12]

Experimental Protocols

A standardized experimental protocol is crucial for the valid comparison of hemostatic agents. The following outlines a typical methodology used in the cited animal studies.

Animal Model and Surgical Procedure

- **Animal Species:** Male Wistar rats (weighing 180-230 g) or porcine models are commonly used.[1][2][3][9][13]
- **Anesthesia:** Anesthesia is typically induced with an intraperitoneal injection of a ketamine and xylazine mixture.[1]
- **Surgical Incision:** A midline abdominal incision is made to expose the liver.
- **Liver Injury Model:** A standardized incision (e.g., 2 cm in length and 0.5 cm in depth) is made on a liver lobe to induce controlled bleeding.[1][2][9] In some porcine models, lesions of 4-6 mm deep and ~10 mm in diameter are created.[3][4]

Application of Hemostatic Agents and Data Collection

- **Application:** The hemostatic agent is applied to the bleeding site according to the manufacturer's instructions. Control groups may receive treatment with a simple suture or a saline-soaked gauze.

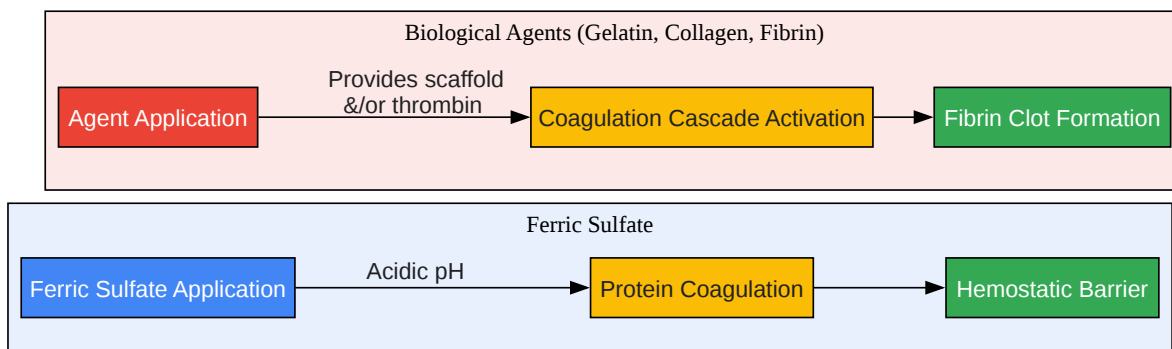
- Hemostasis Time: The time from the application of the agent until the cessation of bleeding is recorded.
- Blood Loss Measurement: Blood loss can be quantified by weighing surgical sponges before and after use.

Pathological Evaluation

- Tissue Collection: A section of the liver tissue, including the injury site, is excised at a predetermined time point (e.g., 7 days post-surgery) for histological analysis.[\[1\]](#)
- Histological Preparation: The tissue samples are fixed in 10% formalin, embedded in paraffin, sectioned, and stained with hematoxylin and eosin (H&E).[\[9\]](#)[\[10\]](#)
- Microscopic Examination: The stained sections are examined under a light microscope by a pathologist blinded to the treatment groups.
- Pathological Scoring: A semi-quantitative scoring system is often used to grade the severity of inflammation, necrosis, and granulation tissue formation.[\[8\]](#)[\[10\]](#) A common grading scale for inflammation is as follows:
 - Grade 0: No change
 - Grade 1: Minor inflammatory infiltration without edema
 - Grade 2: Mild to moderate inflammatory infiltration with mild edema
 - Grade 3: Mild to moderate inflammatory infiltration and moderate edema
 - Grade 4: Moderate inflammation with neutrophils scattered and diffuse edema
 - Grade 5: Severe inflammation of the tissue and edematous changes, fibrosis, and hemorrhage[\[8\]](#)

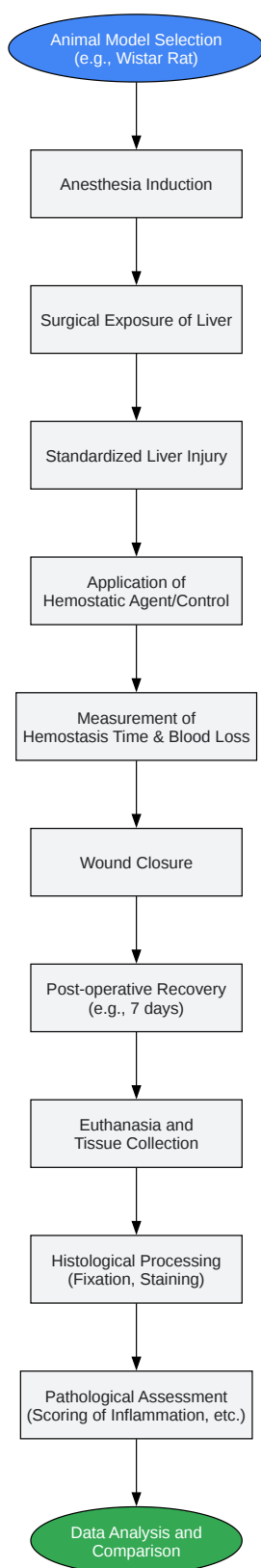
Signaling Pathways and Experimental Workflow

To visualize the logical flow of the experimental and assessment processes, the following diagrams are provided.



[Click to download full resolution via product page](#)

Caption: Mechanisms of action for different hemostatic agents.



[Click to download full resolution via product page](#)

Caption: Experimental workflow for pathological assessment.

Conclusion

The selection of a hemostatic agent for liver surgery requires a careful balance between hemostatic efficacy and tissue biocompatibility. While **ferric sulfate** demonstrates rapid hemostasis, its acidic nature leads to protein coagulation and a notable inflammatory response, particularly at higher concentrations. In contrast, modern biological agents such as gelatin-thrombin matrices and fibrin sealants, while also effective in controlling bleeding, appear to offer a more favorable pathological profile with less inflammation and better promotion of tissue healing. This guide provides a foundational comparison to aid researchers and clinicians in making informed decisions for the development and application of hemostatic technologies in the demanding field of hepatic surgery. Further research focusing on long-term outcomes and more detailed molecular analysis of the tissue response is warranted to continue advancing patient care in this area.

Need Custom Synthesis?

BenchChem offers custom synthesis for rare earth carbides and specific isotopic labeling.

Email: info@benchchem.com or [Request Quote Online](#).

References

- 1. researchgate.net [researchgate.net]
- 2. Comparing the Effect of Ferric Sulfate and Zinc Chloride in Controlling Liver Bleeding in an Animal Model Study - Avicenna Journal of Clinical Medicine [sjh.umsha.ac.ir]
- 3. An Efficacy Comparison of Two Hemostatic Agents in a Porcine Liver Bleeding Model: Gelatin/Thrombin Flowable Matrix versus Collagen/Thrombin Powder - PubMed [pubmed.ncbi.nlm.nih.gov]
- 4. tandfonline.com [tandfonline.com]
- 5. Effects of primary suture and fibrin sealant on hemostasis and liver regeneration in an experimental liver injury - PubMed [pubmed.ncbi.nlm.nih.gov]
- 6. Effects of primary suture and fib sealant on hemostasis and liver regeneration in an experimental liver injury - PMC [pmc.ncbi.nlm.nih.gov]
- 7. Comparison of the hemostatic effects of oxidized cellulose and calcium alginate in an experimental animal model of hepatic parenchymal bleeding - PMC [pmc.ncbi.nlm.nih.gov]

- 8. researchgate.net [researchgate.net]
- 9. Use of Ferric Sulfate to Control Hepatic Bleeding - PMC [pmc.ncbi.nlm.nih.gov]
- 10. traumamon.com [traumamon.com]
- 11. brieflands.com [brieflands.com]
- 12. Comparison of hemostatic and acute histopathological effects of Algan Hemostatic Agent in experimental liver lobectomy model in rats | Journal of Medical and Dental Investigations [jomdi.org]
- 13. Uncontrolled Hemorrhagic Shock Modeled via Liver Laceration in Mice with Real Time Hemodynamic Monitoring - PMC [pmc.ncbi.nlm.nih.gov]
- To cite this document: BenchChem. [Comparative Assessment of Hemostatic Agents for Liver Tissue: A Pathological Perspective]. BenchChem, [2025]. [Online PDF]. Available at: [https://www.benchchem.com/product/b154349#pathological-assessment-of-liver-tissue-after-ferric-sulfate-application]

Disclaimer & Data Validity:

The information provided in this document is for Research Use Only (RUO) and is strictly not intended for diagnostic or therapeutic procedures. While BenchChem strives to provide accurate protocols, we make no warranties, express or implied, regarding the fitness of this product for every specific experimental setup.

Technical Support: The protocols provided are for reference purposes. Unsure if this reagent suits your experiment? [[Contact our Ph.D. Support Team for a compatibility check](#)]

Need Industrial/Bulk Grade? [Request Custom Synthesis Quote](#)

BenchChem

Our mission is to be the trusted global source of essential and advanced chemicals, empowering scientists and researchers to drive progress in science and industry.

Contact

Address: 3281 E Guasti Rd
Ontario, CA 91761, United States
Phone: (601) 213-4426
Email: info@benchchem.com