

Limitations of M-mode compared to 2D echocardiography in regional wall motion assessment

Author: BenchChem Technical Support Team. **Date:** December 2025

Compound of Interest

Compound Name: M-MoDE-A (2)

Cat. No.: B15144752

[Get Quote](#)

M-Mode vs. 2D Echocardiography for Regional Wall Motion Assessment: A Comparative Guide

For Researchers, Scientists, and Drug Development Professionals

The accurate assessment of regional wall motion is critical in preclinical and clinical research for evaluating cardiac function, particularly in the context of ischemic heart disease and the development of novel cardiotropic agents. While both M-mode and two-dimensional (2D) echocardiography are foundational ultrasound techniques, they offer vastly different capabilities for the nuanced analysis of regional myocardial contractility. This guide provides an objective comparison of their performance, supported by available data and detailed methodologies.

Key Differences in Performance

M-mode echocardiography, with its high temporal resolution, excels at measuring the motion of cardiac structures along a single, narrow ultrasound beam. However, this one-dimensional view presents significant limitations in the comprehensive assessment of regional wall motion. In contrast, 2D echocardiography provides a real-time, cross-sectional image of the heart, allowing for the simultaneous visualization and analysis of multiple myocardial segments.

Quantitative Data Summary

Direct comparative studies quantifying the sensitivity and specificity of M-mode versus 2D echocardiography for detecting regional wall motion abnormalities are scarce in recent literature, largely because 2D echocardiography has long been established as the superior and standard method. However, historical comparative data and studies evaluating each modality against a gold standard, such as angiography, provide insight into their relative performance.

Feature	M-mode Echocardiography	2D Echocardiography
Spatial Information	One-dimensional ("ice-pick" view)	Two-dimensional (cross-sectional view)
Regional Assessment	Limited to segments intersecting the ultrasound beam	Comprehensive assessment of multiple segments (typically 17 segments)
Detection of Asymmetric Abnormalities	Prone to missing abnormalities outside the beam's path	High capability to detect localized wall motion defects
Agreement with Angiography	Lower agreement for segmental wall motion assessment. [1]	Higher agreement for segmental wall motion assessment. [1]
Interobserver Variability	Can be high due to difficulty in standardizing the beam position for all segments	Subject to interobserver variability, though standardized segmentation models help to mitigate this. [2] [3]
Temporal Resolution	Very high	High, but lower than M-mode

One comparative study evaluating echocardiographic techniques against left ventricular angiography in patients with recent myocardial infarction found that the total agreement in segmental wall motion was 61% for 2D echo versus angiography, while it was 59% for M-mode versus angiography.[\[1\]](#) More significantly, discrepancies in wall motion grading were attributed to obvious M-mode errors in 21% of discrepant segments, highlighting its inherent limitations.

Experimental Protocols

The methodologies for assessing regional wall motion differ significantly between M-mode and 2D echocardiography, reflecting their fundamental differences in data acquisition.

M-mode Echocardiography Protocol

- **Image Acquisition:** A 2D image is first obtained to guide the placement of the M-mode cursor. The cursor is positioned perpendicular to the interventricular septum and the posterior wall at the level of the mitral valve leaflet tips in the parasternal long-axis or short-axis view.
- **Data Recording:** The M-mode tracing displays the motion of the cardiac structures intersected by the cursor over time.
- **Analysis:** Measurements of wall thickness and excursion are taken from the M-mode tracing. Regional wall motion is inferred from the thickening and inward movement of the septal and posterior walls during systole.
- **Limitations in Protocol:** This protocol is inherently limited as it can only assess the motion of the specific segments of the septum and posterior wall that lie along the M-mode beam. It cannot provide information about the anterior, lateral, or apical walls unless the transducer is repositioned, making a comprehensive and standardized assessment of all regions challenging and often inaccurate.

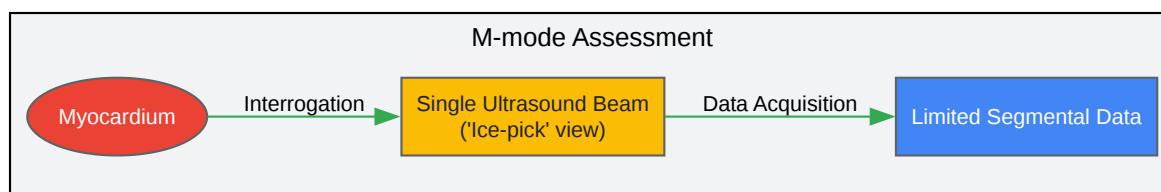
2D Echocardiography Protocol (ASE Recommended 17-Segment Model)

- **Image Acquisition:** A series of standard tomographic views are acquired, including the parasternal long-axis, parasternal short-axis (at basal, mid, and apical levels), and apical (four-chamber, two-chamber, and long-axis) views.
- **Left Ventricular Segmentation:** The left ventricle is conceptually divided into 17 segments. This standardized model ensures a systematic evaluation of all myocardial regions and allows for the correlation of wall motion abnormalities with specific coronary artery territories.
- **Wall Motion Scoring:** Each of the 17 segments is visually assessed and scored based on its contractility during systole. The scoring is typically as follows:
 - 1 = Normal or hyperkinetic (normal to increased thickening and inward motion)
 - 2 = Hypokinetic (reduced thickening and inward motion)

- 3 = Akinetic (absence of thickening and inward motion)
- 4 = Dyskinetic (paradoxical outward motion or "bulging" during systole)
- 5 = Aneurysmal (diastolic deformation)
- Wall Motion Score Index (WMSI): The WMSI is calculated by summing the scores of all visualized segments and dividing by the number of segments analyzed. A WMSI of 1 indicates normal global left ventricular function, while higher scores indicate worsening degrees of wall motion abnormalities.

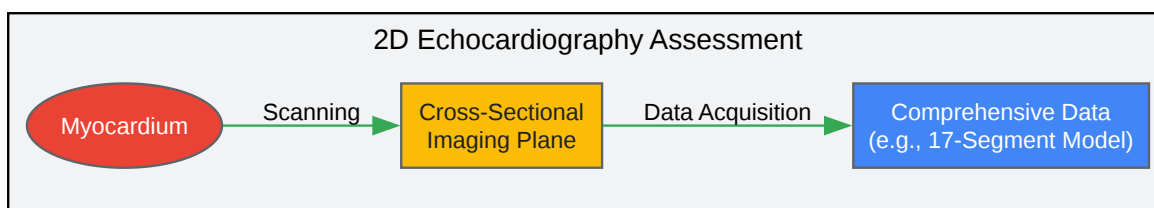
Visualization of Methodological Differences

The following diagrams illustrate the fundamental differences in how M-mode and 2D echocardiography assess regional wall motion.



[Click to download full resolution via product page](#)

Figure 1. M-mode's single-beam interrogation of the myocardium.



[Click to download full resolution via product page](#)

Figure 2. 2D echo's cross-sectional view for comprehensive assessment.

Conclusion

For the assessment of regional wall motion, 2D echocardiography is unequivocally superior to M-mode echocardiography. The fundamental limitation of M-mode is its one-dimensional nature, which precludes a comprehensive evaluation of the left ventricle and can easily miss significant regional abnormalities. While M-mode remains a valuable tool for measuring cardiac dimensions and has excellent temporal resolution, it is not suitable for the primary assessment of regional wall motion in a research or clinical setting.

2D echocardiography, with its ability to provide real-time, cross-sectional images of the heart, allows for the systematic and standardized evaluation of all myocardial segments. This comprehensive approach is essential for accurately detecting, localizing, and quantifying regional wall motion abnormalities, making it the standard of care and the preferred method for researchers, scientists, and drug development professionals. The adoption of the standardized 17-segment model further enhances the reproducibility and communicative value of 2D echocardiographic findings.

Need Custom Synthesis?

BenchChem offers custom synthesis for rare earth carbides and specific isotopic labeling.

Email: info@benchchem.com or [Request Quote Online](#).

References

- 1. Comparative study of echo- and angiographically determined regional left ventricular wall motion in recent myocardial infarction - PubMed [pubmed.ncbi.nlm.nih.gov]
- 2. Echocardiographic Detection of Regional Wall Motion Abnormalities Using Artificial Intelligence Compared to Human Readers - PMC [pmc.ncbi.nlm.nih.gov]
- 3. Inter- and intra-observer variability in the echocardiographic evaluation of wall motion abnormality in patients with ST-elevation myocardial infarction or takotsubo syndrome - A novel approach - PubMed [pubmed.ncbi.nlm.nih.gov]
- To cite this document: BenchChem. [Limitations of M-mode compared to 2D echocardiography in regional wall motion assessment]. BenchChem, [2025]. [Online PDF]. Available at: [https://www.benchchem.com/product/b15144752#limitations-of-m-mode-compared-to-2d-echocardiography-in-regional-wall-motion-assessment]

Disclaimer & Data Validity:

The information provided in this document is for Research Use Only (RUO) and is strictly not intended for diagnostic or therapeutic procedures. While BenchChem strives to provide accurate protocols, we make no warranties, express or implied, regarding the fitness of this product for every specific experimental setup.

Technical Support: The protocols provided are for reference purposes. Unsure if this reagent suits your experiment? [[Contact our Ph.D. Support Team for a compatibility check](#)]

Need Industrial/Bulk Grade? [Request Custom Synthesis Quote](#)

BenchChem

Our mission is to be the trusted global source of essential and advanced chemicals, empowering scientists and researchers to drive progress in science and industry.

Contact

Address: 3281 E Guasti Rd
Ontario, CA 91761, United States
Phone: (601) 213-4426
Email: info@benchchem.com