

# Disofenin Imaging: A Comparative Guide to Surgical and Histopathological Correlation

**Author:** BenchChem Technical Support Team. **Date:** December 2025

## Compound of Interest

Compound Name: Disofenin

Cat. No.: B014549

[Get Quote](#)

For Researchers, Scientists, and Drug Development Professionals

This guide provides an objective comparison of **Disofenin** (HIDA) imaging findings with definitive surgical and histopathological data. It is designed to offer researchers, scientists, and drug development professionals a comprehensive overview of the diagnostic performance of this nuclear medicine technique in various hepatobiliary disorders. The information presented is supported by experimental data from clinical studies, with detailed methodologies and visual representations of key concepts.

## I. Diagnostic Performance of Disofenin Imaging

**Disofenin** imaging, a form of cholescintigraphy, is a functional imaging modality that provides valuable information about the function of hepatocytes, the patency of the biliary ducts, and gallbladder function.<sup>[1]</sup> Its diagnostic accuracy has been extensively evaluated against the gold standards of surgical intervention and histopathological examination of tissue specimens.<sup>[2][3]</sup>

### Acute Cholecystitis

Acute cholecystitis is a primary indication for **Disofenin** imaging.<sup>[4]</sup> The hallmark of this condition in cholescintigraphy is the non-visualization of the gallbladder, which is indicative of cystic duct obstruction.<sup>[4]</sup>

Table 1: Diagnostic Accuracy of **Disofenin** Imaging in Suspected Acute Cholecystitis

Study/Parameter	Sensitivity	Specificity	Positive Predictive Value (PPV)	Negative Predictive Value (NPV)	Accuracy
Colletti et al. (Radionuclide Angiography)	72%	94%	92%	-	-
Retrospective Study (vs. Histopathology)	78%	76.08%	-	-	-
Comparative Study (vs. Ultrasonography)	Superior to Ultrasonography	Superior to Ultrasonography	Superior to Ultrasonography	Superior to Ultrasonography	92%

Data compiled from multiple sources.[5][6][7]

In a study involving 65 patients with suspected acute cholecystitis, radionuclide angiography with technetium-99m **disofenin** demonstrated a sensitivity of 72% and a specificity of 94%.[5] The positive predictive value was 92%, with surgical confirmation in 23 of 25 cases with positive angiographic findings.[5] Another retrospective analysis comparing radiological findings to postoperative histopathology in 350 patients found that HIDA scans had the highest sensitivity (78%) among imaging modalities, with a specificity of 76.08%.[6][8] Furthermore, a direct comparison with ultrasonography in 107 patients showed that hepatobiliary scintigraphy has a superior diagnostic accuracy of 92% versus 77% for ultrasound.[7]

Specific imaging findings can also predict the severity of acute cholecystitis. The "rim sign," for instance, which is a rim of increased tracer activity around the gallbladder fossa, is associated with a higher incidence of transmural inflammation and extension of inflammation into the adjacent liver tissue.[9] In one study, 95% of patients with a rim sign had transmural inflammation on microscopic review, compared to 59% of those without the sign.[9]

## Neonatal Cholestasis and Biliary Atresia

**Disofenin** imaging is a crucial tool in the differential diagnosis of neonatal cholestasis, particularly in distinguishing biliary atresia from other causes like neonatal hepatitis.[10][11] The key diagnostic finding for biliary atresia is the absence of gut excretion of the radiotracer.[10]

Table 2: Diagnostic Accuracy of **Disofenin** Imaging in Neonatal Cholestasis for Biliary Atresia

Study/Parameter	Sensitivity	Specificity
Spivak et al. (DISIDA Scan)	100%	43% (improves with clinical data)
Retrospective Study (Mebrofenin Scan)	- (49% of non-excreting scans were BA)	-

Data compiled from multiple sources.[10][11]

A retrospective study evaluating DISIDA scanning in 28 infants found that the absence of gut excretion was 100% sensitive for biliary atresia but had a specificity of only 43%.[10] However, when combined with clinical data, such as a birth weight greater than 2200 g in infants without gut excretion, the specificity for biliary atresia increased to 92%.[10] It is important to note that a non-excreting scan can also occur in severe intrahepatic cholestasis, leading to false-positive results.[11] In such cases, repeating the study may be beneficial.[10] The gold standard for the diagnosis of biliary atresia remains intraoperative cholangiogram and histological examination of the duct remnant.[12]

## II. Experimental Protocols

The following sections outline the typical methodologies employed in **Disofenin** imaging studies that are correlated with surgical or histopathological data.

### Patient Preparation

For elective procedures, patients are typically required to fast for a minimum of 4 to 6 hours before the administration of the radiotracer. This is to ensure gallbladder filling and to avoid false-positive results due to physiological gallbladder emptying in response to a meal. In emergency settings for suspected acute cholecystitis, the fasting state is also preferred but may not always be feasible.

## Radiopharmaceutical and Administration

The most commonly used radiotracer is Technetium-99m (Tc-99m) labeled to a derivative of iminodiacetic acid (IDA), such as **Disofenin** or Mebrofenin.[1] A standard adult dose is administered intravenously as a bolus injection.[5]

## Imaging Protocol

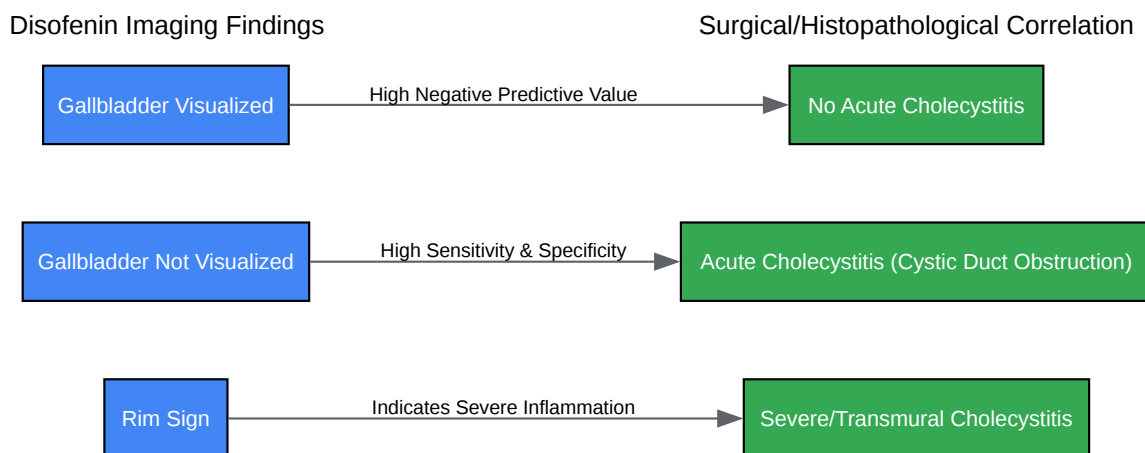
- **Dynamic Acquisition:** Immediately following the injection, dynamic images are acquired over the liver and biliary system.
- **Static Imaging:** Serial static images are typically obtained at 5, 15, 30, 45, and 60 minutes post-injection.
- **Delayed Imaging:** If the gallbladder is not visualized within 60 minutes, delayed imaging at 2 to 4 hours is often performed.[5] In some protocols, imaging may extend up to 24 hours, particularly in cases of neonatal cholestasis.[10]
- **Pharmacological Intervention:** In cases where the gallbladder is not visualized and the tracer is seen in the small intestine, a low dose of morphine may be administered to induce sphincter of Oddi contraction, which can promote gallbladder filling. Conversely, to assess gallbladder ejection fraction in suspected chronic cholecystitis, cholecystikinin (CCK) or a fatty meal can be administered to stimulate gallbladder contraction.[13]

## Surgical and Histopathological Correlation

- **Surgical Confirmation:** For conditions like acute cholecystitis, the findings of the **Disofenin** scan are correlated with the operative findings during cholecystectomy.[9]
- **Histopathological Analysis:** The excised gallbladder or liver biopsy specimen is subjected to histopathological examination.[2] This serves as the definitive diagnosis and the gold standard against which the imaging findings are compared.[3] For neonatal cholestasis, a liver biopsy is essential for the diagnostic workup.[14]

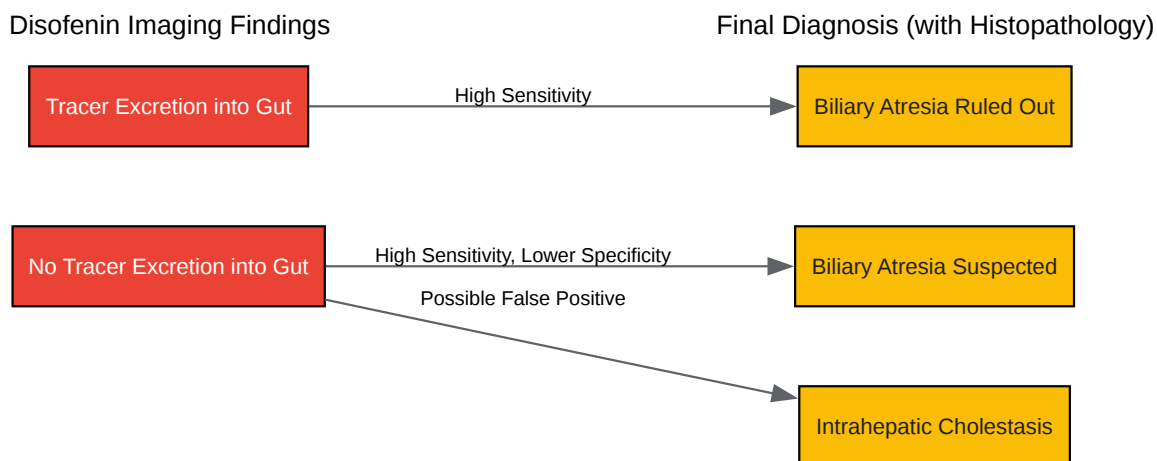
## III. Visualizing Diagnostic Pathways

The following diagrams illustrate the logical flow and relationships in the diagnostic process using **Disofenin** imaging.



[Click to download full resolution via product page](#)

Diagnostic pathway for acute cholecystitis.



[Click to download full resolution via product page](#)

Diagnostic pathway for neonatal cholestasis.

## IV. Comparison with Alternative Modalities

While **Disofenin** imaging is highly accurate for functional assessment, other imaging modalities like ultrasonography are often used as a first-line investigation.

Table 3: Comparison of **Disofenin** Imaging and Ultrasonography for Acute Cholecystitis

Feature	Disofenin Imaging	Ultrasonography
Principle	Functional imaging of bile flow	Anatomical imaging
Primary Finding	Cystic duct obstruction (non-visualization of gallbladder)	Gallstones, gallbladder wall thickening, pericholecystic fluid
Sensitivity	High (often >90%)	Variable (generally lower than scintigraphy)
Specificity	High (often >90%)	High
Accuracy	Generally higher than ultrasonography[7]	Lower than scintigraphy[7]
Limitations	Use of ionizing radiation, may be less effective in patients with severe liver dysfunction	Operator dependent, may be limited by patient body habitus

In a retrospective study, while the HIDA scan had the highest sensitivity, ultrasonography demonstrated the highest specificity (90.47%) for acute cholecystitis when compared to histopathology.[6][8] However, for overall diagnostic accuracy in suspected acute cholecystitis, hepatobiliary scintigraphy has been shown to be superior.[7]

## V. Conclusion

**Disofenin** imaging demonstrates a strong correlation with surgical and histopathological findings, particularly in the diagnosis of acute cholecystitis and in the differentiation of neonatal cholestasis. Its high sensitivity and specificity for detecting cystic duct obstruction make it an invaluable tool in clinical practice. For researchers and professionals in drug development, understanding the robust correlation between **Disofenin** imaging findings and definitive pathological outcomes is crucial for evaluating hepatobiliary function and the effects of novel therapeutic agents. The detailed experimental protocols and the established diagnostic

accuracy provide a solid foundation for incorporating this imaging modality into clinical trials and preclinical studies.

#### Need Custom Synthesis?

BenchChem offers custom synthesis for rare earth carbides and specific isotopic labeling.

Email: [info@benchchem.com](mailto:info@benchchem.com) or [Request Quote Online](#).

## References

- 1. Hepatobiliary Iminodiacetic Acid Scan - StatPearls - NCBI Bookshelf [ncbi.nlm.nih.gov]
- 2. Correlation of in-vivo imaging with histopathology: A review - PubMed [pubmed.ncbi.nlm.nih.gov]
- 3. Ultrasound for the Diagnosis of Acute Calculous Cholecystitis, and the Impact of Analgesics: A Retrospective Cohort Study [riojournal.com]
- 4. Cholescintigraphy in acute and chronic cholecystitis - PubMed [pubmed.ncbi.nlm.nih.gov]
- 5. Acute cholecystitis: diagnosis with radionuclide angiography - PubMed [pubmed.ncbi.nlm.nih.gov]
- 6. A Retrospective Study Comparing Radiological to Histopathological Diagnosis After Laparoscopic Cholecystectomy for Suspected Cholecystitis - PMC [pmc.ncbi.nlm.nih.gov]
- 7. Hepatobiliary scintigraphy is superior to abdominal ultrasonography in suspected acute cholecystitis - PubMed [pubmed.ncbi.nlm.nih.gov]
- 8. A Retrospective Study Comparing Radiological to Histopathological Diagnosis After Laparoscopic Cholecystectomy for Suspected Cholecystitis - PubMed [pubmed.ncbi.nlm.nih.gov]
- 9. The rim sign in acute cholecystitis. Comparison of radionuclide, surgical, and pathologic findings - PubMed [pubmed.ncbi.nlm.nih.gov]
- 10. Diagnostic utility of hepatobiliary scintigraphy with 99mTc-DISIDA in neonatal cholestasis - PubMed [pubmed.ncbi.nlm.nih.gov]
- 11. Pathological Variables and Laboratory Values in Infants with Neonatal Cholestasis Showing Nonexcretion on Tc-99m Mebrofenin Hepatobiliary Scans: A Descriptive Study - PMC [pmc.ncbi.nlm.nih.gov]
- 12. [emedicine.medscape.com](https://www.emedicine.medscape.com) [emedicine.medscape.com]

- 13. my.clevelandclinic.org [my.clevelandclinic.org]
- 14. Pathologic approach to Neonatal cholestasis with a simple scoring system for biliary atresia - PMC [pmc.ncbi.nlm.nih.gov]
- To cite this document: BenchChem. [Disofenin Imaging: A Comparative Guide to Surgical and Histopathological Correlation]. BenchChem, [2025]. [Online PDF]. Available at: [https://www.benchchem.com/product/b014549#correlation-of-disofenin-imaging-findings-with-surgical-or-histopathological-data]

---

### Disclaimer & Data Validity:

The information provided in this document is for Research Use Only (RUO) and is strictly not intended for diagnostic or therapeutic procedures. While BenchChem strives to provide accurate protocols, we make no warranties, express or implied, regarding the fitness of this product for every specific experimental setup.

**Technical Support:** The protocols provided are for reference purposes. Unsure if this reagent suits your experiment? [[Contact our Ph.D. Support Team for a compatibility check](#)]

**Need Industrial/Bulk Grade?** [Request Custom Synthesis Quote](#)

## BenchChem

Our mission is to be the trusted global source of essential and advanced chemicals, empowering scientists and researchers to drive progress in science and industry.

### Contact

Address: 3281 E Guasti Rd

Ontario, CA 91761, United States

Phone: (601) 213-4426

Email: [info@benchchem.com](mailto:info@benchchem.com)