

# Application Notes and Protocols for Histopathological Analysis of Tissues Following Dimefluthrin Exposure

**Author:** BenchChem Technical Support Team. **Date:** December 2025

## Compound of Interest

Compound Name: Dimefluthrin

Cat. No.: B1295995

[Get Quote](#)

For Researchers, Scientists, and Drug Development Professionals

## Introduction

**Dimefluthrin**, a synthetic pyrethroid insecticide, is widely utilized in household products for mosquito control. While effective, its continuous and prolonged exposure raises toxicological concerns, necessitating a thorough evaluation of its potential impact on non-target organisms. Histopathological analysis serves as a cornerstone in toxicology studies, providing critical insights into cellular and tissue-level alterations induced by chemical agents. These application notes provide a comprehensive overview of the histopathological changes observed in various tissues following exposure to **Dimefluthrin** and related pyrethroids. Detailed protocols for tissue processing and analysis are included to guide researchers in conducting similar assessments.

## Histopathological Findings

Exposure to **Dimefluthrin** and other pyrethroids has been shown to induce a range of histopathological changes across multiple organ systems. The severity of these effects is often dose- and duration-dependent.

## Liver

The liver, a primary site of xenobiotic metabolism, is particularly susceptible to toxic injury. Histopathological examination of liver tissue from animals exposed to **Dimefluthrin** has revealed several key alterations:

- **Degeneration and Necrosis:** Studies have reported hydropic degeneration, characterized by cellular swelling, and necrosis, particularly in the portal areas.[\[1\]](#)[\[2\]](#) Higher concentrations of **Dimefluthrin** are associated with increased rates of cell degeneration and necrosis.[\[2\]](#)
- **Inflammatory Infiltration:** Infiltration of inflammatory cells is a common finding, indicating an active immune response to cellular damage.[\[1\]](#)
- **Fibrosis:** Chronic exposure can lead to the deposition of fibrous connective tissue, particularly in the portal areas, which can impair liver function.[\[1\]](#)
- **Vascular Changes:** Sinusoidal dilatation and congestion have also been observed.[\[3\]](#)[\[4\]](#)

## Kidney

The kidneys play a crucial role in filtering and excreting metabolites, making them vulnerable to toxicants. Histopathological changes in the kidney following **Dimefluthrin** exposure include:

- **Tubular Damage:** Degeneration and necrosis of renal tubular epithelial cells are prominent features.[\[2\]](#)[\[5\]](#) This can be accompanied by a narrowing of the tubular lumen.[\[6\]](#)
- **Glomerular Alterations:** Damage to the glomeruli, including shrinkage and dilation of Bowman's space, has been noted.[\[6\]](#)[\[7\]](#)[\[8\]](#)
- **Inflammation:** Infiltration of lymphocytes and erythrocytes is indicative of an inflammatory response within the kidney tissue.[\[5\]](#)

## Lungs

Inhalation is a significant route of exposure for volatile insecticides like **Dimefluthrin**. The lungs can exhibit the following histopathological changes:

- **Congestion and Edema:** Heavy congestion and marked perivascular edema are frequently observed.[\[9\]](#)[\[10\]](#)

- **Inflammation:** Lymphoplasmacytic infiltration and nonspecific interstitial pneumonia are signs of an inflammatory response in the lung tissue.[\[9\]](#)[\[10\]](#) Pleural thickening has also been reported.[\[11\]](#)
- **Cellular Alterations:** Degeneration of ciliated cells and hyperplasia of type II alveolar cells can occur.[\[9\]](#)

## Nervous System

Neurotoxicity is a known concern for pyrethroid insecticides. Histopathological analysis of brain tissue has revealed:

- **Neuronal Degeneration:** Studies have shown neuronal degeneration and an increase in glial cells (gliosis) in the brain.[\[7\]](#)[\[12\]](#)
- **Structural Damage:** In zebrafish larvae, **Dimefluthrin** has been shown to impair the development of the olfactory bulb and peripheral nerves, as well as damage the blood-brain barrier.[\[13\]](#)

## Reproductive Organs

The reproductive system can also be a target for pyrethroid toxicity. Key findings include:

- **Testicular Damage:** Exposure can lead to the disorganization and degeneration of seminiferous tubules, with a loss of spermatogenic cells.[\[7\]](#)[\[14\]](#)
- **Ovarian Effects:** In females, a loss of follicular cells and oocytes has been observed.[\[7\]](#)

## Quantitative Data Summary

The following tables summarize representative quantitative data based on findings from various studies. It is important to note that specific values can vary depending on the experimental model, dose, and duration of exposure.

Table 1: Liver Histopathology Scores

Treatment Group	Degeneration Score (Mean $\pm$ SD)	Necrosis Score (Mean $\pm$ SD)	Inflammation Score (Mean $\pm$ SD)
Control	0.2 $\pm$ 0.1	0.1 $\pm$ 0.1	0.3 $\pm$ 0.2
Low-Dose Dimefluthrin	1.5 $\pm$ 0.4	1.2 $\pm$ 0.3	1.8 $\pm$ 0.5
High-Dose Dimefluthrin	2.8 $\pm$ 0.6	2.5 $\pm$ 0.5	2.9 $\pm$ 0.7
*Scoring system: 0 = None, 1 = Mild, 2 = Moderate, 3 = Severe. p < 0.05 compared to control.			

Table 2: Kidney Histopathology Scores

Treatment Group	Tubular Degeneration Score (Mean $\pm$ SD)	Glomerular Damage Score (Mean $\pm$ SD)	Interstitial Inflammation Score (Mean $\pm$ SD)
Control	0.3 $\pm$ 0.2	0.2 $\pm$ 0.1	0.4 $\pm$ 0.2
Low-Dose Dimefluthrin	1.7 $\pm$ 0.5	1.4 $\pm$ 0.4	1.9 $\pm$ 0.6
High-Dose Dimefluthrin	2.9 $\pm$ 0.7	2.6 $\pm$ 0.6	3.0 $\pm$ 0.8
*Scoring system: 0 = None, 1 = Mild, 2 = Moderate, 3 = Severe. p < 0.05 compared to control.			

Table 3: Lung Histopathology Scores

Treatment Group	Congestion Score (Mean $\pm$ SD)	Edema Score (Mean $\pm$ SD)	Inflammatory Infiltration Score (Mean $\pm$ SD)
Control	0.5 $\pm$ 0.3	0.4 $\pm$ 0.2	0.6 $\pm$ 0.3
Low-Dose Dimefluthrin	2.0 $\pm$ 0.6	1.8 $\pm$ 0.5	2.2 $\pm$ 0.7
High-Dose Dimefluthrin	3.5 $\pm$ 0.8	3.2 $\pm$ 0.7	3.6 $\pm$ 0.9

\*Scoring system: 0 = None, 1 = Mild, 2 = Moderate, 3 = Severe, 4 = Marked.  $p < 0.05$  compared to control.

## Experimental Protocols

### Protocol 1: Tissue Collection and Fixation

- **Animal Euthanasia:** Euthanize the experimental animals (e.g., rats, mice) according to approved institutional animal care and use committee (IACUC) protocols.
- **Tissue Dissection:** Immediately dissect the target organs (liver, kidneys, lungs, brain, gonads).
- **Rinsing:** Gently rinse the tissues with ice-cold phosphate-buffered saline (PBS) to remove excess blood.
- **Fixation:** Immerse the tissues in a sufficient volume of 10% neutral buffered formalin for 24-48 hours at room temperature. The volume of fixative should be at least 10 times the volume of the tissue. For lung tissue, intratracheal instillation of the fixative at a constant pressure is recommended for optimal inflation and preservation of architecture.[\[15\]](#)

### Protocol 2: Tissue Processing and Embedding

- **Dehydration:** Dehydrate the fixed tissues through a graded series of ethanol solutions (e.g., 70%, 80%, 95%, 100% ethanol).
- **Clearing:** Clear the dehydrated tissues using an appropriate clearing agent such as xylene.
- **Infiltration:** Infiltrate the cleared tissues with molten paraffin wax in a tissue processor.
- **Embedding:** Embed the infiltrated tissues in paraffin blocks using a tissue embedding station.

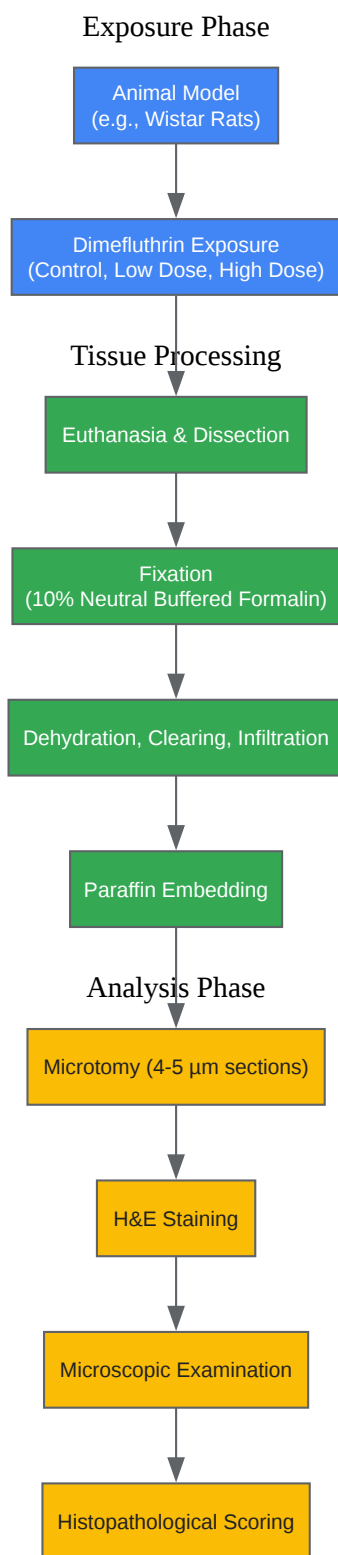
## Protocol 3: Sectioning and Staining

- **Sectioning:** Cut 4-5  $\mu\text{m}$  thick sections from the paraffin blocks using a microtome.
- **Mounting:** Float the sections on a warm water bath and mount them onto clean glass slides.
- **Drying:** Dry the slides overnight in an oven at 37-40°C.
- **Deparaffinization and Rehydration:** Deparaffinize the sections in xylene and rehydrate them through a descending series of ethanol concentrations to water.
- **Hematoxylin and Eosin (H&E) Staining:**
  - Stain with Hematoxylin solution to stain the cell nuclei blue/purple.
  - Rinse in running tap water.
  - Differentiate in acid alcohol to remove excess stain.
  - Blue in a suitable bluing agent (e.g., Scott's tap water).
  - Rinse in running tap water.
  - Counterstain with Eosin solution to stain the cytoplasm and extracellular matrix pink/red.
- **Dehydration and Mounting:** Dehydrate the stained sections through an ascending series of ethanol, clear in xylene, and mount with a coverslip using a permanent mounting medium.

## Protocol 4: Microscopic Examination and Scoring

- Microscopy: Examine the stained tissue sections under a light microscope.
- Image Capture: Capture representative images of the histopathological changes observed.
- Scoring: Semi-quantitatively score the observed lesions (e.g., degeneration, necrosis, inflammation, fibrosis) using a predefined scoring system (e.g., 0 = no change, 1 = mild, 2 = moderate, 3 = severe). The scoring should be performed by at least two independent pathologists in a blinded manner to minimize bias.

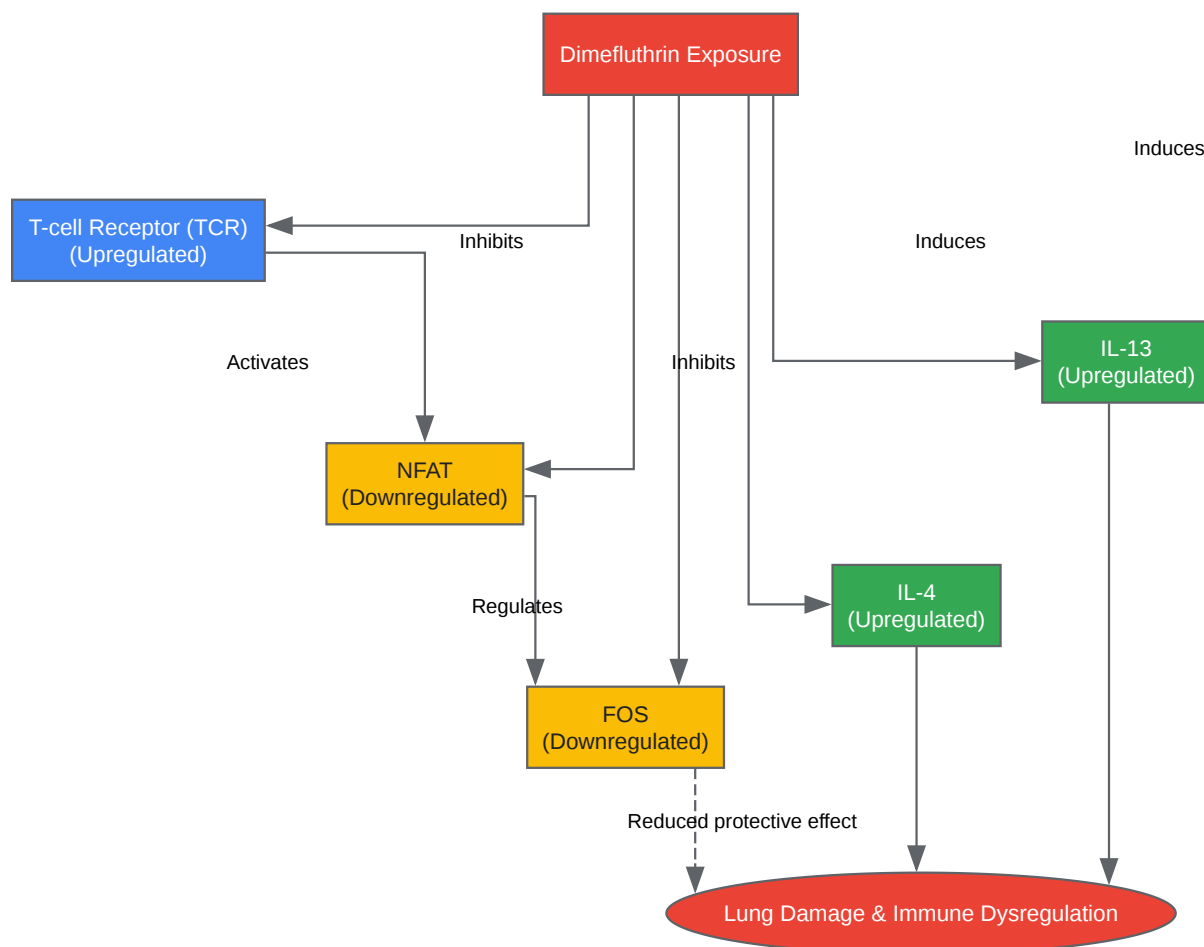
## Visualizations



[Click to download full resolution via product page](#)

Caption: Experimental workflow for histopathological analysis.





[Click to download full resolution via product page](#)

Caption: Dysregulation of the NFAT signaling pathway in lung tissue.

#### Need Custom Synthesis?

BenchChem offers custom synthesis for rare earth carbides and specific isotopic labeling.

Email: [info@benchchem.com](mailto:info@benchchem.com) or [Request Quote Online](#).

## References

- 1. researchgate.net [researchgate.net]

- 2. repository.unusa.ac.id [repository.unusa.ac.id]
- 3. Biochemical and histological changes in rat liver caused by cypermethrin and beta-cyfluthrin - PubMed [pubmed.ncbi.nlm.nih.gov]
- 4. researchgate.net [researchgate.net]
- 5. journal.uui.ac.id [journal.uui.ac.id]
- 6. biology-journal.org [biology-journal.org]
- 7. Toxic impacts of cypermethrin on behavior and histology of certain tissues of albino rats - PubMed [pubmed.ncbi.nlm.nih.gov]
- 8. nephropathol.com [nephropathol.com]
- 9. Pulmonary effects of deltamethrin inhalation: an experimental study in rats - PubMed [pubmed.ncbi.nlm.nih.gov]
- 10. researchgate.net [researchgate.net]
- 11. researchgate.net [researchgate.net]
- 12. Combined Neurotoxic Effects of Commercial Formulations of Pyrethroid (Deltamethrin) and Neonicotinoid (Imidacloprid) Pesticides on Adult Zebrafish (Danio rerio): Behavioral, Molecular, and Histopathological Analysis [mdpi.com]
- 13. The hygienic insecticide dimefluthrin induced neurodevelopmental deficits and behavioral disorders in zebrafish (Danio rerio) larvae - PubMed [pubmed.ncbi.nlm.nih.gov]
- 14. researchgate.net [researchgate.net]
- 15. In Vivo Exposure of Deltamethrin Dysregulates the NFAT Signalling Pathway and Induces Lung Damage - PMC [pmc.ncbi.nlm.nih.gov]
- To cite this document: BenchChem. [Application Notes and Protocols for Histopathological Analysis of Tissues Following Dimefluthrin Exposure]. BenchChem, [2025]. [Online PDF]. Available at: [https://www.benchchem.com/product/b1295995#histopathological-analysis-of-tissues-after-dimefluthrin-exposure]

---

### Disclaimer & Data Validity:

The information provided in this document is for Research Use Only (RUO) and is strictly not intended for diagnostic or therapeutic procedures. While BenchChem strives to provide accurate protocols, we make no warranties, express or implied, regarding the fitness of this product for every specific experimental setup.

**Technical Support:** The protocols provided are for reference purposes. Unsure if this reagent suits your experiment? [[Contact our Ph.D. Support Team for a compatibility check](#)]

**Need Industrial/Bulk Grade?** [Request Custom Synthesis Quote](#)

## BenchChem

Our mission is to be the trusted global source of essential and advanced chemicals, empowering scientists and researchers to drive progress in science and industry.

### Contact

Address: 3281 E Guasti Rd  
Ontario, CA 91761, United States  
Phone: (601) 213-4426  
Email: [info@benchchem.com](mailto:info@benchchem.com)