

# A comparative study of magnum morphology in healthy vs. diseased birds.

**Author:** BenchChem Technical Support Team. **Date:** December 2025

## Compound of Interest

Compound Name: *Magnum*

Cat. No.: *B12768669*

[Get Quote](#)

## A Comparative Study of Magnum Morphology in Healthy vs. Diseased Birds

For Researchers, Scientists, and Drug Development Professionals

This guide provides a comprehensive comparison of the morphological and histological characteristics of the avian **magnum** in healthy birds versus those afflicted with common viral diseases, namely Newcastle Disease (ND) and Infectious Bronchitis (IB). This objective analysis is supported by a summary of experimental data and detailed methodologies to aid in research and development aimed at mitigating the impact of these diseases on poultry reproduction.

### Gross and Histomorphological Comparison

The **magnum**, the longest and most coiled segment of the avian oviduct, is responsible for the synthesis and secretion of albumen, the egg white.<sup>[1]</sup> Its intricate structure is finely tuned for this function, and any pathological insult can lead to significant alterations in its morphology and, consequently, egg quality.

In healthy laying hens, the **magnum** is a robust, highly glandular organ. Its mucosal surface is characterized by numerous primary and secondary folds, which significantly increase the secretory surface area. These folds are lined with a simple columnar epithelium composed of

ciliated and non-ciliated secretory (goblet) cells. The lamina propria is densely packed with branched tubular glands responsible for producing the majority of the albumen proteins.<sup>[2]</sup>

Viral infections, such as those caused by Newcastle Disease Virus (NDV) and Infectious Bronchitis Virus (IBV), can induce profound changes in the **magnum**'s structure and function. These changes are often associated with a drastic drop in egg production and the laying of poor-quality eggs with watery whites.<sup>[3][4]</sup>

## Data Presentation: Morphological and Histological Changes

The following tables summarize the key morphological and histological differences observed between the **magnum** of healthy birds and those infected with NDV and IBV.

Table 1: Gross Morphological Changes in the **Magnum**

Parameter	Healthy Birds	Birds with Newcastle Disease	Birds with Infectious Bronchitis
Appearance	Turgid, well-coiled, pinkish	Flaccid, edematous, hemorrhagic	Atrophied, cystic in some cases
Length	Varies by breed (e.g., 19-33 cm)	Generally reduced	Significantly reduced
Weight	Varies by breed and laying status	Decreased	Significantly decreased
Mucosal Folds	Prominent and well-defined	Swollen, flattened, and hemorrhagic	Atrophied and flattened

Table 2: Histological and Cellular Changes in the **Magnum**

Parameter	Healthy Birds	Birds with Newcastle Disease	Birds with Infectious Bronchitis
Epithelium	Intact simple columnar with ciliated and goblet cells	Degeneration and necrosis of epithelial cells	Deciliation, degeneration of glandular epithelial cells[3]
Glands	Densely packed, active tubular glands	Glandular atrophy, edema, and necrosis	Atrophy of tubular glands, cytopathological changes[3]
Lamina Propria	Normal cellularity	Infiltration of lymphocytes and other inflammatory cells	Infiltration of lymphocytes and plasma cells
Cellular Changes	Normal organelle structure	Apoptosis, pyknotic nuclei in glandular cells	Increased RER deposits, cytopathology in organelles[3]

## Experimental Protocols

The following are detailed methodologies for key experiments commonly used in the study of avian **magnum** morphology.

### Hematoxylin and Eosin (H&E) Staining of Avian Oviduct Tissue

Objective: To visualize the general tissue architecture and cellular morphology of the **magnum**.

Materials:

- 10% Neutral Buffered Formalin (NBF)
- Ethanol (70%, 80%, 95%, 100%)

- Xylene
- Paraffin wax
- Microtome
- Glass slides
- Harris's Hematoxylin
- Eosin Y solution
- Acid alcohol (1% HCl in 70% ethanol)
- Scott's tap water substitute (or running tap water)
- DPX mounting medium

Procedure:

- Fixation: Immediately after euthanasia, dissect the **magnum** and fix in 10% NBF for 24-48 hours. The volume of fixative should be at least 10 times the volume of the tissue.
- Dehydration: Dehydrate the fixed tissue through a graded series of ethanol solutions:
  - 70% ethanol: 2 changes, 1 hour each
  - 80% ethanol: 1 hour
  - 95% ethanol: 2 changes, 1 hour each
  - 100% ethanol: 3 changes, 1 hour each
- Clearing: Clear the tissue in xylene with 2-3 changes, 1 hour each.
- Infiltration and Embedding: Infiltrate the tissue with molten paraffin wax at 58-60°C in an oven. Perform 2-3 changes of paraffin, 1-2 hours each. Embed the tissue in a paraffin block.

- Sectioning: Cut 4-5  $\mu\text{m}$  thick sections using a rotary microtome. Float the sections on a warm water bath (40-45°C) and mount them onto clean glass slides.
- Drying: Dry the slides overnight in an oven at 37°C or for 1 hour at 60°C.
- Deparaffinization and Rehydration:
  - Xylene: 2 changes, 5 minutes each
  - 100% ethanol: 2 changes, 3 minutes each
  - 95% ethanol: 2 minutes
  - 70% ethanol: 2 minutes
  - Distilled water: 5 minutes
- Staining:
  - Stain with Harris's Hematoxylin for 5-10 minutes.
  - Rinse in running tap water for 5 minutes.
  - Differentiate in 1% acid alcohol for a few seconds.
  - Rinse in running tap water for 5 minutes.
  - Blue the sections in Scott's tap water substitute or running tap water for 1-2 minutes.
  - Rinse in running tap water for 5 minutes.
  - Counterstain with Eosin Y for 1-3 minutes.
  - Rinse briefly in running tap water.
- Dehydration and Mounting:
  - 95% ethanol: 2 changes, 3 minutes each

- 100% ethanol: 2 changes, 3 minutes each
- Xylene: 2 changes, 5 minutes each
- Mount with a coverslip using DPX mounting medium.

## Immunohistochemistry (IHC) for CD3, CD4, and CD8 Lymphocytes

Objective: To identify and localize T-lymphocyte populations within the **magnum** tissue, indicating an inflammatory response.

Materials:

- Paraffin-embedded tissue sections on charged slides
- Xylene
- Ethanol (100%, 95%, 70%)
- Antigen retrieval buffer (e.g., Citrate buffer, pH 6.0)
- Hydrogen peroxide (3%)
- Blocking solution (e.g., 5% normal goat serum in PBS)
- Primary antibodies (Rabbit anti-chicken CD3, Mouse anti-chicken CD4, Mouse anti-chicken CD8)
- Biotinylated secondary antibodies (Goat anti-rabbit IgG, Goat anti-mouse IgG)
- Streptavidin-HRP conjugate
- DAB (3,3'-Diaminobenzidine) chromogen substrate
- Hematoxylin counterstain
- DPX mounting medium

**Procedure:**

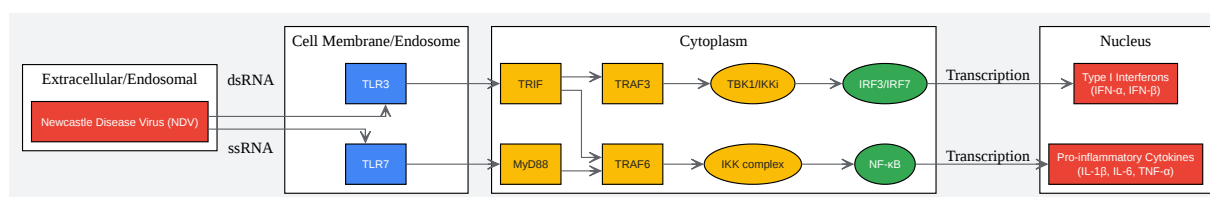
- Deparaffinization and Rehydration: Follow steps 7a-e from the H&E protocol.
- Antigen Retrieval:
  - Immerse slides in pre-heated antigen retrieval buffer.
  - Heat in a microwave, pressure cooker, or water bath according to standard protocols (e.g., microwave at high power for 5 minutes, then low power for 15 minutes).
  - Allow slides to cool in the buffer for 20-30 minutes.
  - Rinse slides in distilled water and then in PBS.
- Peroxidase Blocking: Incubate sections with 3% hydrogen peroxide for 10-15 minutes to block endogenous peroxidase activity. Rinse with PBS.
- Blocking: Incubate sections with the blocking solution for 30-60 minutes at room temperature in a humidified chamber to block non-specific antibody binding.
- Primary Antibody Incubation:
  - Dilute the primary antibodies (anti-CD3, anti-CD4, or anti-CD8) to their optimal concentration in PBS.
  - Incubate the sections with the primary antibody overnight at 4°C in a humidified chamber.
- Secondary Antibody Incubation:
  - Rinse slides with PBS (3 changes, 5 minutes each).
  - Incubate with the appropriate biotinylated secondary antibody for 30-60 minutes at room temperature.
- Detection:
  - Rinse slides with PBS (3 changes, 5 minutes each).

- Incubate with streptavidin-HRP conjugate for 30 minutes at room temperature.
- Rinse slides with PBS (3 changes, 5 minutes each).
- Chromogen Development:
  - Incubate sections with DAB substrate solution until a brown color develops (typically 1-10 minutes). Monitor under a microscope.
  - Stop the reaction by rinsing with distilled water.
- Counterstaining: Lightly counterstain with hematoxylin for 30-60 seconds. Rinse with running tap water.
- Dehydration and Mounting: Follow steps 9a-c from the H&E protocol.

## Signaling Pathways and Experimental Workflows

### Newcastle Disease Virus (NDV) and the Toll-Like Receptor (TLR) Signaling Pathway

NDV infection in the avian oviduct triggers a robust innate immune response, primarily mediated through the recognition of viral components by Toll-like receptors (TLRs).[5] The binding of viral RNA to TLRs, such as TLR3 and TLR7, initiates a signaling cascade that leads to the production of pro-inflammatory cytokines and interferons, contributing to the observed inflammation and tissue damage in the **magnum**.[3]



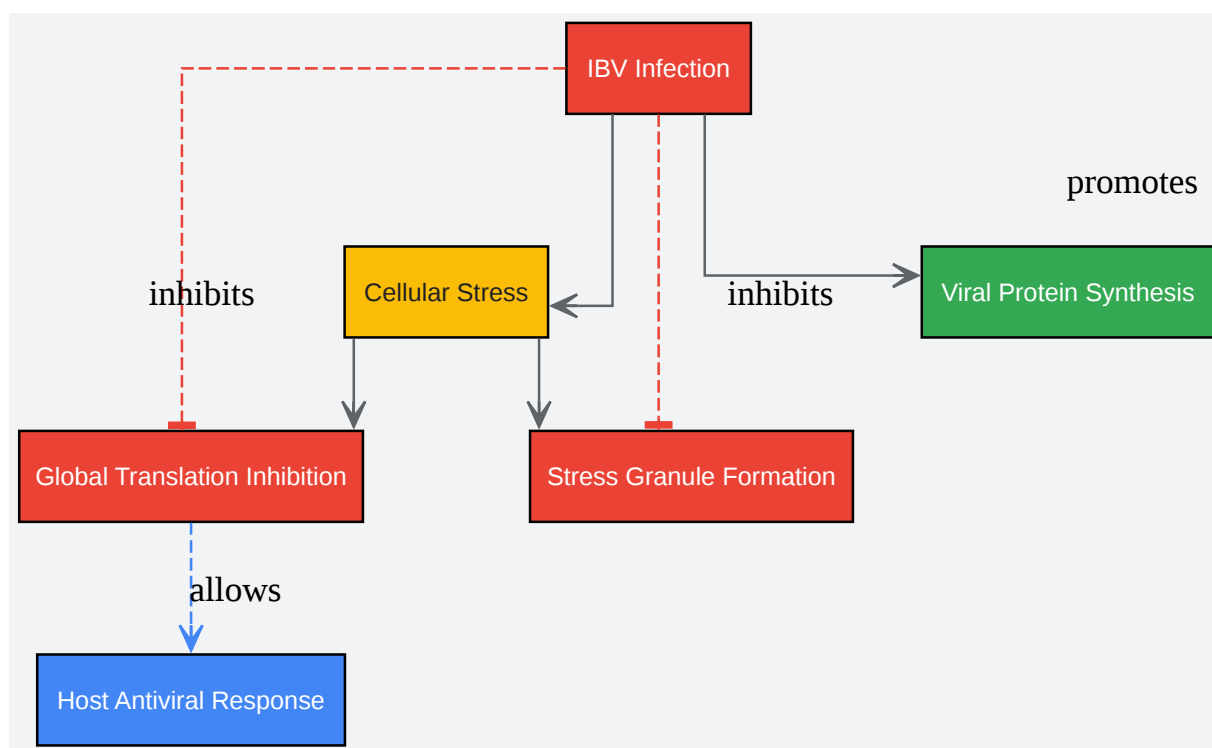


[Click to download full resolution via product page](#)

NDV-induced TLR signaling cascade.

## Infectious Bronchitis Virus (IBV) and Cellular Stress Response

Infectious Bronchitis Virus has been shown to manipulate the host cell's stress response to its advantage. While viral infection typically triggers a shutdown of protein synthesis to inhibit viral replication, IBV can uncouple these signaling pathways, allowing for the continued production of viral proteins.[6]

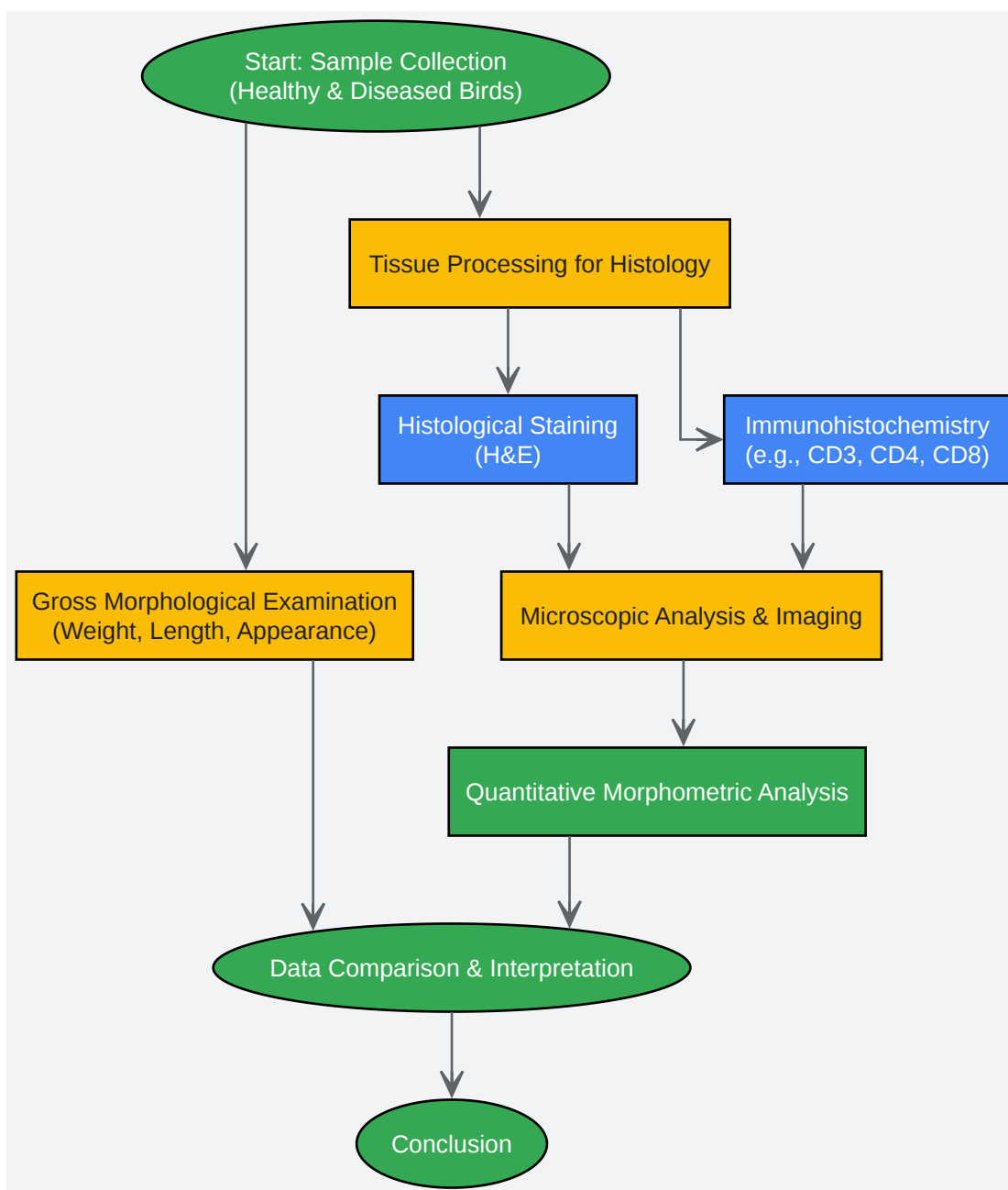


[Click to download full resolution via product page](#)

IBV manipulation of cellular stress.

## Experimental Workflow for Comparative Magnum Morphology Study

The following diagram illustrates a typical workflow for a comparative study of **magnum** morphology.



[Click to download full resolution via product page](#)

Workflow for **magnum** morphology study.

#### Need Custom Synthesis?

BenchChem offers custom synthesis for rare earth carbides and specific isotopic labeling.

Email: [info@benchchem.com](mailto:info@benchchem.com) or [Request Quote Online](#).

## References

- 1. academic.oup.com [academic.oup.com]
- 2. researchgate.net [researchgate.net]
- 3. Strong inflammatory responses and apoptosis in the oviducts of egg-laying hens caused by genotype VIlId Newcastle disease virus - PMC [pmc.ncbi.nlm.nih.gov]
- 4. The Potential of Toll-Like Receptors to Modulate Avian Immune System: Exploring the Effects of Genetic Variants and Phytonutrients - PMC [pmc.ncbi.nlm.nih.gov]
- 5. TGF- $\beta$  Signaling - PMC [pmc.ncbi.nlm.nih.gov]
- 6. rjpbcs.com [rjpbcs.com]
- To cite this document: BenchChem. [A comparative study of magnum morphology in healthy vs. diseased birds.]. BenchChem, [2025]. [Online PDF]. Available at: [https://www.benchchem.com/product/b12768669#a-comparative-study-of-magnum-morphology-in-healthy-vs-diseased-birds]

---

### Disclaimer & Data Validity:

The information provided in this document is for Research Use Only (RUO) and is strictly not intended for diagnostic or therapeutic procedures. While BenchChem strives to provide accurate protocols, we make no warranties, express or implied, regarding the fitness of this product for every specific experimental setup.

**Technical Support:** The protocols provided are for reference purposes. Unsure if this reagent suits your experiment? [[Contact our Ph.D. Support Team for a compatibility check](#)]

**Need Industrial/Bulk Grade?** [Request Custom Synthesis Quote](#)

## BenchChem

Our mission is to be the trusted global source of essential and advanced chemicals, empowering scientists and researchers to drive progress in science and industry.

### Contact

Address: 3281 E Guasti Rd

Ontario, CA 91761, United States

Phone: (601) 213-4426

Email: [info@benchchem.com](mailto:info@benchchem.com)

