

# Common pitfalls in Indium-111 SPECT imaging and how to avoid them

**Author:** BenchChem Technical Support Team. **Date:** December 2025

## Compound of Interest

Compound Name: Indium IN-111 chloride

Cat. No.: B12762705

[Get Quote](#)

## Indium-111 SPECT Imaging: Technical Support Center

This technical support center provides troubleshooting guides and frequently asked questions (FAQs) to help researchers, scientists, and drug development professionals overcome common pitfalls in Indium-111 ( $^{111}\text{In}$ ) SPECT imaging.

### Section 1: Image Acquisition & Reconstruction Artifacts

This section addresses issues arising during the image acquisition and reconstruction process, which can significantly impact image quality and quantitative accuracy.

#### Frequently Asked Questions (FAQs)

Q1: What are the primary challenges in  $^{111}\text{In}$  SPECT imaging due to its decay characteristics?

A1: Indium-111 decays by electron capture with a half-life of 2.8 days and emits two primary gamma photons at 171 keV and 245 keV.[1][2][3] This dual-photon emission presents significant challenges, primarily photon scatter and down-scatter from the 245 keV peak into the 171 keV energy window, which can degrade image quality and quantitative accuracy.[4] Attenuation correction is also more complex compared to single-photon emitters.[5]

Q2: What causes "ring artifacts" in reconstructed SPECT images and how can they be prevented?

A2: Ring artifacts are primarily caused by non-uniformity in the gamma camera's response to a uniform field of radiation.[6] These image defects, even if subtle in planar images, are amplified during the tomographic reconstruction process.[7] To prevent these artifacts, a rigorous quality control program is essential. This includes daily uniformity checks using a flood source to ensure the system's sensitivity response is uniform across the entire detector surface.[6][8]

Q3: How does photon attenuation affect  $^{111}\text{In}$  SPECT images, and what are the common correction methods?

A3: Photon attenuation, the absorption or deflection of photons as they pass through tissue, can lead to image degradation and inaccuracies in quantifying radionuclide uptake.[5][9] For  $^{111}\text{In}$ , this is complicated by its two different photon energies.[5] Common correction methods include:

- CT-based Attenuation Correction: Using a separately acquired CT scan to create an attenuation map. This method can improve the homogeneity of tracer distribution in the reconstructed images.[10][11] However, inaccurate maps can introduce their own artifacts.[12]
- Differential Attenuation Method (DAM): This method estimates attenuation from the observed ratio of the two photopeak intensities, using the known difference in attenuation at the two energies.[13]
- Effective Attenuation Coefficient: This approach treats the dual emissions from  $^{111}\text{In}$  as a single photon with an effective energy (e.g., 210 keV), simplifying the correction process.[5]

Q4: What is photon scatter and how is it corrected in  $^{111}\text{In}$  imaging?

A4: Photon scatter occurs when gamma rays are deflected from their original path, leading to a loss of image contrast and quantitative accuracy.[14] In  $^{111}\text{In}$  imaging, a significant challenge is the down-scatter from the higher energy 245 keV photons into the lower 171 keV energy window.[4] Scatter correction is crucial and often involves multiple-energy window acquisition methods.[14] One common technique is the Triple-Energy Window (TEW) method, which uses scatter windows adjacent to the photopeak window to estimate and subtract the scatter

contribution.[1][15] Using both photopeak energy windows for imaging can lead to improved image contrast with a reasonable level of noise.[14]

## Troubleshooting Guide: Image Artifacts

Problem: My reconstructed SPECT images show poor contrast, "hot" or "cold" spots that don't correspond to expected biodistribution, or visible artifacts like rings or streaks.

Potential Cause	Troubleshooting Steps	Recommended Action
Patient Motion	Review rotating planar projection images (sinogram) for any misalignments or abrupt shifts.	If motion is detected, consider re-acquiring the scan if feasible. For future scans, ensure the patient is comfortable and immobilized. Motion correction software can sometimes be applied post-acquisition. <a href="#">[9]</a>
Photon Attenuation	Observe if there is reduced activity in deeper tissues or areas shadowed by dense tissue (e.g., liver, bone). <a href="#">[9]</a>	Apply a validated attenuation correction method. If using CT-based correction, visually inspect the attenuation map for artifacts (e.g., from metallic implants, truncation) before applying it to the emission data. <a href="#">[12]</a> <a href="#">[16]</a>
Scatter Contamination	Images appear "blurry" with low contrast, especially around areas of high activity.	Implement a scatter correction technique, such as the dual-energy window or TEW method. Ensure energy windows are correctly set. <a href="#">[1]</a> <a href="#">[14]</a>
Camera Non-Uniformity	Concentric rings or "bullseye" artifacts are visible in the reconstructed images. <a href="#">[6]</a>	Perform a high-count flood uniformity test as part of your daily quality control. If non-uniformity is confirmed, the system requires recalibration by a qualified service engineer. <a href="#">[7]</a> <a href="#">[8]</a>
Reconstruction Errors	Artifacts appear after applying specific filters or reconstruction algorithms.	Review reconstruction parameters. For example, using a 3D low-pass filter can sometimes improve diagnostic results for certain studies. <a href="#">[17]</a>

Experiment with different reconstruction algorithms (e.g., iterative vs. filtered backprojection) as iterative methods may reduce some artifacts.[\[12\]](#)

---

## Section 2: Radiopharmaceutical Preparation & Quality Control

This section focuses on pitfalls related to the preparation and quality control of  $^{111}\text{In}$ -labeled agents, which are critical for successful imaging.

### Frequently Asked Questions (FAQs)

Q1: What are the common methods for radiolabeling molecules with Indium-111?

A1: Since radiometals like  $^{111}\text{In}$  cannot be directly incorporated into proteins or peptides, bifunctional chelators are used.[\[18\]](#)[\[19\]](#) A chelator is first attached to the targeting molecule (e.g., an antibody), and then the  $^{111}\text{In}$  is introduced to form a stable complex.[\[2\]](#) Common chelators include DTPA (diethylenetriaminepentaacetic acid) and DOTA (dodecane tetraacetic acid).[\[18\]](#)[\[20\]](#) Macrocyclic chelators like DOTA are often favored for in vivo use due to their higher stability compared to acyclic chelators.[\[18\]](#)[\[19\]](#)

Q2: What can cause low radiolabeling efficiency?

A2: Several factors can lead to poor labeling efficiency:

- pH of the reaction mixture: The optimal pH for chelation is crucial. For example, labeling with DTPA or DOTA is often carried out in a slightly acidic buffer (e.g., pH 5.5).[\[18\]](#)
- Presence of metal contaminants: Trace metal ions in buffers or on glassware can compete with  $^{111}\text{In}$  for the chelator, reducing the yield of the desired radiolabeled product.
- Incorrect temperature or incubation time: Labeling reactions have optimal temperature and time requirements. For instance, DTPA labeling may be done at  $37^\circ\text{C}$  for 1 hour, while DOTA may require longer incubation.[\[18\]](#)

- Radiopharmaceutical purity: The radiochemical purity of the final product should be tested before administration and should typically be greater than 90%.[21]

Q3: How do I ensure the in vivo stability of my  $^{111}\text{In}$ -labeled agent?

A3: The stability of the radiometal-chelator complex is critical to prevent the release of free  $^{111}\text{In}$ , which can lead to off-target accumulation and misinterpretation of images. In vivo stability is largely determined by the choice of chelator.[18][19] Post-labeling quality control should include stability tests, for example, by challenging the labeled compound with a strong competing chelator like EDTA over time to assess the retention of  $^{111}\text{In}$ .[19]

## Experimental Protocol: Basic Quality Control of $^{111}\text{In}$ -Pentetreotide

This protocol is a simplified example for assessing the radiochemical purity of  $^{111}\text{In}$ -pentetreotide, a common radiopharmaceutical.

- Objective: To determine the percentage of  $^{111}\text{In}$  that is successfully bound to the pentetreotide peptide.
- Materials:
  - $^{111}\text{In}$ -pentetreotide solution (final prepared product).
  - Sep-Pak C18 cartridge.
  - Ethanol.
  - Distilled water.
  - Dose calibrator or gamma counter.
- Methodology:
  1. Cartridge Preparation: Pre-rinse the Sep-Pak C18 cartridge with 5 mL of ethanol, followed by 5 mL of distilled water.

2. Sample Application: Apply a small, known volume (e.g., 100 µL) of the prepared <sup>111</sup>In-pentetreotide solution to the top of the cartridge.
  3. Elution of Impurities: Elute the cartridge with 5 mL of distilled water and collect the eluate. This fraction will contain unbound (free) <sup>111</sup>In.
  4. Elution of Labeled Product: Elute the cartridge with 5 mL of ethanol and collect this second eluate. This fraction contains the bound <sup>111</sup>In-pentetreotide. The cartridge itself will retain any colloidal impurities.
  5. Counting: Measure the radioactivity in the "free <sup>111</sup>In" fraction, the "bound <sup>111</sup>In-pentetreotide" fraction, and the cartridge using a gamma counter.
- Calculation:
    - Radiochemical Purity (%) =  $\left[ \frac{\text{Activity of Bound Fraction}}{\text{Activity of Bound Fraction} + \text{Activity of Free Fraction} + \text{Activity on Cartridge}} \right] \times 100$
  - Acceptance Criteria: The radiochemical purity should be >90% before patient administration. [\[21\]](#)

## Section 3: Patient-Related Pitfalls

Patient preparation and physiological factors can introduce significant artifacts and pitfalls in <sup>111</sup>In SPECT imaging.

## Frequently Asked Questions (FAQs)

Q1: What are the most common patient-related artifacts in SPECT imaging?

A1: The most common patient-related artifacts are due to patient motion and soft tissue attenuation.[\[9\]](#) Patient motion can cause blurring and misregistration artifacts, while attenuation from soft tissues like the breasts or diaphragm can create apparent "cold spots" that may be mistaken for pathology.[\[9\]](#)[\[22\]](#)

Q2: What kind of patient preparation is required for <sup>111</sup>In imaging?

A2: Patient preparation varies depending on the specific agent and clinical question. For abdominal imaging with agents like  $^{111}\text{In}$ -pentetretotide or  $^{111}\text{In}$ -labeled leukocytes, physiologic bowel activity can obscure or be mistaken for abnormal uptake.<sup>[22][23]</sup> Therefore, patient preparation may include the use of laxatives or an enema to cleanse the bowel before imaging.<sup>[17]</sup> For some studies, fasting may be required.<sup>[24]</sup>

Q3: Can normal physiological uptake of  $^{111}\text{In}$ -labeled agents be mistaken for pathology?

A3: Yes, this is a common pitfall.  $^{111}\text{In}$ -labeled leukocytes, for example, normally accumulate in the liver, spleen, and bone marrow.<sup>[25]</sup> Accumulation in the colon has also been observed and can be a source of false-positive diagnoses.<sup>[23]</sup> Similarly, for somatostatin receptor imaging with  $^{111}\text{In}$ -pentetretotide, high physiological uptake is seen in the kidneys and spleen, which can sometimes make it difficult to detect tumors in or near these organs.<sup>[21]</sup> Delayed imaging (e.g., at 24 or 48 hours) can be helpful as it often provides a higher target-to-background ratio.<sup>[3][21]</sup>

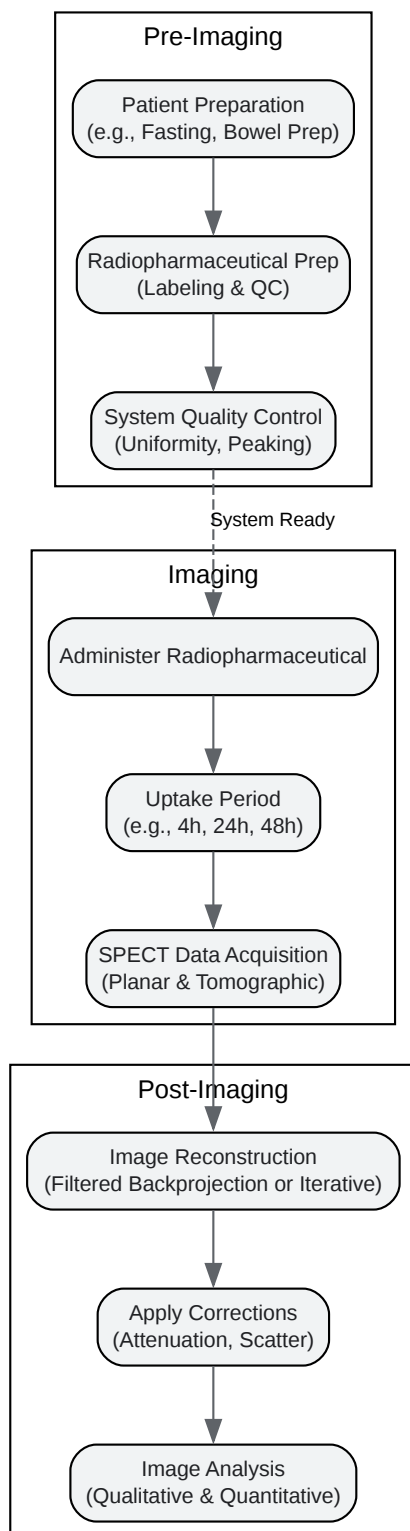
## Troubleshooting Guide: Differentiating Physiological Uptake from Pathology

Observed Uptake Location	Potential Pitfall	Recommended Action / Differentiation Strategy
Abdomen/Pelvis (diffuse, changing)	Bowel Activity: Physiologic excretion of the radiotracer into the gut.	Perform delayed imaging (e.g., at 24 or 48 hours). Bowel activity will typically move or decrease over time, whereas pathological uptake is usually fixed. SPECT/CT can provide anatomical localization to confirm activity is within the bowel lumen. <a href="#">[21]</a> <a href="#">[22]</a>
Spleen, Liver, Bone Marrow	Normal Biodistribution: Expected high physiological uptake for many <sup>111</sup> In-labeled cells and peptides. <a href="#">[25]</a> <a href="#">[26]</a>	Compare the intensity of uptake to expected normal patterns. SPECT/CT is invaluable for precise anatomical correlation. For suspected liver lesions with <sup>111</sup> In-pentetreotide, uptake may be isointense with normal liver tissue, making SPECT essential. <a href="#">[21]</a>
Kidneys	Renal Excretion: High uptake is normal for agents like <sup>111</sup> In-pentetreotide.	SPECT/CT can help differentiate uptake within the renal parenchyma from an adjacent adrenal or retroperitoneal lesion. <a href="#">[21]</a>
Injection Site	Extravasation Artifact: A "hot spot" at the injection site due to subcutaneous infiltration of the radiotracer. <a href="#">[27]</a> <a href="#">[28]</a>	Document the injection site. The appearance is typically intense and localized. It can sometimes lead to uptake in ipsilateral lymph nodes. <a href="#">[28]</a>

## Section 4: Visual Guides and Workflows

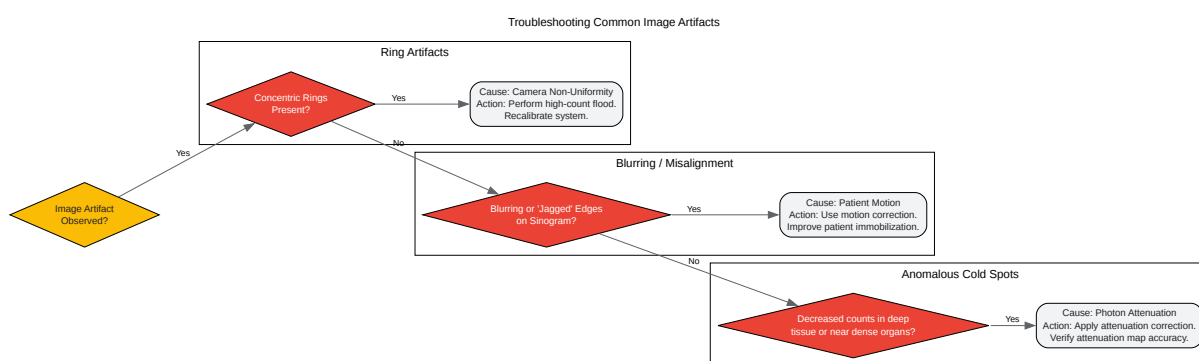
## Diagrams

General Workflow for an In-111 SPECT Imaging Experiment



[Click to download full resolution via product page](#)

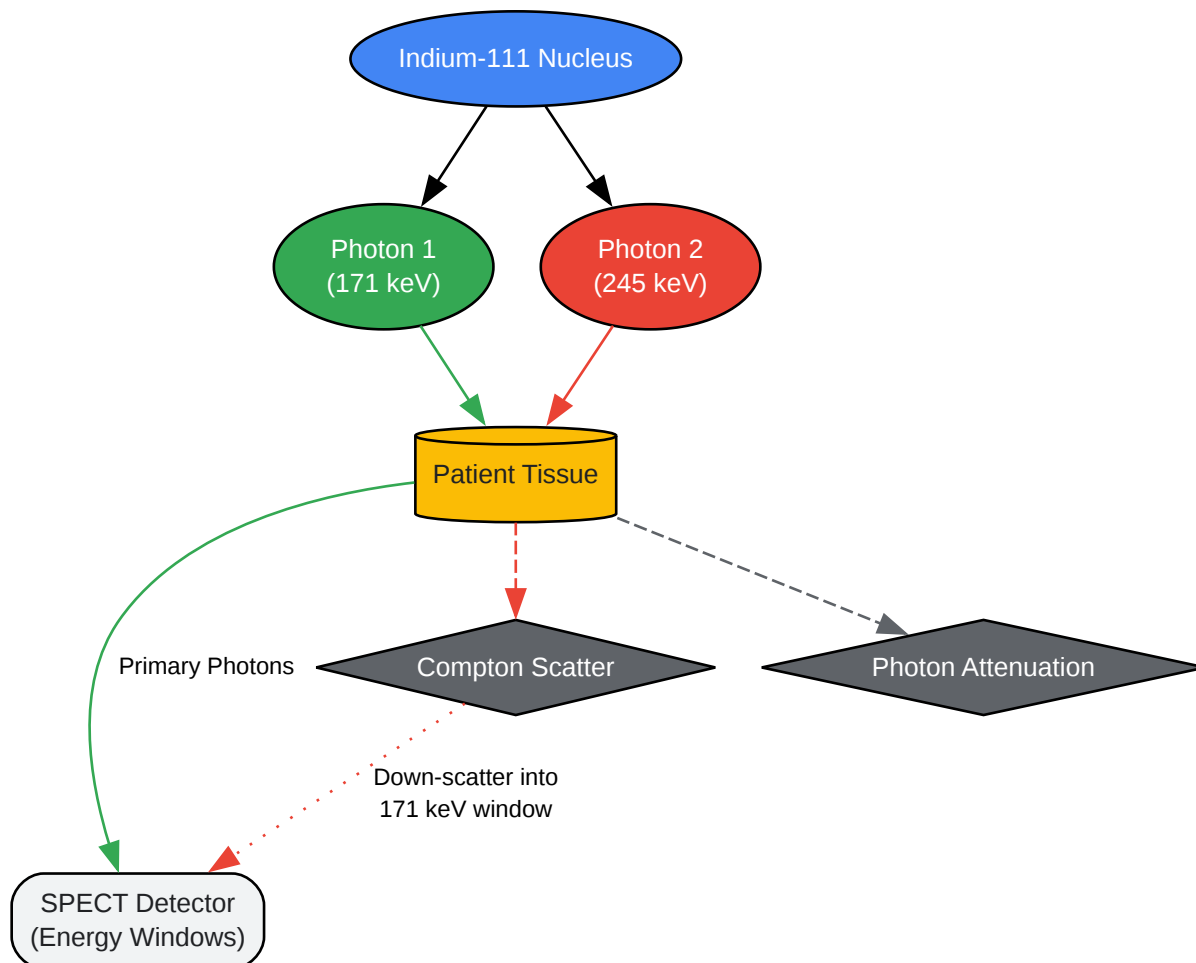
Caption: A typical experimental workflow for Indium-111 SPECT imaging.



[Click to download full resolution via product page](#)

Caption: A decision tree for troubleshooting common SPECT image artifacts.

## Challenges of Dual-Photon Emission in In-111 SPECT

[Click to download full resolution via product page](#)

Caption: The dual-photon emission of In-111 leads to scatter and attenuation.

**Need Custom Synthesis?**

BenchChem offers custom synthesis for rare earth carbides and specific isotopic labeling.

Email: [info@benchchem.com](mailto:info@benchchem.com) or [Request Quote Online](#).

## References

- 1. Assessment of Four Scatter Correction Methods in In-111 SPECT Imaging: A Simulation Study - PMC [pmc.ncbi.nlm.nih.gov]

- 2. Indium-111 - Wikipedia [en.wikipedia.org]
- 3. taylorandfrancis.com [taylorandfrancis.com]
- 4. researchgate.net [researchgate.net]
- 5. Calculation and validation of the use of effective attenuation coefficient for attenuation correction in In-111 SPECT - PubMed [pubmed.ncbi.nlm.nih.gov]
- 6. aapm.org [aapm.org]
- 7. osti.gov [osti.gov]
- 8. Quality Control in SPECT and PET Imaging | Thoracic Key [thoracickey.com]
- 9. Recognizing and preventing artifacts with SPECT and PET imaging | Radiology Key [radiologykey.com]
- 10. researchgate.net [researchgate.net]
- 11. juser.fz-juelich.de [juser.fz-juelich.de]
- 12. Problems created in attenuation-corrected SPECT images by artifacts in attenuation maps: a simulation study - PubMed [pubmed.ncbi.nlm.nih.gov]
- 13. Scatter and attenuation correction for 111In based on energy spectrum fitting - PubMed [pubmed.ncbi.nlm.nih.gov]
- 14. Assessment of Four Scatter Correction Methods in In-111 SPECT Imaging: A Simulation Study - PubMed [pubmed.ncbi.nlm.nih.gov]
- 15. A modified TEW approach to scatter correction for In-111 and Tc-99m dual-isotope small-animal SPECT - PubMed [pubmed.ncbi.nlm.nih.gov]
- 16. Multi-modality nuclear medicine imaging: artefacts, pitfalls and recommendations - PMC [pmc.ncbi.nlm.nih.gov]
- 17. Technical considerations for acquiring and processing indium-111 capromab pendetide images - PubMed [pubmed.ncbi.nlm.nih.gov]
- 18. Indium-111 radiolabelling of a brain-penetrant A $\beta$  antibody for SPECT imaging | Upsala Journal of Medical Sciences [ujms.net]
- 19. ujms.net [ujms.net]
- 20. alfa-rdtrial.com [alfa-rdtrial.com]
- 21. carcinoid.org [carcinoid.org]
- 22. scholarscompass.vcu.edu [scholarscompass.vcu.edu]
- 23. Possible pitfalls with clinical imaging of indium-111 leukocytes: concise communication - PubMed [pubmed.ncbi.nlm.nih.gov]

- 24. Preparing for Your Nuclear Medicine Procedure | University of Utah Health [healthcare.utah.edu]
- 25. jnm.snmjournals.org [jnm.snmjournals.org]
- 26. Indium-111 radiolabelling of a brain-penetrant A $\beta$  antibody for SPECT imaging - PubMed [pubmed.ncbi.nlm.nih.gov]
- 27. Nuclear Medicine Artifacts - StatPearls - NCBI Bookshelf [ncbi.nlm.nih.gov]
- 28. med.emory.edu [med.emory.edu]
- To cite this document: BenchChem. [Common pitfalls in Indium-111 SPECT imaging and how to avoid them]. BenchChem, [2025]. [Online PDF]. Available at: [https://www.benchchem.com/product/b12762705#common-pitfalls-in-indium-111-spect-imaging-and-how-to-avoid-them]

---

#### Disclaimer & Data Validity:

The information provided in this document is for Research Use Only (RUO) and is strictly not intended for diagnostic or therapeutic procedures. While BenchChem strives to provide accurate protocols, we make no warranties, express or implied, regarding the fitness of this product for every specific experimental setup.

**Technical Support:** The protocols provided are for reference purposes. Unsure if this reagent suits your experiment? [[Contact our Ph.D. Support Team for a compatibility check](#)]

**Need Industrial/Bulk Grade?** [Request Custom Synthesis Quote](#)

## BenchChem

Our mission is to be the trusted global source of essential and advanced chemicals, empowering scientists and researchers to drive progress in science and industry.

#### Contact

Address: 3281 E Guasti Rd  
Ontario, CA 91761, United States  
Phone: (601) 213-4426  
Email: [info@benchchem.com](mailto:info@benchchem.com)