

Technical Support Center: Managing Radiation Necrosis After Iotrex (131I-rituximab) Treatment

Author: BenchChem Technical Support Team. **Date:** December 2025

Compound of Interest

Compound Name: Iotrex

Cat. No.: B1264771

[Get Quote](#)

This technical support center provides guidance for researchers, scientists, and drug development professionals investigating the effects of **Iotrex** (131I-rituximab) and managing the potential complication of radiation necrosis in a preclinical research setting.

Frequently Asked Questions (FAQs)

Q1: What is the underlying mechanism of radiation necrosis following radioimmunotherapy?

A1: Radiation necrosis is a delayed complication resulting from radiation-induced damage to the brain parenchyma. The primary mechanism is thought to be initial damage to vascular endothelial cells and glial cells, particularly oligodendrocytes.[1][2][3] This initial injury triggers a cascade of events including inflammation, disruption of the blood-brain barrier, and local ischemia.[3] Hypoxia ensues, leading to the upregulation of Hypoxia-Inducible Factor-1 alpha (HIF-1 α) and subsequently Vascular Endothelial Growth Factor (VEGF) in reactive astrocytes.[1][4][5] This surge in VEGF promotes the formation of leaky, fragile blood vessels, which contributes to vasogenic edema and perpetuates the cycle of tissue damage and necrosis, predominantly affecting the white matter.[2][4]

Q2: In a preclinical model, what is the typical timeframe for the onset of radiation necrosis after irradiation?

A2: The onset of radiation necrosis is dose-dependent. In rodent models using high-dose, single-fraction stereotactic radiosurgery, evidence of radiation injury on gadolinium-enhanced MRI can be identified as early as 2 weeks post-irradiation with doses of 140 Gy.[6] With lower

doses, the onset is delayed; for example, at 100 Gy, injury may be seen at 4 to 6 weeks, and at 60 Gy, it can take up to 8 months.^[6] It's crucial to establish a timeline specific to your experimental model and radiation delivery method.

Q3: How can radiation necrosis be distinguished from tumor progression in animal models?

A3: Differentiating radiation necrosis from tumor progression is a significant challenge as they can appear similar on conventional MRI (e.g., contrast-enhancing lesions).^{[7][8][9]} Advanced imaging techniques are often required for better differentiation. Multi-parametric MRI, including methods like Diffusion-Weighted Imaging (DWI), perfusion imaging, and Chemical Exchange Saturation Transfer (CEST), can provide physiological information to help distinguish the two conditions.^{[8][10]} For instance, some studies suggest that metrics like the Apparent Diffusion Coefficient (ADC) and initial Area Under the Curve (iAUC) from perfusion MRI can be effective discriminators.^[10] PET imaging using amino acid tracers can also be valuable, as tumors typically show higher metabolic activity than necrotic tissue.^{[4][9]} Ultimately, histopathological analysis remains the gold standard for definitive diagnosis.^{[3][7]}

Q4: What is the rationale for using anti-VEGF agents like bevacizumab to manage radiation necrosis?

A4: The rationale is based on the central role of VEGF in the pathophysiology of radiation necrosis.^{[5][11]} As described in Q1, radiation-induced hypoxia leads to a significant upregulation of VEGF, which increases vascular permeability and edema.^{[1][4]} Bevacizumab is a monoclonal antibody that targets and neutralizes VEGF-A.^[12] By blocking VEGF, bevacizumab is hypothesized to restore the integrity of the blood-brain barrier, reduce vascular leakage and associated edema, thereby mitigating the effects of radiation necrosis.^[13] Preclinical and clinical studies have shown that bevacizumab can lead to a significant reduction in lesion volume on MRI and clinical improvement.^{[5][13][14]}

Troubleshooting Guides

Problem: High variability in the incidence and time-to-onset of radiation necrosis in our rodent model.

Possible Cause	Suggested Solution
Inconsistent Radiation Dosing/Targeting	Ensure precise and reproducible radiation delivery. Use a stereotactic setup with image guidance (e.g., micro-CT) for accurate targeting of the brain region. ^[7] Regularly calibrate the radiation source to ensure consistent dose delivery.
Animal Strain/Age Differences	Use a consistent age and a single, well-characterized strain of animal for all experiments. Genetic background can influence radiation sensitivity.
Health Status of Animals	Monitor the health of the animals closely. Underlying health issues can affect their response to radiation. Ensure standardized housing and husbandry conditions.
Model-Specific Factors	The specific characteristics of your tumor model (if used) can influence the development of necrosis. A model that combines radiation necrosis with a viable tumor may be more clinically relevant. ^[7]

Problem: Inconclusive results from MRI scans for differentiating necrosis from tumor recurrence.

Possible Cause	Suggested Solution
Reliance on Conventional MRI Alone	Standard T1-weighted contrast-enhanced and T2-weighted MRI often cannot reliably distinguish between the two conditions. [7] [8]
Suboptimal Imaging Parameters	Optimize advanced imaging protocols for your specific scanner and animal model. This may involve adjusting parameters for DWI, perfusion MRI, or CEST sequences. [8]
Lack of Quantitative Analysis	Implement quantitative analysis of your imaging data. Instead of relying solely on visual assessment, calculate metrics such as ADC values, cerebral blood volume, or amide proton transfer ratios. [10]
Need for Correlative Data	Correlate imaging findings with histology. Sacrificing a subset of animals at various time points to compare imaging with pathological findings can help validate your imaging-based assessments. [7]

Quantitative Data Summary

Table 1: Comparison of Imaging Parameters for Differentiating Radiation Necrosis (RN) vs. Brain Tumor (BT) in a Rodent Model

MRI Parameter	Modality	Typical Finding in RN	Typical Finding in BT	Discriminatory Power	Reference
ADC	Diffusion MRI	Higher	Lower	Good	[10]
iAUC	Perfusion MRI	Lower	Higher	Good	[10]
APT	CEST MRI	Lower	Higher	Promising	[8] [10]
FDG Uptake	PET	Hypometabolism	Hypermetabolism	Variable	[4] [9]
Amino Acid Tracer Uptake	PET	Low	High	Promising	[4]

ADC: Apparent Diffusion Coefficient; iAUC: initial Area Under the Curve; APT: Amide Proton Transfer; CEST: Chemical Exchange Saturation Transfer; FDG: Fluorodeoxyglucose; PET: Positron Emission Tomography.

Table 2: Efficacy of Bevacizumab in Preclinical and Clinical Settings for Radiation Necrosis

Study Type	Bevacizumab Dose	Key Outcomes	Reference
Preclinical (Mouse Model)	N/A	Decreased lesion volumes on T1- and T2-weighted MRI; ADC values returned to normal range.	[13]
Clinical (Systematic Review)	5 - 7.5 mg/kg	Radiographic response in ~85-97% of patients; significant reduction in edema.	[5]
Clinical (Phase II Study)	Ultra-low-dose (1 mg/kg)	High efficacy in reducing lesion volume and edema.	[15][16]
Clinical (Prospective Trial)	2.5 mg/kg (intra-arterial)	>75% reduction in RN volume at 12 months.	[14]

Key Experimental Protocols

Protocol 1: Induction of a Rodent Model of Radiation Necrosis

This protocol is adapted from methodologies using a clinical linear accelerator (LINAC) for stereotactic radiosurgery in rodents.[6][10]

- **Animal Preparation:** Anesthetize the animal (e.g., male Fisher 344 rat) using an isoflurane/oxygen mixture. Secure the animal in a stereotactic frame to prevent motion.
- **Imaging for Treatment Planning:** Acquire a planning CT scan. If available, fuse these images with a pre-acquired MRI for better anatomical delineation of the target area (e.g., one hemisphere of the brain).
- **Treatment Planning:** Using appropriate software, define the target volume. Generate a treatment plan using multiple non-coplanar arcs to deliver a high, focal dose of radiation (e.g., a single fraction of 140 Gy) to the isocenter while minimizing dose to surrounding tissues.[10]

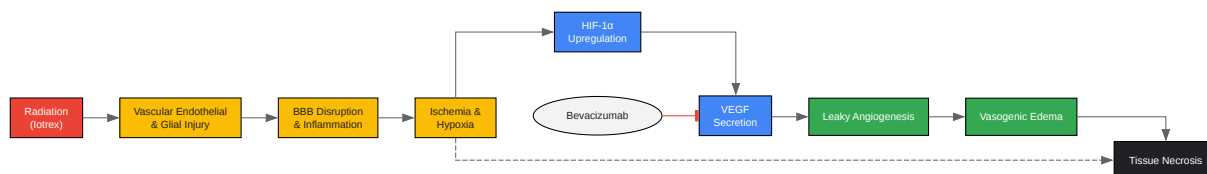
- **Radiation Delivery:** Position the animal on the treatment couch. Use on-board imaging (e.g., Cone Beam CT) to verify the animal's position against the treatment plan and make any necessary adjustments. Deliver the radiation according to the approved plan.
- **Post-Procedure Monitoring:** Monitor the animal's recovery from anesthesia. Provide supportive care as needed. Follow the animal for the planned duration of the experiment, with regular monitoring for any neurological symptoms.

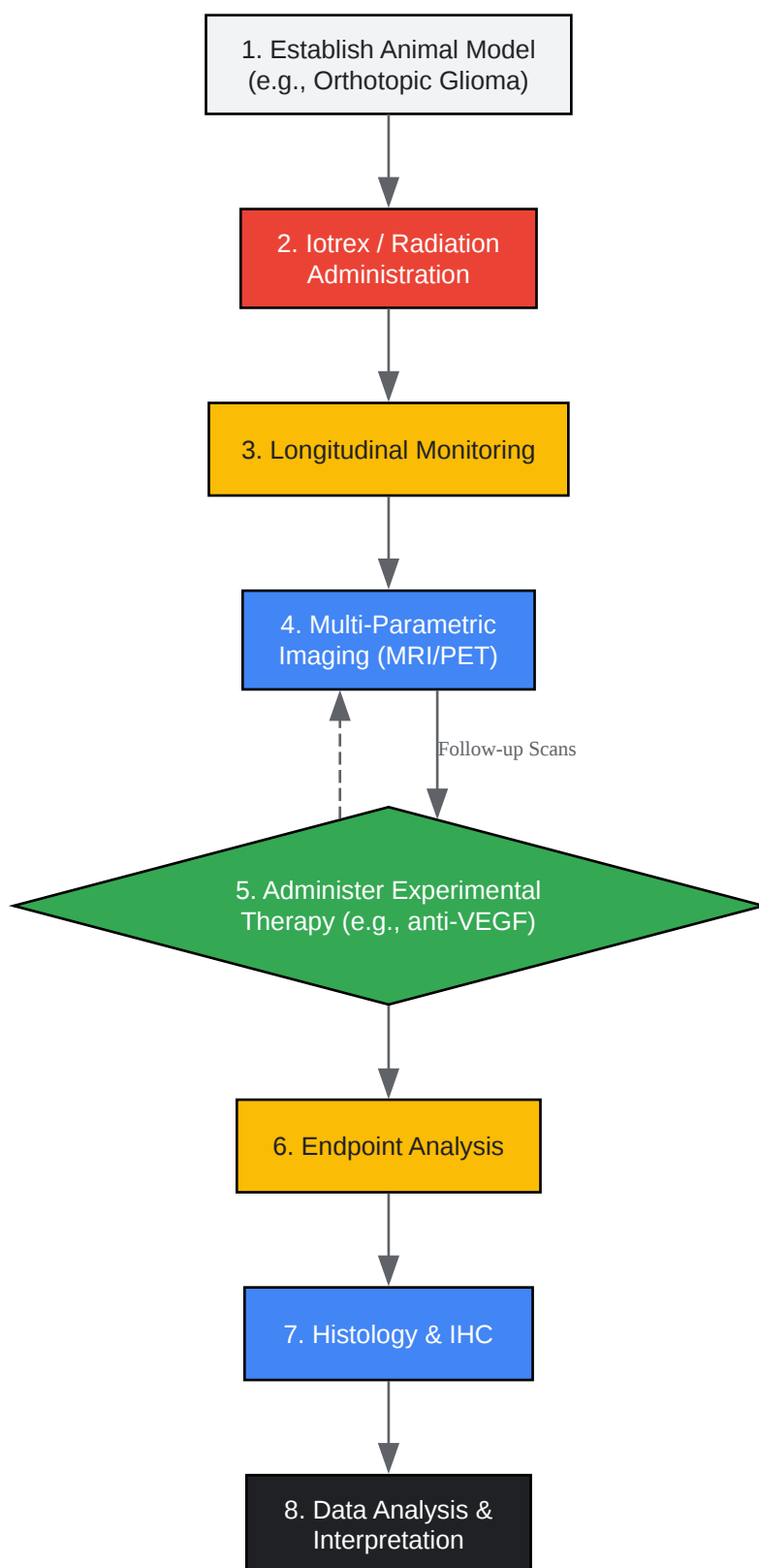
Protocol 2: Immunohistochemical Staining for Necrosis and Hypoxia Markers

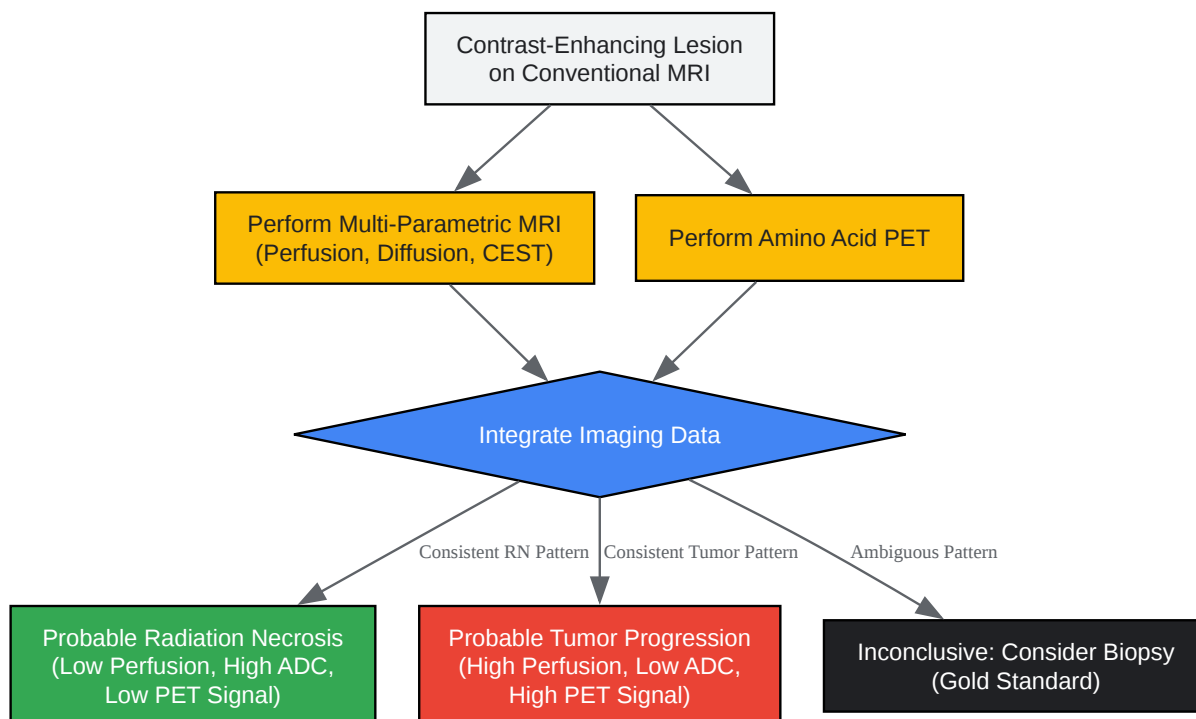
- **Tissue Preparation:** Following euthanasia, perfuse the animal transcardially with saline followed by 10% formalin.^[6] Harvest the brain and post-fix in formalin before transferring to 70% ethanol. Process the tissue and embed in paraffin.
- **Sectioning:** Cut 5-10 μm thick sections from the paraffin-embedded blocks. Mount the sections on charged glass slides.
- **Deparaffinization and Rehydration:** Deparaffinize the sections in xylene and rehydrate through a graded series of ethanol to water.
- **Antigen Retrieval:** Perform heat-induced epitope retrieval using an appropriate buffer (e.g., citrate buffer, pH 6.0).
- **Staining:**
 - Perform a Hematoxylin and Eosin (H&E) stain on a representative section to visualize general morphology, areas of necrosis, and vascular changes.^{[7][17]}
 - For specific markers, block endogenous peroxidase activity and non-specific binding sites.
 - Incubate sections with primary antibodies overnight at 4°C. Key antibodies include:
 - VEGF: To assess angiogenesis and vascular permeability.^[4]
 - HIF-1 α : As a marker for hypoxia.^{[4][13]}
 - CD31: To identify endothelial cells.^[18]

- GFAP: To identify reactive astrocytes.
- Iba1: To identify activated microglia/macrophages.
- Detection and Visualization: Use a suitable secondary antibody and detection system (e.g., DAB chromogen). Counterstain with hematoxylin.
- Analysis: Dehydrate, clear, and coverslip the slides. Examine under a microscope to assess the expression and localization of each marker within the necrotic lesion and surrounding tissue.

Visualizations







[Click to download full resolution via product page](#)

Need Custom Synthesis?

BenchChem offers custom synthesis for rare earth carbides and specific isotopic labeling.

Email: info@benchchem.com or [Request Quote Online](#).

References

- 1. Treatment of Radiation-Induced Brain Necrosis - PMC [pmc.ncbi.nlm.nih.gov]
- 2. Radiation Necrosis: Background, Pathophysiology, Epidemiology [emedicine.medscape.com]
- 3. mdpi.com [mdpi.com]
- 4. Pathophysiology, Diagnosis, and Treatment of Radiation Necrosis in the Brain - PMC [pmc.ncbi.nlm.nih.gov]
- 5. Frontiers | Bevacizumab Treatment of Radiation-Induced Brain Necrosis: A Systematic Review [frontiersin.org]

- 6. Rodent Model of Brain Radionecrosis Using Clinical LINAC-Based Stereotactic Radiosurgery - PMC [pmc.ncbi.nlm.nih.gov]
- 7. Development of a novel animal model to differentiate radiation necrosis from tumor recurrence - PMC [pmc.ncbi.nlm.nih.gov]
- 8. aacrjournals.org [aacrjournals.org]
- 9. Radiation Necrosis Workup: Imaging Studies, Procedures, Histologic Findings [emedicine.medscape.com]
- 10. Towards differentiation of brain tumor from radiation necrosis using multi-parametric MRI: Preliminary results at 4.7T using rodent models - PMC [pmc.ncbi.nlm.nih.gov]
- 11. The role of VEGF receptor inhibitors in preventing cerebral radiation necrosis: a retrospective cohort study - PMC [pmc.ncbi.nlm.nih.gov]
- 12. The role of VEGF receptor inhibitors in preventing cerebral radiation necrosis: a retrospective cohort study - PubMed [pubmed.ncbi.nlm.nih.gov]
- 13. Can anti-Vascular Endothelial Growth Factor Antibody Reverse Radiation Necrosis? A Preclinical Investigation - PMC [pmc.ncbi.nlm.nih.gov]
- 14. nortonhealthcareprovider.com [nortonhealthcareprovider.com]
- 15. scienceopen.com [scienceopen.com]
- 16. Ultra-Low-Dose Bevacizumab For Cerebral Radiation Necrosis: A Prospective Phase II Clinical Study - PMC [pmc.ncbi.nlm.nih.gov]
- 17. researchgate.net [researchgate.net]
- 18. researchgate.net [researchgate.net]
- To cite this document: BenchChem. [Technical Support Center: Managing Radiation Necrosis After Iotrex (131I-rituximab) Treatment]. BenchChem, [2025]. [Online PDF]. Available at: [https://www.benchchem.com/product/b1264771#managing-radiation-necrosis-after-iotrex-treatment]

Disclaimer & Data Validity:

The information provided in this document is for Research Use Only (RUO) and is strictly not intended for diagnostic or therapeutic procedures. While BenchChem strives to provide accurate protocols, we make no warranties, express or implied, regarding the fitness of this product for every specific experimental setup.

Technical Support: The protocols provided are for reference purposes. Unsure if this reagent suits your experiment? [[Contact our Ph.D. Support Team for a compatibility check](#)]

Need Industrial/Bulk Grade? [Request Custom Synthesis Quote](#)

BenchChem

Our mission is to be the trusted global source of essential and advanced chemicals, empowering scientists and researchers to drive progress in science and industry.

Contact

Address: 3281 E Guasti Rd
Ontario, CA 91761, United States
Phone: (601) 213-4426
Email: info@benchchem.com