

# GliaSite Catheter Placement: A Technical Support Guide

**Author:** BenchChem Technical Support Team. **Date:** December 2025

## Compound of Interest

Compound Name: *Iotrex*

Cat. No.: *B1264771*

[Get Quote](#)

For Researchers, Scientists, and Drug Development Professionals

This technical support center provides troubleshooting guidance and frequently asked questions (FAQs) to address specific challenges that may arise during the placement of the GliaSite catheter in preclinical research and clinical investigations.

## Troubleshooting Guide

This guide offers a systematic approach to resolving common issues encountered during the GliaSite catheter placement procedure.

### Issue 1: Poor Conformance of the Balloon to the Resection Cavity

**Problem:** Post-inflation imaging (CT or MRI) reveals a significant gap (>1.0 cm) between the balloon surface and the surrounding tissue of the resection cavity.<sup>[1]</sup> This can lead to non-uniform radiation delivery.

Possible Causes:

- Irregularly shaped resection cavity.
- Incorrect balloon size selection.
- Presence of blood clots or residual tumor tissue preventing full balloon-tissue contact.

### Troubleshooting Steps:

- Intraoperative Assessment:
  - Carefully inspect the resection cavity for any irregularities or remaining tissue fragments.
  - Use a Foley catheter to estimate the cavity volume to aid in selecting the appropriate GliaSite balloon size (available in 2, 3, and 4 cm diameters).[\[2\]](#)
- Post-Inflation Imaging Review:
  - If imaging shows poor conformance, consider partially deflating and then reinflating the balloon. This may help it better adapt to the cavity's shape.
  - Reposition the patient's head and acquire new images to see if gravity can aid in settling the balloon against the tissue.
- Advanced Solutions (requiring surgical revision):
  - If significant gaps persist, the balloon may need to be explanted.
  - The surgeon may need to revise the resection cavity to create a more uniform shape.
  - In select cases, based on surgical judgment and cavity geometry, replacing a single large balloon with two smaller balloons might be considered to achieve better overall contact with the tissue surface, a technique that has been adapted for other complex cavities.[\[3\]](#)

## Issue 2: Catheter or Balloon Malposition

**Problem:** The catheter is kinked, or the balloon is not centered within the resection cavity upon imaging.

### Possible Causes:

- Suboptimal catheter tunneling path.
- Patient movement during or after placement.
- Inadequate securing of the infusion port.

**Troubleshooting Steps:**

- Visual Inspection:
  - Examine the external portion of the catheter for any visible kinks.
  - Ensure the infusion port is securely sutured to the skull.
- Imaging Verification:
  - Utilize CT or MRI to confirm the position of the balloon and the catheter track. MRI is generally superior for visualizing the balloon and surrounding soft tissues.[\[1\]](#)[\[4\]](#)
- Repositioning (if feasible):
  - Minor adjustments to the catheter's external slack may resolve some kinks.
  - If the balloon is significantly malpositioned, it may require surgical repositioning or replacement.

## Issue 3: Balloon Inflation Failure

**Problem:** The balloon does not inflate to the expected volume, or there is resistance during inflation.

**Possible Causes:**

- Kink in the catheter.
- Blockage within the catheter lumen.
- Manufacturing defect in the balloon or catheter (rare).

**Troubleshooting Steps:**

- Check for Kinks: Straighten any visible external kinks in the catheter.
- Gentle Saline Flush: Attempt to flush the catheter with a small amount of sterile saline to dislodge any potential blockages. Caution: Do not apply excessive force, as this could

damage the catheter.

- **Inspect Connections:** Ensure all connections between the syringe and the catheter port are secure.
- **Catheter Replacement:** If the balloon still fails to inflate, the catheter is likely obstructed or defective and should be replaced.

## Issue 4: Post-Placement Hemorrhage

**Problem:** Imaging reveals significant bleeding in or around the resection cavity after catheter placement.[\[1\]](#)

**Possible Causes:**

- Inadequate hemostasis during the resection surgery.
- Patient coagulopathy.[\[1\]](#)
- Vascular injury during catheter placement.

**Management:**

- **Immediate Imaging:** CT imaging is crucial to assess the extent of the hemorrhage.[\[1\]](#)
- **Neurosurgical Consultation:** This is a clinical complication that requires immediate neurosurgical evaluation.
- **Device Removal:** In cases of substantial hemorrhage, the GliaSite device may need to be removed to manage the bleeding.[\[1\]](#)
- **Coagulation Correction:** If the patient has a coagulopathy, it should be corrected promptly.

## Frequently Asked Questions (FAQs)

**Q1:** What are the most common complications associated with the GliaSite catheter?

**A1:** Based on clinical trial data, common complications include wound infection, meningitis (bacterial, chemical, or aseptic), and pseudomeningocele.[\[5\]](#)[\[6\]](#) Late complications can include

symptomatic radiation necrosis and, in some cases, brain hemorrhage.[7][8][9]

Q2: How is the correct balloon size determined?

A2: The appropriate balloon size is chosen based on the volume of the resection cavity, which can be measured intraoperatively, often with a Foley catheter. The GliaSite system is available in 2, 3, and 4 cm diameter balloons.[2] The goal is to select a size that will conform well to the surgical cavity.[10]

Q3: What imaging modality is best for assessing GliaSite placement?

A3: While CT can be used, MRI is generally preferred for visualizing the balloon, its conformance to the cavity, and the surrounding brain parenchyma.[1][4] MRI provides better soft-tissue contrast and can help differentiate between post-surgical changes, tumor recurrence, and radiation necrosis in follow-up scans.[4]

Q4: Can the GliaSite catheter be used in irregularly shaped resection cavities?

A4: While the spherical shape of the balloon is ideal for uniform, spherical cavities, it can be used in non-spherical cavities. However, achieving optimal conformance can be challenging. Post-placement imaging is critical to ensure there are no significant gaps between the balloon and the tissue, which could lead to underdosing of the target area.[1] If conformance is poor, alternative strategies may need to be considered.[3]

Q5: What is the typical timeline from catheter placement to radiation treatment?

A5: Following surgical resection and GliaSite implantation, there is typically a recovery period of one to three weeks.[7][8][11] After this period, the patient is readmitted, and the balloon is filled with the liquid radiation source (**lotrex**) for a duration of 3 to 7 days.[12]

## Quantitative Data Summary

The following tables summarize key quantitative data from clinical studies of the GliaSite Radiation Therapy System.

Table 1: Reported Adverse Events in GliaSite Clinical Trials

Adverse Event	Frequency/Incidence	Study/Reference
Meningitis	3 out of 21 patients (1 bacterial, 1 chemical, 1 aseptic)	Tatter et al. (2003)[5][6]
Wound Infection	1 out of 21 patients	Tatter et al. (2003)[5][6]
Pseudomeningocele	1 out of 21 patients	Tatter et al. (2003)[5][6]
Symptomatic Radiation Necrosis	3 out of 15 patients (20%)	Gobitti et al. (2011)[9]
Hemorrhage	Cases reported, need for careful coagulation control noted	Gerber et al. (2007)[8]
Device Removal (early)	3 out of 8 patients (due to bleeding, mass effect, lack of conformance)	Matheus & Castillo (2004)[1]

Table 2: Clinical Outcomes from Select GliaSite Studies

Outcome	Value	Patient Population	Study/Reference
Median Survival (after GliaSite)	12.7 months	Recurrent high-grade astrocytomas	Tatter et al. (2003)[5][6]
Median Survival (after GliaSite)	13 months	Recurrent high-grade glioma	Gobitti et al. (2011)[9]
1-Year Overall Survival Rate	Approx. 50%	Recurrent high-grade gliomas	Tatter et al. (2003)[7]
1-Year Overall Survival Rate	31.1%	Recurrent malignant gliomas	Gabayan et al. (2006)[7][8]

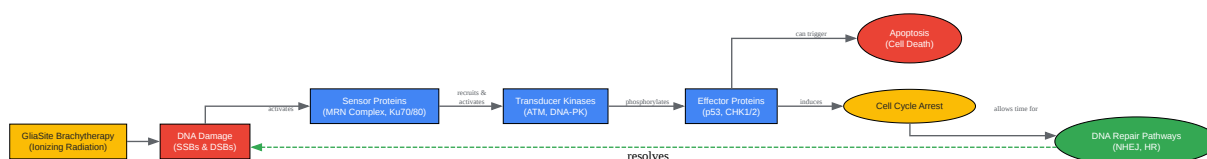
## Experimental Protocols & Visualizations

## Experimental Protocol: Post-Placement Imaging Assessment

- Objective: To verify the correct placement and conformance of the GliaSite balloon catheter within the resection cavity.
- Time Point: Within 48 hours of surgical placement.
- Imaging Modality:
  - Primary: MRI of the brain without and with gadolinium contrast. Recommended sequences include T1-weighted, T2-weighted, and FLAIR.[1][13]
  - Alternative: CT of the head without and with intravenous contrast. Note that CT may have artifacts that obscure the tissues immediately surrounding the balloon.[4][14]
- Procedure:
  1. The balloon is inflated with a diluted iodinated contrast agent for visualization.[1]
  2. The patient is positioned in the scanner, ensuring the head is stable.
  3. Acquire axial, sagittal, and coronal images of the brain.
- Analysis:
  1. Balloon Position: Confirm the balloon is centered within the resection cavity.
  2. Conformance: Measure the distance between the balloon surface and the surrounding brain parenchyma. A distance greater than 1.0 cm is considered a lack of conformance.[1]
  3. Complications: Assess for any signs of hemorrhage, edema, or mass effect.[1][13]
  4. Documentation: Record all findings and measurements. If placement is suboptimal, consult the troubleshooting guide and the neurosurgical team.

## Signaling Pathway: DNA Damage Response to Brachytherapy

The ionizing radiation delivered by the GliaSite system induces various forms of DNA damage in surrounding tumor cells, with DNA double-strand breaks (DSBs) being the most lethal.[15] [16] This triggers a complex signaling network known as the DNA Damage Response (DDR), which attempts to repair the damage. The efficacy of the brachytherapy is dependent on overwhelming this repair capacity.



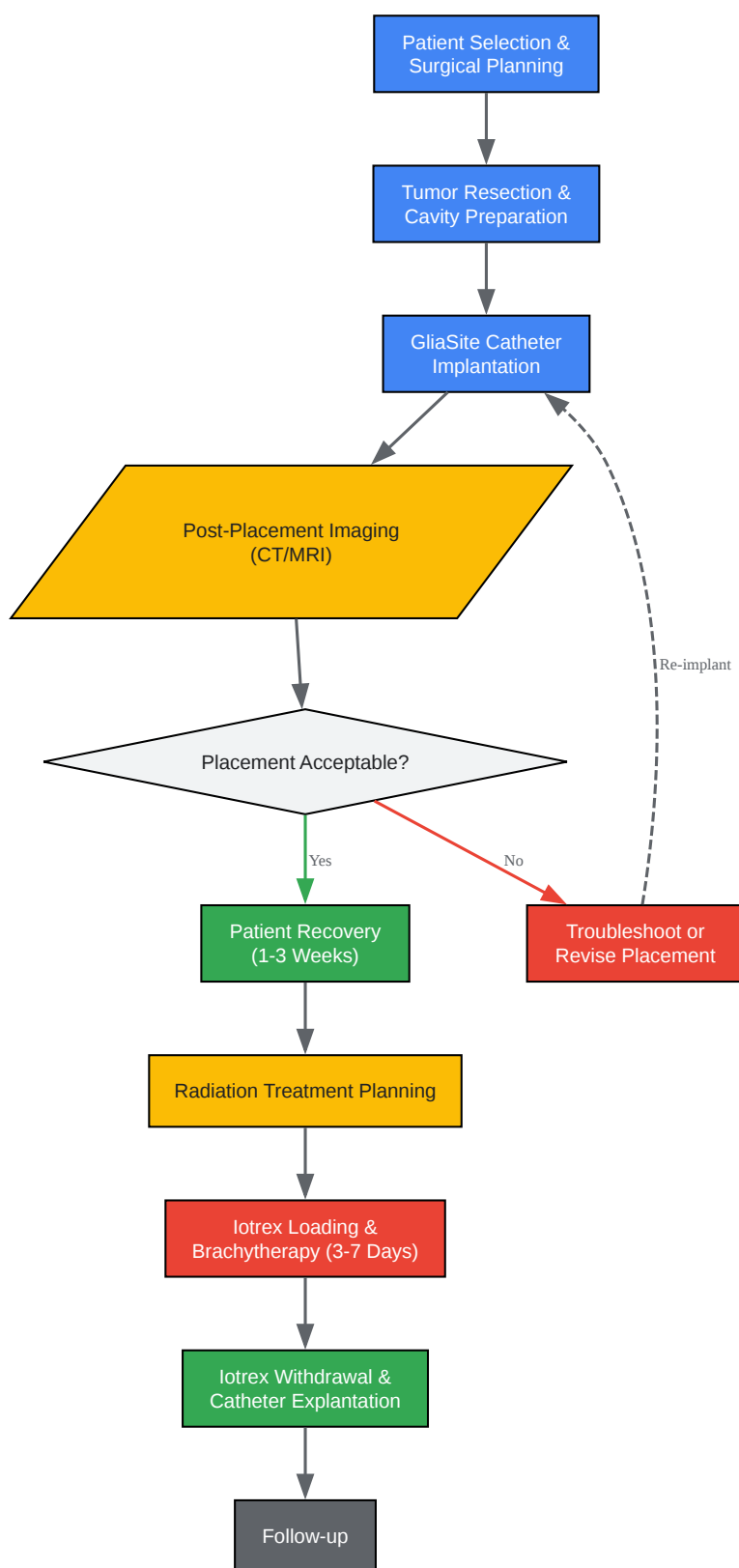
[Click to download full resolution via product page](#)

Caption: DNA Damage Response (DDR) pathway activated by GliaSite brachytherapy.

## Experimental Workflow: GliaSite Catheter Placement and Treatment

This diagram outlines the typical workflow from patient selection to the completion of brachytherapy.





[Click to download full resolution via product page](#)

Caption: Standard workflow for GliSite catheter placement and brachytherapy.

**Need Custom Synthesis?**

BenchChem offers custom synthesis for rare earth carbides and specific isotopic labeling.

Email: [info@benchchem.com](mailto:info@benchchem.com) or [Request Quote Online](#).

## References

- 1. CT and MR Imaging after Placement of the GliSite Radiation Therapy System to Treat Brain Tumor: Initial Experience - PMC [pmc.ncbi.nlm.nih.gov]
- 2. Radiation Safety Considerations In GliSite 125I Brain Implant Procedures - PubMed [pubmed.ncbi.nlm.nih.gov]
- 3. aapm.org [aapm.org]
- 4. CT and MR imaging after placement of the GliSite radiation therapy system to treat brain tumor: initial experience - PubMed [pubmed.ncbi.nlm.nih.gov]
- 5. An inflatable balloon catheter and liquid 125I radiation source (GliSite Radiation Therapy System) for treatment of recurrent malignant glioma: multicenter safety and feasibility trial - PubMed [pubmed.ncbi.nlm.nih.gov]
- 6. pure.johnshopkins.edu [pure.johnshopkins.edu]
- 7. Intracavitary Balloon Catheter Brain Brachytherapy for Malignant Gliomas or Metastasis to the Brain [southcarolinablues.com]
- 8. blueshieldca.com [blueshieldca.com]
- 9. Treatment of recurrent high-grade gliomas with GliSite brachytherapy: a prospective mono-institutional Italian experience - PubMed [pubmed.ncbi.nlm.nih.gov]
- 10. researchgate.net [researchgate.net]
- 11. Brachytherapy, Intracavitary Balloon Catheter for Brain Cancer | Providers | Blue Cross NC [bluecrossnc.com]
- 12. cda-amc.ca [cda-amc.ca]
- 13. researchgate.net [researchgate.net]
- 14. ajnr.org [ajnr.org]
- 15. Repurposing DNA repair factors to eradicate tumor cells upon radiotherapy - PMC [pmc.ncbi.nlm.nih.gov]

- 16. *Frontiers* | Altering DNA Repair to Improve Radiation Therapy: Specific and Multiple Pathway Targeting [frontiersin.org]
- To cite this document: BenchChem. [GliaSite Catheter Placement: A Technical Support Guide]. BenchChem, [2025]. [Online PDF]. Available at: [https://www.benchchem.com/product/b1264771#overcoming-challenges-in-gliasite-catheter-placement]

---

#### Disclaimer & Data Validity:

The information provided in this document is for Research Use Only (RUO) and is strictly not intended for diagnostic or therapeutic procedures. While BenchChem strives to provide accurate protocols, we make no warranties, express or implied, regarding the fitness of this product for every specific experimental setup.

**Technical Support:** The protocols provided are for reference purposes. Unsure if this reagent suits your experiment? [[Contact our Ph.D. Support Team for a compatibility check](#)]

**Need Industrial/Bulk Grade?** [Request Custom Synthesis Quote](#)

## BenchChem

Our mission is to be the trusted global source of essential and advanced chemicals, empowering scientists and researchers to drive progress in science and industry.

#### Contact

Address: 3281 E Guasti Rd  
Ontario, CA 91761, United States  
Phone: (601) 213-4426  
Email: [info@benchchem.com](mailto:info@benchchem.com)