

Addressing background noise in Iodohippurate sodium I 123 imaging

Author: BenchChem Technical Support Team. **Date:** December 2025

Compound of Interest

Compound Name: Iodohippurate sodium I 123

Cat. No.: B1260339

[Get Quote](#)

Technical Support Center: Iodohippurate Sodium I-123 Imaging

This technical support center provides troubleshooting guides and frequently asked questions (FAQs) to assist researchers, scientists, and drug development professionals in addressing background noise and other common issues encountered during Iodohippurate sodium I-123 (I-123 OIH) imaging experiments.

Troubleshooting Guides

This section offers solutions to specific problems you might encounter during your I-123 OIH imaging studies.

Issue 1: High Background Noise Throughout the Dynamic Acquisition

Q: Why is there persistently high background activity in my I-123 OIH images, leading to a poor kidney-to-background ratio?

A: Persistently high background noise can be attributed to several factors, ranging from patient physiology to technical errors in the experimental protocol. Here are the most common causes and troubleshooting steps:

- Patient-Related Factors:

- Impaired Renal Function: The most common cause of high background is poor renal function. I-123 OIH is cleared by the kidneys, and if renal function is compromised, the radiotracer remains in the bloodstream for a longer period, resulting in a high blood pool background.
 - Action: Review the subject's clinical history for any indications of renal impairment. If possible, correlate the imaging findings with renal function tests (e.g., serum creatinine, eGFR). In cases of known severe renal impairment, hepatobiliary excretion of I-123 OIH may increase, contributing to background activity.
- Dehydration: Inadequate hydration can lead to reduced renal blood flow and tracer delivery to the kidneys, as well as slower clearance of the tracer from the collecting system, which can contribute to overall background.
 - Action: Ensure subjects are well-hydrated before the study, unless contraindicated. A typical recommendation is for the patient to drink approximately 7 mL/kg of body weight.
- Radiopharmaceutical-Related Factors:
 - Radiochemical Impurities: The presence of free I-123 or other radiolabeled impurities can lead to increased background activity as these impurities may not be efficiently cleared by the kidneys and may accumulate in other tissues.
 - Action: Verify the radiochemical purity of the I-123 OIH preparation. It should be $\geq 96\%$. If purity is a concern, perform quality control checks on the radiopharmaceutical batch.
- Technical & Procedural Factors:
 - Infiltration of Injected Dose: If a portion of the I-123 OIH dose was administered interstitially instead of intravenously, it will lead to slow and prolonged absorption from the injection site, causing persistently high background activity.
 - Action: At the end of the dynamic study, acquire a static image of the injection site to check for any residual activity that would indicate infiltration.
 - Incorrect Background Subtraction: The method used to subtract background counts is a critical step and a common source of error.

- Action: Review your background correction method. The placement of the background Region of Interest (ROI) is crucial. A perirenal (around the kidney) or a C-shaped ROI is often recommended over an inferior (subrenal) ROI to avoid underestimation of background, especially in the case of the right kidney which is adjacent to the liver.

Issue 2: The Renogram Curve Shows an Atypical Pattern

Q: My renogram curve does not show the expected uptake and excretion phases. What could be the cause?

A: An atypical renogram curve can indicate physiological issues or technical problems.

- Delayed Time to Peak Activity (Tmax):
 - Possible Cause: This can be a sign of renal artery stenosis, urinary tract obstruction, or parenchymal renal disease. In cases of obstruction, the tracer accumulates in the renal pelvis and is not efficiently excreted.
 - Action: Correlate the renogram findings with the visual appearance of the dynamic images. Look for evidence of tracer retention in the renal pelvis or ureter. A diuretic challenge (e.g., with furosemide) can help differentiate between obstructive and non-obstructive hydronephrosis.
- "Flat" Renogram (Poor Uptake):
 - Possible Cause: Severely impaired renal function or renal artery occlusion can result in very low uptake of the tracer by the kidney.
 - Action: Verify the injected dose and check for infiltration. Review the subject's clinical data for severe renal disease.
- Patient Movement:
 - Possible Cause: Patient motion during the acquisition can cause the kidney to move in and out of the ROI, leading to an artificially distorted renogram curve.

- Action: Use motion correction software if available. If not, visually inspect the dynamic images for patient movement. In some cases, it may be necessary to manually re-register the ROIs on a frame-by-frame basis, though this is labor-intensive.

Frequently Asked Questions (FAQs)

Q1: What is the optimal method for background subtraction in I-123 OIH imaging?

A1: There is no single "best" method for all situations, but some are generally more robust than others. Perirenal or C-shaped background ROIs are often preferred as they provide a more accurate estimation of the background activity immediately surrounding the kidney. Inferiorly placed ROIs can underestimate the background, particularly for the right kidney due to the influence of liver activity. Automated background subtraction methods can improve reproducibility. The choice of background subtraction method can significantly impact the calculated differential renal function, so consistency is key, especially in follow-up studies.

Q2: How does radiochemical purity of Iodohippurate sodium I-123 affect the imaging results?

A2: The radiochemical purity of I-123 OIH is critical for obtaining high-quality images. The presence of free radioiodine or other impurities can lead to increased background signal, as these impurities are not specifically taken up and excreted by the renal tubules. This can result in a lower kidney-to-background ratio and may interfere with the accurate quantification of renal function. It is recommended to use I-123 OIH with a radiochemical purity of at least 96%.

Q3: What are the key patient preparation steps to minimize background noise?

A3: Proper patient preparation is essential for reducing background noise and ensuring accurate results. Key steps include:

- Hydration: Ensure the patient is well-hydrated to promote good renal blood flow and rapid clearance of the tracer.
- Voiding: Have the patient void immediately before the start of the imaging procedure to minimize activity in the bladder which can interfere with the visualization of the lower poles of the kidneys.

- **Medication Review:** Certain medications can interfere with renal function and tracer kinetics. For example, ACE inhibitors can alter renal hemodynamics. A thorough review of the patient's current medications is necessary.

Q4: Can I use a different collimator for I-123 OIH imaging?

A4: While a low-energy all-purpose (LEAP) or low-energy high-resolution (LEHR) collimator can be used, a medium-energy collimator may be preferable for I-123 imaging, especially when accurate quantification is important. This is because I-123 has some high-energy photon emissions that can penetrate the septa of low-energy collimators, leading to image degradation and increased background noise.

Quantitative Data Summary

The following table summarizes the impact of different background subtraction methods on the accuracy of activity quantification, based on phantom studies.

Background Subtraction Method	Description	Percentage Difference from Actual Activity (Range)	Reference
No Correction	Counts from the organ ROI are used without any background subtraction.	+2% to +413%	
Conventional Subtraction	A background ROI is drawn, and the average counts per pixel in the background ROI are subtracted from the organ ROI.	-1% to -80%	
Kojima Method	Background is corrected for organ thickness and depth.	+11% to -18%	
Buijs Method	Background is corrected for organ and total-body thickness.	-4% to +39%	

Experimental Protocols

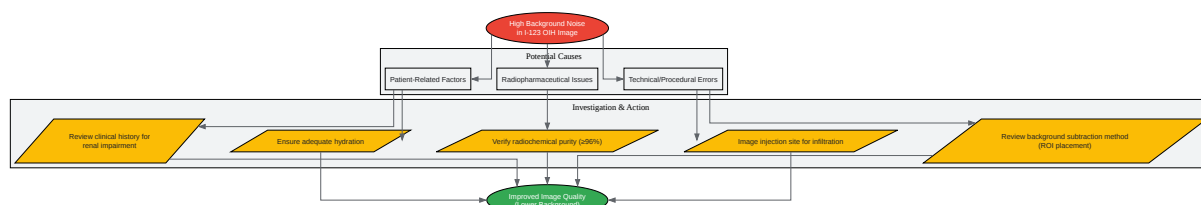
Detailed Methodology for a Standard I-123 OIH Renography Study

- Patient Preparation:
 - Ensure the patient is well-hydrated. Oral hydration with approximately 7 mL/kg of body weight is recommended.
 - Ask the patient to void immediately before the acquisition.
 - Position the patient supine with the gamma camera detector placed posteriorly.

- Radiopharmaceutical Administration:
 - Administer a sterile, pyrogen-free solution of Iodohippurate sodium I-123 intravenously as a bolus injection.
 - The administered activity can vary, but doses around 37 MBq (1.0 mCi) to 74 MBq (2.0 mCi) have been shown to provide good image quality.
- Image Acquisition:
 - Collimator: A medium-energy collimator is preferred for I-123 imaging to reduce septal penetration. A LEAP or LEHR collimator can be used as an alternative.
 - Energy Window: Set a 20% energy window centered at the 159 keV photopeak of I-123.
 - Dynamic Acquisition: Start the dynamic acquisition immediately upon injection. Acquire serial images for 20-30 minutes. A typical framing rate is 20-30 seconds per frame.
 - Static Imaging: After the dynamic acquisition, obtain a post-void static image of the kidneys and bladder. Also, acquire a static image of the injection site to rule out infiltration.
- Data Analysis:
 - Region of Interest (ROI) Drawing:
 - Draw ROIs around each kidney on a summed image of the early frames (e.g., 1-3 minutes).
 - Draw a background ROI. A perirenal or C-shaped ROI is recommended.
 - Background Subtraction: Subtract the background counts from the kidney ROIs to generate background-corrected time-activity curves (renograms).
 - Renogram Analysis: From the renogram, calculate key quantitative parameters such as:
 - Differential renal function (relative uptake).
 - Time to peak activity (Tmax).

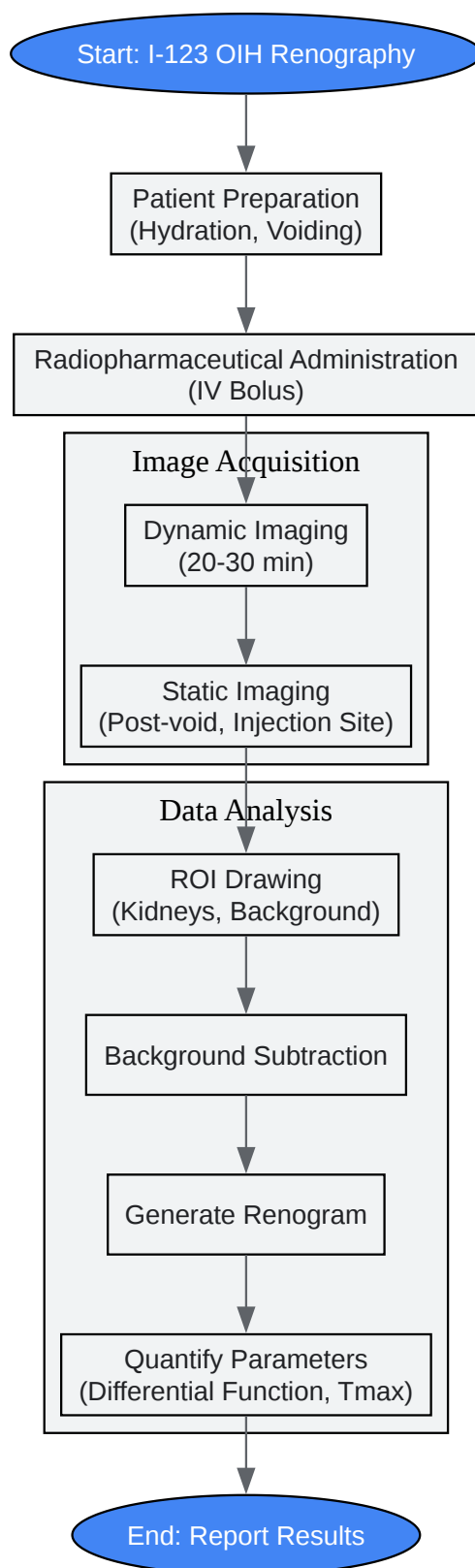
- Time to half-peak activity (T1/2) if a diuretic was administered.

Visualizations



[Click to download full resolution via product page](#)

Caption: Troubleshooting workflow for high background noise in I-123 OIH imaging.



[Click to download full resolution via product page](#)

Caption: Standard experimental workflow for I-123 OIH renography.

- To cite this document: BenchChem. [Addressing background noise in Iodohippurate sodium I 123 imaging]. BenchChem, [2025]. [Online PDF]. Available at: [https://www.benchchem.com/product/b1260339#addressing-background-noise-in-iodohippurate-sodium-i-123-imaging]

Disclaimer & Data Validity:

The information provided in this document is for Research Use Only (RUO) and is strictly not intended for diagnostic or therapeutic procedures. While BenchChem strives to provide accurate protocols, we make no warranties, express or implied, regarding the fitness of this product for every specific experimental setup.

Technical Support: The protocols provided are for reference purposes. Unsure if this reagent suits your experiment? [[Contact our Ph.D. Support Team for a compatibility check](#)]

Need Industrial/Bulk Grade? [Request Custom Synthesis Quote](#)

BenchChem

Our mission is to be the trusted global source of essential and advanced chemicals, empowering scientists and researchers to drive progress in science and industry.

Contact

Address: 3281 E Guasti Rd
Ontario, CA 91761, United States
Phone: (601) 213-4426
Email: info@benchchem.com