

# Unraveling Bone Lesions: A Comparative Guide to <sup>99m</sup>Tc-MDP Uptake and Histological Findings

**Author:** BenchChem Technical Support Team. **Date:** December 2025

## Compound of Interest

Compound Name: *<sup>99m</sup>Tc-Methylene diphosphonate*

Cat. No.: *B1257127*

[Get Quote](#)

For Researchers, Scientists, and Drug Development Professionals: An in-depth analysis of Technetium-99m Methylene Diphosphonate (<sup>99m</sup>Tc-MDP) bone scintigraphy, correlating tracer uptake with the underlying histopathology of bone lesions. This guide provides a critical comparison with alternative imaging modalities, supported by experimental data and detailed protocols to aid in research and development.

Technetium-99m methylene diphosphonate (<sup>99m</sup>Tc-MDP) bone scintigraphy has long been a cornerstone in the detection and evaluation of various osseous pathologies. Its high sensitivity in identifying areas of altered bone metabolism makes it an invaluable tool for screening skeletal metastases, diagnosing occult fractures, and assessing inflammatory conditions like osteomyelitis. The uptake of <sup>99m</sup>Tc-MDP is intrinsically linked to local blood flow and, more significantly, to the rate of new bone formation. The radiotracer's diphosphonate component chemisorbs onto hydroxyapatite crystals, particularly at sites of active osteoblastic activity. This biological mechanism forms the basis for its utility in nuclear medicine.

This guide delves into the quantitative correlation between the intensity of <sup>99m</sup>Tc-MDP uptake, often measured as the Maximum Standardized Uptake Value (SUVmax) in SPECT/CT, and the definitive histological characteristics of bone lesions. By juxtaposing imaging data with tissue-level pathology, we aim to provide a clearer understanding of the strengths and limitations of this imaging modality for researchers and clinicians.

# Quantitative Correlation of 99mTc-MDP Uptake with Histology

The ability to differentiate between benign and malignant bone lesions is a critical diagnostic challenge. Quantitative analysis of 99mTc-MDP uptake using SPECT/CT has shown promise in improving diagnostic accuracy over qualitative visual assessment.

Table 1: 99mTc-MDP Uptake in Malignant vs. Benign Bone Lesions

Lesion Type	Primary Cancer	Quantitative Metric	Cutoff Value	Sensitivity	Specificity	Accuracy	Positive Predictive Value (PPV)	Negative Predictive Value (NPV)	Source
Bone Metastases	Breast Cancer	SUVmax	> 16.7 g/mL	92.48 %	94.55 %	94%	99%	82%	[1]
Bone Metastases	Prostate Cancer	T/NT Ratio*	> 2.94	88%	97.5%	-	-	-	[2]
Osteomyelitis	Various	A/N Ratio**	> 2.0	-	-	-	-	-	[3][4]
Fibrous Dysplasia	-	Perfusion Ratio** *	1.65 ± 0.907	-	-	-	-	-	[5]
Fibrous Dysplasia	-	Uptake Ratio** **	6.0 ± 2.58	-	-	-	-	-	[5]

\*T/NT Ratio: Tumor to Normal Tissue Ratio \*\*A/N Ratio: Abnormal to Normal Tissue Ratio

\*\*\*Perfusion Ratio compared to the normal contralateral side. \*\*\*\*Uptake Ratio compared to the normal contralateral side.

## Comparison with Alternative Imaging Modalities

While <sup>99m</sup>Tc-MDP scintigraphy is highly sensitive, its specificity can be limited as various benign conditions can also lead to increased uptake. The following table compares its performance with an alternative radiotracer, <sup>99m</sup>Tc-PSMA, in the context of prostate cancer bone metastases.

Table 2: Comparison of <sup>99m</sup>Tc-MDP and <sup>99m</sup>Tc-PSMA for Prostate Cancer Bone Metastasis Detection

Imaging Agent	Sensitivity	Specificity	Additional Findings	Source
<sup>99m</sup> Tc-MDP SPECT/CT	50.0%	82.1%	-	[6]
<sup>99m</sup> Tc-PSMA SPECT/CT	83.3%	100%	Detected lymph node metastases and residual prostate disease.	[6][7]

## Experimental Protocols

A standardized protocol is crucial for reproducible and comparable quantitative imaging results. Below are summarized methodologies from key studies.

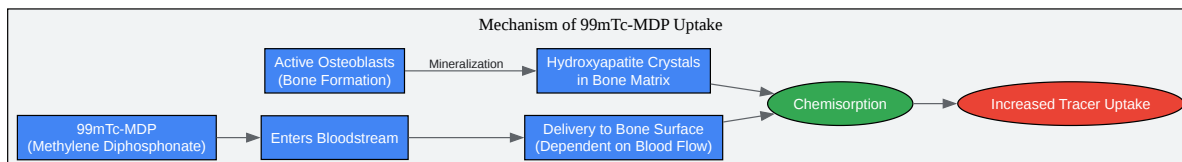
### Protocol for Quantitative <sup>99m</sup>Tc-MDP SPECT/CT for Bone Lesion Evaluation

- **Patient Preparation:** Patients are typically instructed to hydrate well before and after the injection of the radiotracer to ensure good quality images and to facilitate the clearance of the tracer from soft tissues. No other specific preparation is usually required.

- **Radiopharmaceutical Administration:** An intravenous injection of 740–925 MBq (20–25 mCi) of <sup>99m</sup>Tc-MDP is administered to the patient. The exact dose and time of injection are meticulously recorded for subsequent SUV calculations.
- **Imaging Acquisition:**
  - Whole-body planar scans are acquired 2 to 4 hours post-injection.
  - SPECT/CT imaging is performed over the area of interest identified on the planar scans.
  - **SPECT Parameters:** A typical protocol might involve a dual-head gamma camera with low-energy, high-resolution collimators. Data is acquired over 360 degrees, with 60-120 projections, in a 128x128 or 256x256 matrix.
  - **CT Parameters:** A low-dose CT scan is performed for attenuation correction and anatomical localization. Typical parameters are 120 kVp and 30-80 mAs.
- **Image Reconstruction and Analysis:**
  - SPECT data is reconstructed using an iterative algorithm (e.g., OSEM) with corrections for attenuation, scatter, and collimator-detector response.
  - The SPECT and CT images are fused, and volumes of interest (VOIs) are drawn around the lesions and in a reference normal bone region.
  - Quantitative metrics such as SUV<sub>max</sub>, SUV<sub>mean</sub>, T/NT ratio, or A/N ratio are calculated.
- **Histological Confirmation:** The final diagnosis is confirmed by bone biopsy of the suspicious lesion. The histological findings are then correlated with the quantitative imaging data.

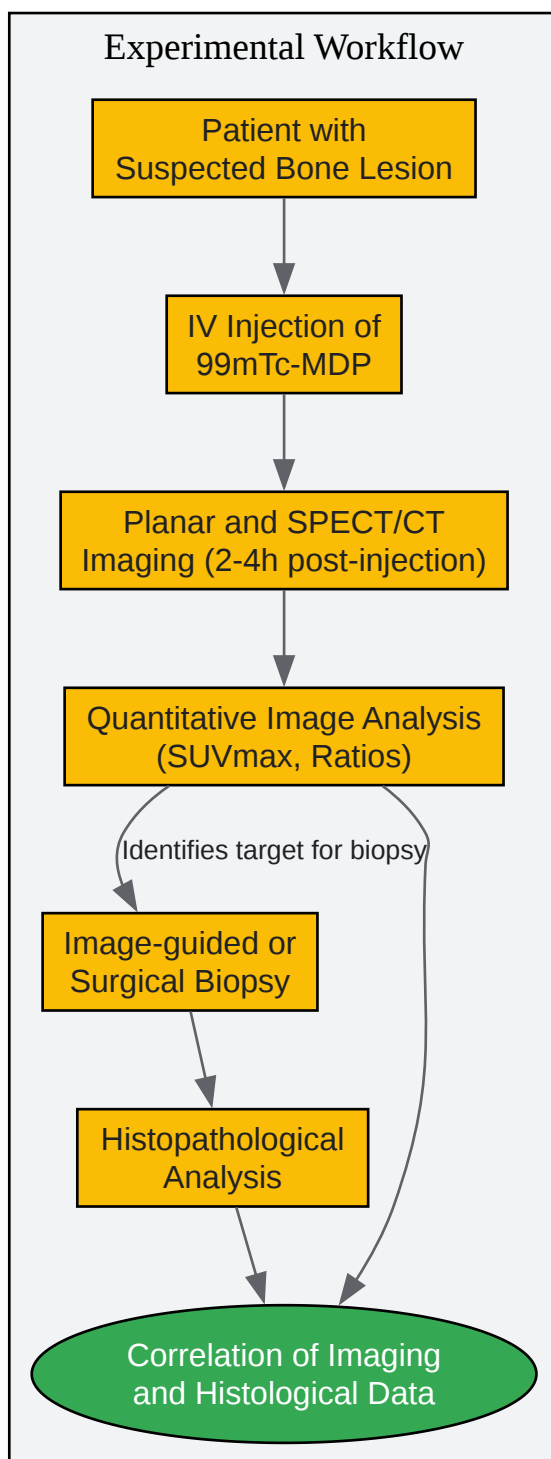
## Visualizing the Pathways and Processes

To better understand the underlying mechanisms and workflows, the following diagrams are provided.



[Click to download full resolution via product page](#)

Mechanism of <sup>99m</sup>Tc-MDP uptake in bone.



[Click to download full resolution via product page](#)

Experimental workflow for correlating imaging and histology.

## Concluding Remarks for the Research Professional

The quantitative analysis of  $^{99m}\text{Tc}$ -MDP uptake, particularly through SPECT/CT, offers a valuable, non-invasive method to aid in the characterization of bone lesions. The data presented demonstrates a clear differentiation between malignant and benign conditions based on uptake values, which can be instrumental in guiding clinical decisions and patient management. However, it is crucial to acknowledge that significant overlap can exist, and a definitive diagnosis often relies on histopathological examination.

For drug development professionals, understanding the correlation between  $^{99m}\text{Tc}$ -MDP uptake and the underlying cellular activity provides a framework for utilizing bone scintigraphy as a biomarker for treatment response. A decrease in tracer uptake following therapy, for instance, could be quantitatively correlated with a reduction in osteoblastic activity and tumor viability.

Future research should focus on establishing more refined correlations between quantitative  $^{99m}\text{Tc}$ -MDP uptake and specific histological parameters, such as tumor grade, cellularity, and the degree of inflammatory infiltrate. Such studies will further enhance the diagnostic and prognostic power of this widely available and cost-effective imaging modality.

#### *Need Custom Synthesis?*

*BenchChem offers custom synthesis for rare earth carbides and specific isotopic labeling.*

*Email: [info@benchchem.com](mailto:info@benchchem.com) or [Request Quote Online](#).*

## References

- 1. Frontiers | A novel approach for fibrous dysplasia assessment using combined planar and quantitative SPECT/CT analysis of Tc- $^{99m}$ -diphosphonate bone scan in correlation with biological bone turnover markers of disease activity [frontiersin.org]
- 2. Peritoneal Metastasis of Osteosarcoma in  $^{99m}\text{Tc}$ -MDP SPECT/CT Imaging - PubMed [pubmed.ncbi.nlm.nih.gov]
- 3. The value of quantitative uptake of ( $^{99m}$ )Tc-MDP and ( $^{99m}$ )Tc-HMPAO white blood cells in detecting osteomyelitis in violated peripheral bones - PubMed [pubmed.ncbi.nlm.nih.gov]
- 4. [Evaluation of inflammatory activity in chronic osteomyelitis. Contribution of scintigraphy with polyclonal antibodies] - PubMed [pubmed.ncbi.nlm.nih.gov]

- 5. Criteria and quantification of fibrous dysplasia on MDP scanning - PubMed [pubmed.ncbi.nlm.nih.gov]
- 6. Frontiers | Comparison of diagnostic efficacy between 99mTc-methylene diphosphate SPECT/CT and MRI for bone and joint infections: a multicenter retrospective analysis [frontiersin.org]
- 7. purerims.smu.ac.za [purerims.smu.ac.za]
- To cite this document: BenchChem. [Unraveling Bone Lesions: A Comparative Guide to 99mTc-MDP Uptake and Histological Findings]. BenchChem, [2025]. [Online PDF]. Available at: [https://www.benchchem.com/product/b1257127#correlating-99mtc-mdp-uptake-with-histological-findings-in-bone-lesions]

---

### Disclaimer & Data Validity:

The information provided in this document is for Research Use Only (RUO) and is strictly not intended for diagnostic or therapeutic procedures. While BenchChem strives to provide accurate protocols, we make no warranties, express or implied, regarding the fitness of this product for every specific experimental setup.

**Technical Support:** The protocols provided are for reference purposes. Unsure if this reagent suits your experiment? [[Contact our Ph.D. Support Team for a compatibility check](#)]

**Need Industrial/Bulk Grade?** [Request Custom Synthesis Quote](#)

## BenchChem

Our mission is to be the trusted global source of essential and advanced chemicals, empowering scientists and researchers to drive progress in science and industry.

### Contact

Address: 3281 E Guasti Rd  
Ontario, CA 91761, United States  
Phone: (601) 213-4426  
Email: [info@benchchem.com](mailto:info@benchchem.com)