

A Comparative Analysis of 99mTc-MDP and MRI in the Diagnosis of Osteomyelitis

Author: BenchChem Technical Support Team. **Date:** December 2025

Compound of Interest

Compound Name: 99mTc-Methylene diphosphonate

Cat. No.: B1257127

[Get Quote](#)

For researchers, scientists, and drug development professionals, the accurate and timely diagnosis of osteomyelitis is critical for effective therapeutic intervention. This guide provides a comparative analysis of two key imaging modalities: Technetium-99m methylene diphosphonate (99mTc-MDP) bone scintigraphy and Magnetic Resonance Imaging (MRI), with a focus on their diagnostic performance, experimental protocols, and roles in the clinical workflow.

Osteomyelitis, an infection of the bone, can be challenging to diagnose. While plain radiography is often the initial imaging step, its sensitivity is low in the early stages of the disease.^[1] Therefore, more advanced imaging techniques like 99mTc-MDP bone scintigraphy and MRI are crucial for an early and accurate diagnosis.^[2]

Quantitative Performance Data

The diagnostic performance of 99mTc-MDP and MRI in osteomyelitis has been extensively studied. The following table summarizes the quantitative data from various sources, highlighting the sensitivity, specificity, and accuracy of each modality. It is important to note that the performance of 99mTc-MDP can be enhanced with Single Photon Emission Computed Tomography (SPECT)/CT.

Imaging Modality	Sensitivity	Specificity	Accuracy	Positive Predictive Value (PPV)	Negative Predictive Value (NPV)	Source
99mTc-MDP Bone Scan	75%	52.9%	57.1%	27.3%	90%	[3]
99mTc-MDP SPECT/CT	96%	92%	96%	-	-	[4]
MRI	82-100%	75-96%	87%	-	-	[3]
MRI	88%	84%	87%	-	-	[4]

Experimental Protocols

99mTc-MDP Three-Phase Bone Scintigraphy

The 99mTc-MDP three-phase bone scan is a cornerstone of nuclear medicine for detecting osteomyelitis. The protocol involves the intravenous injection of the radiotracer 99mTc-MDP, which accumulates in areas of increased bone turnover and blood flow. The scan consists of three distinct phases:

- Flow (Angiographic) Phase: Dynamic images are acquired for the first 60 seconds immediately following the injection to assess blood flow to the region of interest.
- Blood Pool Phase: Static images are taken within 10 minutes after injection to evaluate soft tissue hyperemia.
- Delayed (Bone) Phase: Planar or SPECT/CT images are acquired 2 to 4 hours post-injection, allowing for the tracer to accumulate in the bone matrix. Increased focal uptake in all three phases is highly suggestive of osteomyelitis.[\[3\]](#)

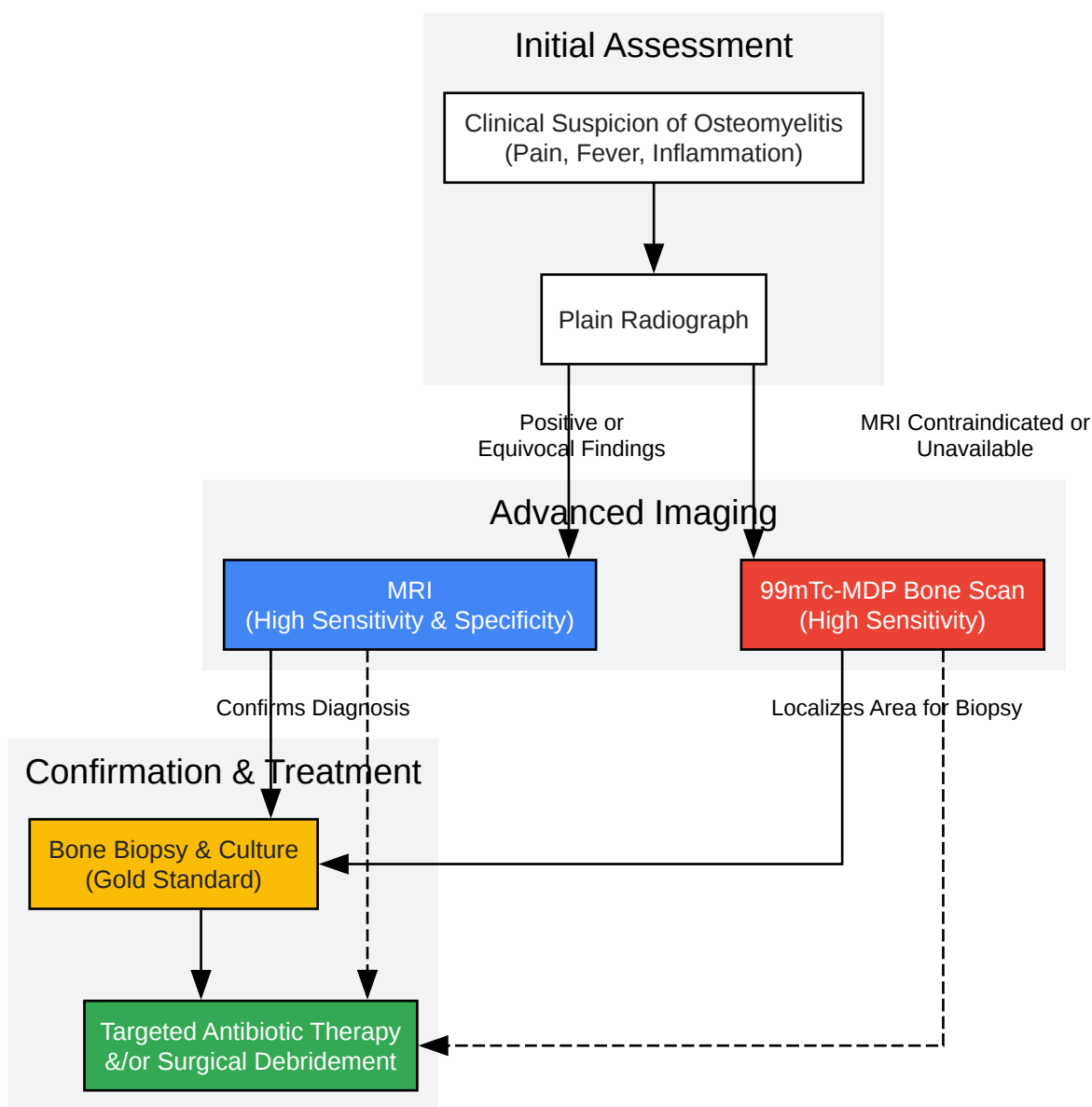
Magnetic Resonance Imaging (MRI) Protocol for Osteomyelitis

MRI is considered the imaging modality of choice for suspected osteomyelitis by many clinicians due to its excellent soft tissue contrast and high sensitivity for detecting early bone marrow changes.^[1] A typical MRI protocol for suspected osteomyelitis includes:

- T1-weighted sequences: Provide detailed anatomical information. Infected marrow typically shows decreased signal intensity.
- T2-weighted sequences (with fat suppression) or Short-Tau Inversion Recovery (STIR): These sequences are highly sensitive to the presence of edema and fluid, which appear as high signal intensity in infected bone and surrounding soft tissues.
- Post-contrast T1-weighted sequences (with fat suppression): Following the intravenous administration of a gadolinium-based contrast agent, these images help to delineate abscesses (which will show rim enhancement) and assess the extent of inflammation.

Diagnostic Workflow

The selection of an imaging modality often depends on the clinical presentation and local expertise. The following diagram illustrates a typical diagnostic workflow for a patient with suspected osteomyelitis.



[Click to download full resolution via product page](#)

Diagnostic workflow for suspected osteomyelitis.

Comparative Insights

99mTc-MDP Bone Scintigraphy:

- Advantages: High sensitivity in detecting early bone changes, ability to perform a whole-body survey to detect multifocal disease, and relatively lower cost.

- Disadvantages: Lower specificity, as increased uptake can be seen in other conditions such as fractures, tumors, and arthritis. It also involves exposure to ionizing radiation.

Magnetic Resonance Imaging (MRI):

- Advantages: Excellent anatomical detail and superior soft tissue contrast, allowing for the detection of abscesses and the extent of infection into surrounding tissues. It has high sensitivity and specificity and does not involve ionizing radiation.[3]
- Disadvantages: Higher cost, longer acquisition time, and contraindications in patients with certain metallic implants or claustrophobia. The presence of metallic hardware can also cause artifacts that may obscure the area of interest.

Conclusion

Both ^{99m}Tc -MDP bone scintigraphy and MRI are valuable tools in the diagnostic workup of osteomyelitis. MRI is often favored for its superior anatomical detail and high diagnostic accuracy, particularly in complex cases. However, ^{99m}Tc -MDP bone scintigraphy remains a highly sensitive and cost-effective option, especially for initial screening and in patients where MRI is not feasible. The choice of imaging modality should be guided by the specific clinical scenario, available resources, and the expertise of the interpreting physician to ensure the best possible outcome for the patient.

Need Custom Synthesis?

BenchChem offers custom synthesis for rare earth carbides and specific isotopic labeling.

Email: info@benchchem.com or [Request Quote Online](#).

References

1. Osteomyelitis: Diagnosis and Treatment | AAFP [aafp.org]
2. "Imaging Osteomyelitis" by Brandon J. Smith, MD, Grant S. Buchanan, MD et al. [mds.marshall.edu]
3. Comparative Analysis of ^{99m}Tc -MDP Three-Phase Bone Scan with SPECT/CT and ^{99m}Tc -HMPAO-Labeled WBC SPECT/CT in the Differential Diagnosis of Clinically Suspicious Post-traumatic Osteomyelitis - PMC [pmc.ncbi.nlm.nih.gov]

- 4. Frontiers | Comparison of diagnostic efficacy between 99mTc-methylene diphosphate SPECT/CT and MRI for bone and joint infections: a multicenter retrospective analysis [frontiersin.org]
- To cite this document: BenchChem. [A Comparative Analysis of 99mTc-MDP and MRI in the Diagnosis of Osteomyelitis]. BenchChem, [2025]. [Online PDF]. Available at: [https://www.benchchem.com/product/b1257127#comparative-analysis-of-99mtc-mdp-and-mri-in-diagnosing-osteomyelitis]

Disclaimer & Data Validity:

The information provided in this document is for Research Use Only (RUO) and is strictly not intended for diagnostic or therapeutic procedures. While BenchChem strives to provide accurate protocols, we make no warranties, express or implied, regarding the fitness of this product for every specific experimental setup.

Technical Support: The protocols provided are for reference purposes. Unsure if this reagent suits your experiment? [[Contact our Ph.D. Support Team for a compatibility check](#)]

Need Industrial/Bulk Grade? [Request Custom Synthesis Quote](#)

BenchChem

Our mission is to be the trusted global source of essential and advanced chemicals, empowering scientists and researchers to drive progress in science and industry.

Contact

Address: 3281 E Guasti Rd
Ontario, CA 91761, United States
Phone: (601) 213-4426
Email: info@benchchem.com