

Technical Support Center: Optimizing Fixation Stability in BSSO Procedures

Author: BenchChem Technical Support Team. **Date:** April 2026

Compound of Interest

Compound Name: BSSO
CAS No.: 3712-16-1
Cat. No.: B1252915

[Get Quote](#)

This technical support center provides researchers, scientists, and drug development professionals with troubleshooting guides and frequently asked questions (FAQs) to address specific issues encountered during Bilateral Sagittal Split Osteotomy (**BSSO**) procedures and related experimental studies.

Troubleshooting Guides

This section provides solutions to common problems that may arise during or after **BSSO** procedures, potentially impacting fixation stability.

Issue: Intraoperative Fracture ("Bad Split")

An unfavorable fracture during the osteotomy, commonly known as a "bad split," can compromise the stability of the fixation.[1][2][3] These can occur in various locations, including the proximal or distal segments, the coronoid process, or the condylar neck.[2]

Symptom	Possible Cause	Recommended Action
Uncontrolled fracture line during splitting	Incomplete osteotomy cuts, especially at the inferior border. ^[1]	Ensure all osteotomy cuts are complete before attempting the split. Consider using a fine osteotome to gently guide the fracture.
Presence of impacted third molars. ^[1]	Ideally, third molars should be removed at least six months prior to the BSSO procedure to allow for adequate bone healing. ^[1]	
Fracture extending to the condylar neck	High osteotomy line or incorrect vector of splitting force.	Immediately stabilize the fractured segments. Depending on the severity, this may involve additional miniplates or screws. In severe cases, discontinuing the procedure and allowing for healing before a second attempt might be necessary. ^[4]
Buccal or lingual plate fracture	Thin cortical bone or excessive force.	The fractured fragment should be repositioned and stabilized, often with an additional miniplate or positional screws, to ensure adequate bone contact and stability. ^[5]

Issue: Postoperative Malocclusion

The development of a malocclusion after fixation can indicate instability or improper segment positioning.^{[1][6]}

Symptom	Possible Cause	Recommended Action
Immediate open bite upon release of intermaxillary fixation (IMF)	Condylar sag, where the condyle is not properly seated in the glenoid fossa.[7][8][9]	Intraoperatively, meticulously check the occlusion after fixation and before final closure. If condylar sag is suspected, the fixation should be released and the proximal segment repositioned.[7][9] Postoperatively, minor discrepancies may be managed with guiding elastics, but significant malocclusion may require surgical revision. [1]
Hardware failure (e.g., screw loosening, plate bending).	Obtain radiographic imaging to assess the integrity of the fixation hardware. If failure is confirmed, revision surgery to replace or augment the fixation is necessary.	
Gradual development of malocclusion weeks to months post-op	Skeletal relapse due to soft tissue pull or neuromuscular adaptation.	Ensure adequate and stable fixation was achieved intraoperatively. Postoperative orthodontic management is crucial to guide the occlusion and counteract minor relapse tendencies.
Condylar resorption.[1][10]	Monitor patients with risk factors (e.g., high mandibular plane angle, female gender). Management may involve occlusal adjustments, orthodontics, or in severe cases, further surgery.	

Issue: Hardware-Related Complications

Problems with the fixation plates and screws can lead to instability and other adverse outcomes.

Symptom	Possible Cause	Recommended Action
Screw loosening in the immediate postoperative period	Poor bone quality, oversized drill hole, or inadequate screw tightening.	If detected early and stability is compromised, immediate revision with a larger diameter screw or a different fixation method may be required. In a retrospective analysis, poor stability from screw loosening was observed in 0.62% of cases. [11]
Infection at the hardware site	Bacterial contamination during surgery or poor postoperative oral hygiene.	Initial management typically involves a course of antibiotics. If the infection persists or an abscess forms, surgical drainage and potentially hardware removal may be necessary. [12]
Palpable or exposed hardware	Thin soft tissue coverage or prominent hardware placement.	If the hardware is causing patient discomfort or is exposed to the oral cavity, removal is often indicated after bony union is complete (typically 6-12 months post-surgery). [13] [14]

Frequently Asked Questions (FAQs)

Q1: Which fixation method provides better stability: miniplates or bicortical screws?

A1: Both miniplate (monocortical) and bicortical screw fixation can provide adequate stability for **BSSO** procedures, and the choice often depends on surgeon preference and the specific clinical situation.[15] Meta-analyses have shown no statistically significant difference in skeletal stability between the two methods for both mandibular advancement and setback.[16]

However, some studies suggest nuances:

- Biomechanical studies have indicated that bicortical screw fixation tends to be more rigid than monocortical miniplate fixation.[17]
- Long-term relapse rates for mandibular advancement have been reported to be slightly higher in some studies for patients treated with bicortical screws compared to miniplates.[18]
- Condylar position: One study noted a marginal but statistically significant increase in the angulation of the left condyle in the lag screw group compared to the miniplate group.[15]

Q2: What is "condylar sag" and how can it be prevented?

A2: Condylar sag refers to the improper seating or inferior displacement of the mandibular condyle within the glenoid fossa after the osteotomized segments are fixated.[7][8] This can lead to immediate postoperative malocclusion and potential long-term temporomandibular joint (TMJ) issues.[7][10]

Prevention strategies include:

- Meticulous intraoperative technique: Ensuring the condyle is properly seated in the fossa before and during fixation is paramount.[7]
- Use of condylar positioning devices: While their use is debated, these devices can aid in maintaining the preoperative condylar position.[7]
- Intraoperative assessment: Carefully checking the occlusion after fixation and before final closure can help identify and correct condylar sag intraoperatively.[9]

Q3: What are the management options for an intraoperative "bad split"?

A3: The management of a "bad split" depends on the location and severity of the unfavorable fracture.[2] The primary goal is to achieve stable fixation of all fragments.

- Minor fractures of the buccal or lingual plates can often be managed by incorporating the fractured segment into the fixation with an additional miniplate or screws.[5]
- Fractures involving the condylar head or neck are more complex. The surgeon must decide whether to attempt immediate fixation or to abort the procedure on that side and plan for a delayed repair.[4]
- The use of osteosynthetic plates and miniplates with bicortical or monocortical screws is a common approach to stabilize the fractured segments.[5]

Q4: Is routine removal of fixation hardware necessary after **BSSO**?

A4: Routine removal of asymptomatic fixation hardware is generally not necessary.[13]

Titanium plates and screws are biocompatible and can remain in place indefinitely in many cases. However, hardware removal may be indicated in cases of:

- Infection or inflammation around the hardware.[12]
- Patient discomfort, such as palpability or sensitivity to cold.[19]
- Hardware exposure into the oral cavity.[14]
- Patient request.[19]

Rates of hardware removal due to complications vary, with some studies suggesting a lower rate for bicortical screws (3.1%-7.2% per site) compared to miniplates (6.6%-22.2% per site). [12]

Q5: What is the expected timeline for bone healing and return to function after **BSSO**?

A5: Bony union after a **BSSO** typically takes several months. While rigid fixation allows for a more rapid return to function compared to older methods, a period of restricted jaw function is still necessary. A typical timeline is as follows:

- Initial Healing (First 6-8 weeks): A soft diet is usually recommended to minimize forces on the healing osteotomy sites.

- Return to Normal Function: Most patients can gradually return to a normal diet and function over the course of 3 to 6 months.
- Full Bony Consolidation: Radiographic evidence of complete bone healing is typically seen by 6 to 12 months post-surgery.

Data Presentation

Table 1: Comparison of Relapse Rates for Different Fixation Methods in **BSSO** Advancement

Fixation Method	Timepoint	Relapse Rate at Point B (%)
Bicortical Screws	Short-term	1.5 - 32.7
Long-term	2.0 - 50.3	
Miniplates	Short-term	1.5 - 18.0
Long-term	1.5 - 8.9	
Bioresorbable Bicortical Screws	Short-term	10.4 - 17.4

Data compiled from a systematic review.[\[18\]](#)

Table 2: Incidence of Hardware-Related Complications

Fixation Method	Complication	Incidence Rate (%)
Bicortical Screws	Screw Loosening (Immediate Post-op)	0.62
Infection (1-month follow-up)	2.48	
Hardware Removal (Symptomatic)	3.1 - 7.2 (per site)	
Miniplates	Hardware Removal (Symptomatic)	6.6 - 22.2 (per site)

Data compiled from multiple studies.[\[11\]](#)[\[12\]](#)

Experimental Protocols

Protocol 1: In Vitro Biomechanical Testing of **BSSO** Fixation Stability

Objective: To compare the mechanical stability of different fixation techniques (e.g., miniplates vs. bicortical screws) in a controlled laboratory setting.

Methodology:

- Model Preparation: Utilize synthetic polyurethane hemimandible replicas.[\[20\]](#) Perform a standardized **BSSO** on each replica.
- Fixation: Divide the models into experimental groups based on the fixation method to be tested (e.g., single miniplate, two miniplates, inverted 'L' pattern bicortical screws).[\[20\]](#)[\[21\]](#) Apply the fixation according to the manufacturer's instructions and surgical best practices.
- Mounting: Securely mount the proximal segment of each hemimandible in a testing jig, simulating the temporomandibular joint articulation.[\[20\]](#)
- Load Application: Use a universal testing machine to apply controlled vertical and/or lateral forces to a specific point on the distal segment (e.g., the first molar).[\[20\]](#)[\[21\]](#)[\[22\]](#)

- **Data Acquisition:** Record the force applied and the resulting displacement of the distal segment. The point of failure can be defined as a specific amount of displacement (e.g., 8-10 mm) or until fracture of the hardware or bone model.[20][21]
- **Analysis:** Compare the mean failure load and stiffness (force per unit displacement) between the different fixation groups using appropriate statistical tests (e.g., ANOVA).[21]

Protocol 2: 3D Analysis of Condylar Displacement using Cone-Beam Computed Tomography (CBCT)

Objective: To quantify the three-dimensional changes in condylar position following **BSSO** with a specific fixation technique.

Methodology:

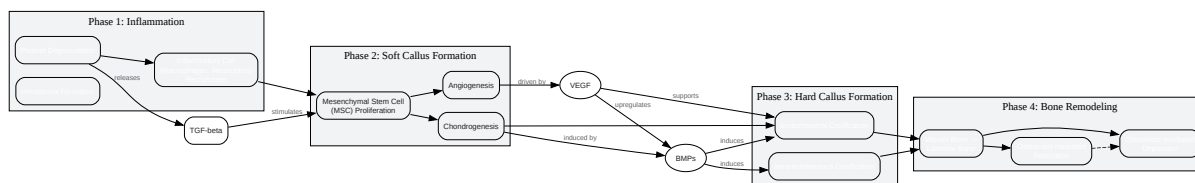
- **Image Acquisition:** Obtain high-resolution CBCT scans of the patient preoperatively and at specified postoperative intervals (e.g., 1 week and 6 months).[23][24][25] Ensure consistent patient positioning and scanning parameters.
- **3D Model Generation:** Use specialized software (e.g., SimPlant, InVesalius) to segment the CBCT data and create 3D virtual models of the preoperative and postoperative mandibles.
- **Image Registration:** Superimpose the postoperative 3D model onto the preoperative model using a stable reference area, typically the cranial base.
- **Coordinate System Definition:** Establish a standardized three-dimensional coordinate system (x, y, z axes) to measure translational and rotational changes.
- **Landmark Identification:** Identify and mark key anatomical landmarks on the condyles of both the preoperative and postoperative models.
- **Displacement Measurement:** Quantify the displacement of the condylar landmarks in the three spatial planes (anteroposterior, superoinferior, and mediolateral).[23][26] Rotational changes (pitch, roll, and yaw) can also be calculated.
- **Statistical Analysis:** Analyze the mean displacement and rotational changes to determine the extent of condylar repositioning. Correlate these changes with clinical outcomes such as

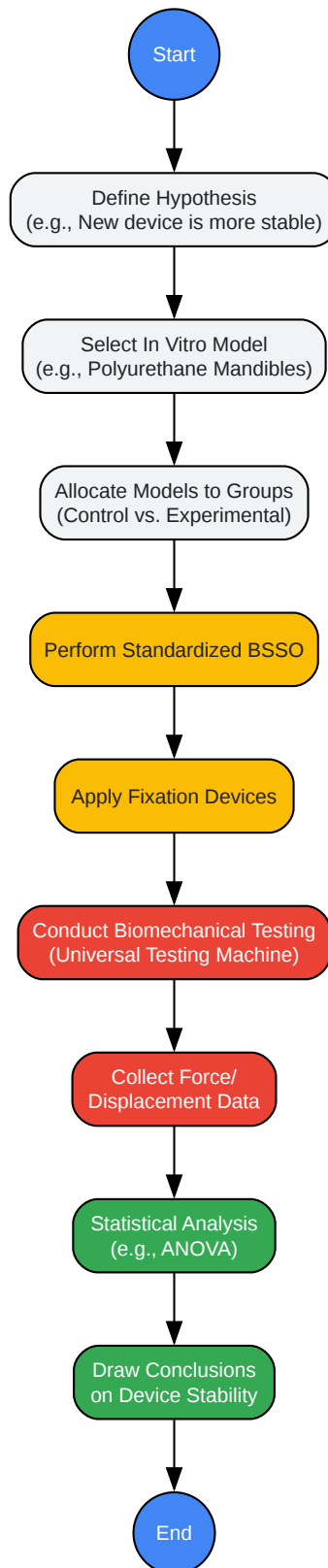
relapse or TMJ symptoms.

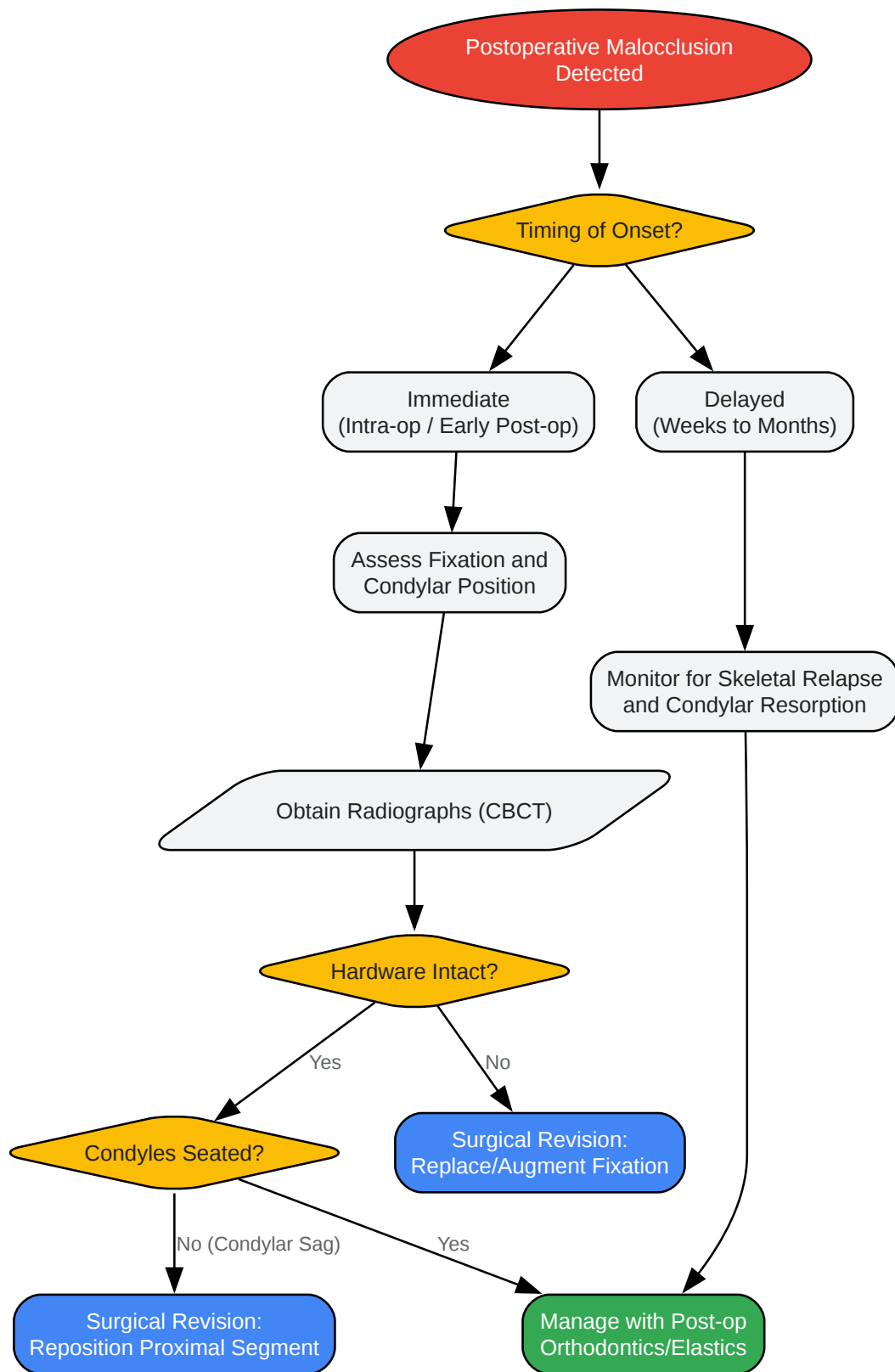
Signaling Pathways and Logical Relationships

Bone Healing Cascade in **BSSO**

The healing of an osteotomy site following a **BSSO** procedure is a complex biological process involving a cascade of molecular signaling events. This process shares similarities with natural fracture healing and involves several key growth factors, including Bone Morphogenetic Proteins (BMPs), Transforming Growth Factor-beta (TGF- β), and Vascular Endothelial Growth Factor (VEGF).[\[27\]](#)[\[28\]](#)[\[29\]](#)[\[30\]](#)[\[31\]](#)[\[32\]](#)







[Click to download full resolution via product page](#)

Need Custom Synthesis?

BenchChem offers custom synthesis for rare earth carbides and specific isotopic labeling.

Email: info@benchchem.com or [Request Quote Online](#).

References

- [1. Bilateral Sagittal Split Osteotomy - PMC \[pmc.ncbi.nlm.nih.gov\]](#)
- [2. Management of A Bad Split Complication: A Systematic Review \[opendentistryjournal.com\]](#)
- [3. Unfavorable fractures in bilateral sagittal split osteotomy: a systematic review of classification and management strategies \[termedia.pl\]](#)
- [4. Bad splits in bssso | PPTX \[slideshare.net\]](#)
- [5. researchgate.net \[researchgate.net\]](#)
- [6. Malocclusion after Orthodontics and Orthognathic Surgery: Prevention and Treatment Pitfalls | Clinical Gate \[clinicalgate.com\]](#)
- [7. ijdmsrjournal.com \[ijdmsrjournal.com\]](#)
- [8. Condylar sag | PPTX \[slideshare.net\]](#)
- [9. Intraoperative diagnosis of condylar sag after bilateral sagittal split ramus osteotomy - PubMed \[pubmed.ncbi.nlm.nih.gov\]](#)
- [10. The Anatomical Basis for Plate Fixation in BSSO to Minimize Condylar Torquing: A Comparative CT Study of Mandibular Advancement and Setback - PMC \[pmc.ncbi.nlm.nih.gov\]](#)
- [11. Complications of bicortical screw fixation observed in 482 mandibular sagittal osteotomies - PubMed \[pubmed.ncbi.nlm.nih.gov\]](#)
- [12. researchgate.net \[researchgate.net\]](#)
- [13. dereksteinbacher.com \[dereksteinbacher.com\]](#)
- [14. Hardware Removal in Maxillofacial Trauma: A Retrospective Study - PMC \[pmc.ncbi.nlm.nih.gov\]](#)
- [15. Post-BSSO condylar position stability: a comparison of miniplate and lag screw fixation - PMC \[pmc.ncbi.nlm.nih.gov\]](#)
- [16. Stability of bicortical screw versus plate fixation after mandibular setback with the bilateral sagittal split osteotomy: a systematic review and meta-analysis - PubMed](#)

[pubmed.ncbi.nlm.nih.gov]

- 17. Stability of bicortical screw versus plate fixation after mandibular setback with the bilateral sagittal split osteotomy: a systematic review and meta-analysis | Pocket Dentistry [pocketdentistry.com]
- 18. Stability after bilateral sagittal split osteotomy advancement surgery with rigid internal fixation: a systematic review [boris-portal.unibe.ch]
- 19. Frequency and Reasons for Fixation Hardware Removal After Orthognathic Surgery in Patients Treated in One Center - PMC [pmc.ncbi.nlm.nih.gov]
- 20. Biomechanical evaluation of different fixation techniques following modified sagittal split ramus osteotomy using buccal step: An in vitro study - PMC [pmc.ncbi.nlm.nih.gov]
- 21. Comparison of strengths of five internal fixation methods used after bilateral sagittal split ramus osteotomy: An in vitro study - PMC [pmc.ncbi.nlm.nih.gov]
- 22. Investigation of a Modified Novel Technique in Bilateral Sagittal Splitting Osteotomy Fixation: Finite Element Analysis and In Vitro Biomechanical Test - PMC [pmc.ncbi.nlm.nih.gov]
- 23. Cone-beam computed tomography evaluation on the condylar displacement following sagittal split ramus osteotomy in asymmetric setback patients: Comparison between conventional approach and surgery-first approach - PMC [pmc.ncbi.nlm.nih.gov]
- 24. World Journal of Dentistry [wjoud.com]
- 25. Pre- and Post-Operative Cone Beam Computed Tomography Assessment of the Temporomandibular Joint in Patients with Orthognathic Surgery - PMC [pmc.ncbi.nlm.nih.gov]
- 26. Cone-beam computed tomography evaluation on the condylar displacement following sagittal split ramus osteotomy in asymmetric setback patients: Comparison between conventional approach and surgery-first approach - PubMed [pubmed.ncbi.nlm.nih.gov]
- 27. Bone Morphogenetic Proteins in Craniofacial Surgery: Current Techniques, Clinical Experiences, and the Future of Personalized Stem Cell Therapy - PMC [pmc.ncbi.nlm.nih.gov]
- 28. Expression of BMP-2 and TGF-beta 1 mRNA during healing of the rabbit mandible - PubMed [pubmed.ncbi.nlm.nih.gov]
- 29. academic.oup.com [academic.oup.com]
- 30. mnofs.com [mnofs.com]
- 31. VEGF-activated angiogenesis during bone regeneration - PubMed [pubmed.ncbi.nlm.nih.gov]

- [32. The roles of vascular endothelial growth factor in bone repair and regeneration - PMC \[pmc.ncbi.nlm.nih.gov\]](#)
- To cite this document: BenchChem. [Technical Support Center: Optimizing Fixation Stability in BSSO Procedures]. BenchChem, [2026]. [Online PDF]. Available at: [<https://www.benchchem.com/product/b1252915/docs#technical-support-center-optimizing-fixation-stability-in-bssoprocedures>]

Disclaimer & Data Validity:

The information provided in this document is for Research Use Only (RUO) and is strictly not intended for diagnostic or therapeutic procedures. While BenchChem strives to provide accurate protocols, we make no warranties, express or implied, regarding the fitness of this product for every specific experimental setup.

Technical Support: The protocols provided are for reference purposes. Unsure if this reagent suits your experiment?

Need Industrial/Bulk Grade? [Request Custom Synthesis Quote](#)

BenchChem

Our mission is to be the trusted global source of essential and advanced chemicals, empowering scientists and researchers to drive progress in science and industry.

Contact

Address: 3281 E Guasti Rd
Ontario, CA 91761, United States
Phone: (601) 213-4426
Email: info@benchchem.com

[Contact our Ph.D. Support Team for a compatibility check](#)