

A Comparative Guide to Xenon-Based Pulmonary Imaging: Cross-Validation with Established Modalities

Author: BenchChem Technical Support Team. **Date:** December 2025

Compound of Interest

Compound Name: Xenon-131

Cat. No.: B1250047

[Get Quote](#)

An Objective Analysis of Hyperpolarized ^{129}Xe MRI and ^{133}Xe SPECT for Researchers and Drug Development Professionals

This guide provides a comprehensive comparison of xenon-based functional lung imaging techniques—hyperpolarized Xenon-129 Magnetic Resonance Imaging (^{129}Xe MRI) and Xenon-133 Single-Photon Emission Computed Tomography (^{133}Xe SPECT)—with established modalities such as Computed Tomography (CT). While the initial inquiry specified **Xenon-131**, it is important to clarify that ^{129}Xe and ^{133}Xe are the predominant xenon isotopes utilized in clinical and research imaging settings. This document synthesizes experimental data to offer a clear, objective overview for researchers, scientists, and professionals in drug development.

At a Glance: Quantitative Comparison of Imaging Modalities

The following tables summarize key quantitative performance indicators for hyperpolarized ^{129}Xe MRI, ^{133}Xe SPECT, and CT in the context of pulmonary imaging.

Parameter	Hyperpolarized ^{129}Xe MRI	^{133}Xe SPECT	Computed Tomography (CT)
Spatial Resolution	High (typically ~3 mm) [1]	Lower than MRI and CT	Very High (sub-millimeter)[2]
Temporal Resolution	Rapid (images acquired in a <10s breath-hold)[2]	Slower (dynamic imaging over several minutes)[3]	Very Rapid (seconds for full chest scan)
Functional Information	Ventilation, gas exchange, alveolar microstructure[4]	Ventilation	Primarily anatomical, indirect functional information
Ionizing Radiation	None[4]	Yes[5]	Yes[5]
Effective Radiation Dose	0 mSv	~1.2 mSv (for ventilation scan)	2-7 mSv (low-dose to standard chest CT)[6] [7]
Primary Application	Detailed regional assessment of lung function	Routine clinical ventilation assessment	High-resolution anatomical imaging

In-Depth Analysis: Experimental Protocols and Methodologies

A clear understanding of the experimental protocols is crucial for interpreting imaging data and designing future studies. This section details the typical methodologies for hyperpolarized ^{129}Xe MRI and ^{133}Xe SPECT ventilation imaging.

Hyperpolarized ^{129}Xe MRI: Experimental Protocol

Hyperpolarized ^{129}Xe MRI offers a radiation-free method to visualize lung ventilation and gas exchange with high resolution. The process involves enhancing the nuclear magnetic resonance signal of ^{129}Xe gas, which is then inhaled by the subject.

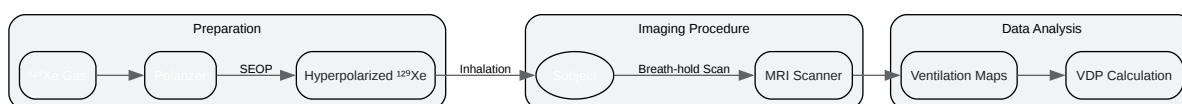
1. Hyperpolarization of ^{129}Xe : Isotopically enriched ^{129}Xe gas is hyperpolarized using a specialized apparatus (a polarizer). This process significantly increases the MR signal by

orders of magnitude, making the gas visible on MRI.[1]

2. Gas Administration: The subject inhales a mixture containing the hyperpolarized ^{129}Xe gas, typically holding their breath for the duration of the scan (around 10-20 seconds).[1]

3. MR Imaging: A standard clinical MRI scanner (e.g., 1.5T or 3T) is used to acquire images.[8] Specific radiofrequency coils and pulse sequences are employed to detect the ^{129}Xe signal.[9] Ventilation-weighted images are typically acquired using fast gradient echo sequences.[9]

4. Data Analysis: The resulting images provide a detailed map of gas distribution within the lungs. Quantitative analysis can be performed to calculate metrics such as the ventilation defect percentage (VDP), which represents the proportion of the lung that is not well-ventilated.[1]



[Click to download full resolution via product page](#)

Fig 1. Experimental workflow for hyperpolarized ^{129}Xe MRI.

^{133}Xe SPECT: Experimental Protocol

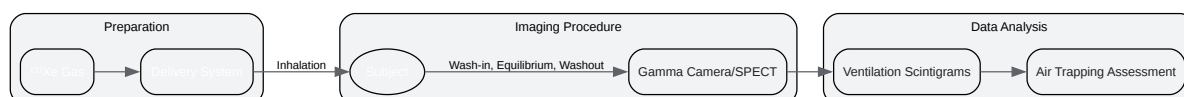
^{133}Xe SPECT is a well-established nuclear medicine technique for assessing lung ventilation. It involves the inhalation of a radioactive tracer, and the detection of emitted gamma rays.

1. Radiopharmaceutical Administration: The patient inhales a small, controlled dose of radioactive ^{133}Xe gas (typically 370–740 MBq) through a specialized delivery system.[10]

2. Imaging Acquisition: A gamma camera detects the gamma rays emitted by the ^{133}Xe as it distributes throughout the lungs. The imaging process typically consists of three phases:

- Wash-in (Single Breath): An initial image is taken as the patient takes a deep breath and holds it.[10]

- Equilibrium: The patient rebreathes the ^{133}Xe -air mixture for several minutes until the gas is evenly distributed in the ventilated parts of the lungs.[10]
 - Washout: The patient breathes normal air, and serial images are taken as the ^{133}Xe is cleared from the lungs.[10]
3. SPECT Imaging: For a 3D view, a SPECT scan can be performed, where the gamma camera rotates around the patient to acquire cross-sectional images.[11]
4. Data Analysis: The resulting images reveal areas of normal and abnormal ventilation. Delayed washout can indicate air trapping, a hallmark of obstructive lung diseases.[3]



[Click to download full resolution via product page](#)

Fig 2. Experimental workflow for ^{133}Xe SPECT ventilation imaging.

Cross-Validation and Comparative Performance

Direct comparisons between these xenon-based techniques and with CT have highlighted their respective strengths and weaknesses.

Hyperpolarized ^{129}Xe MRI vs. ^{133}Xe SPECT/Scintigraphy: Studies directly comparing ^{129}Xe MRI with ^{133}Xe scintigraphy have shown that ^{129}Xe MRI offers superior spatial resolution.[12][13] This allows for a more detailed visualization of ventilation defects. There is a good correlation between the ventilation defect percentages (VDP) measured by both techniques, indicating that they provide comparable information on the extent of ventilation abnormalities.[14] However, the lack of ionizing radiation with ^{129}Xe MRI is a significant advantage, particularly for longitudinal studies and in pediatric populations.[4]

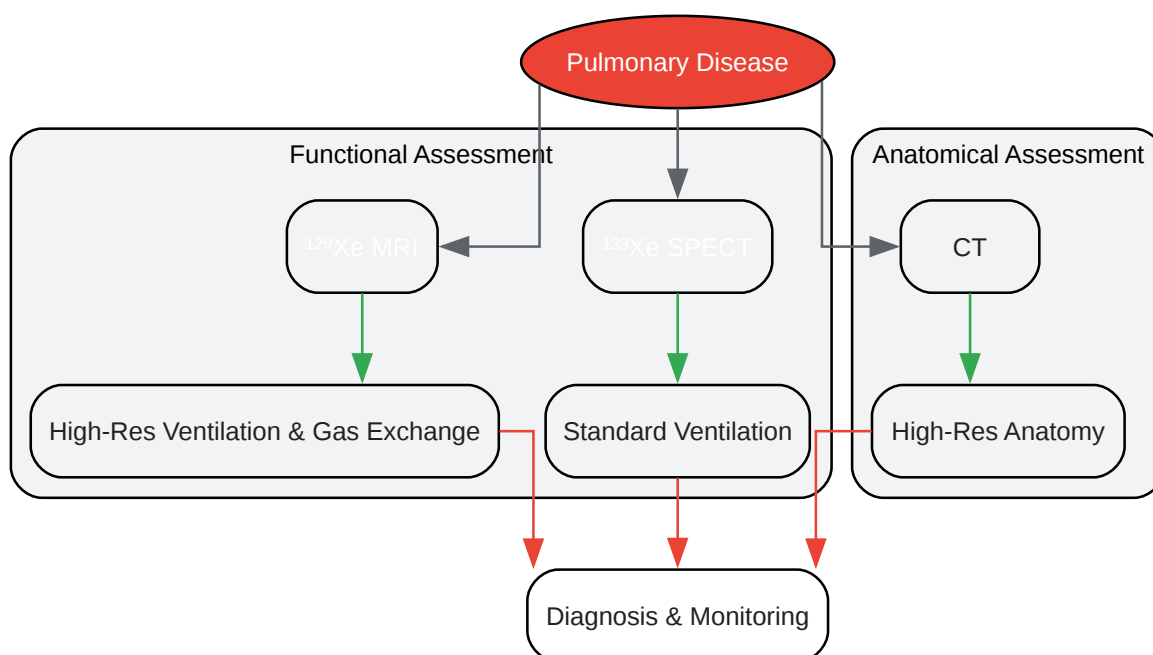
Hyperpolarized ^{129}Xe MRI vs. CT: While CT provides unparalleled anatomical detail of the lung parenchyma, it offers limited direct information on lung function.[2] In contrast, ^{129}Xe MRI

directly visualizes ventilation and can detect functional abnormalities that may not be apparent on a structural CT scan.[2] For instance, ^{129}Xe MRI can identify ventilation heterogeneity in patients with asthma or COPD, even when their CT scans appear relatively normal.[12] Some studies have shown a strong correlation between lobar ventilation measured by ^{129}Xe MRI and emphysema scores derived from CT.[15]

^{133}Xe SPECT vs. CT: ^{133}Xe SPECT is often used in conjunction with a perfusion scan (VQ scan) for the diagnosis of pulmonary embolism, where a mismatch between ventilation and perfusion is indicative of the condition. When combined with CT (SPECT/CT), the functional information from the ^{133}Xe scan can be precisely localized within the anatomical framework provided by the CT.[11] This hybrid imaging approach improves diagnostic accuracy compared to either modality alone.

Logical Relationships in Pulmonary Imaging

The choice of imaging modality often depends on the specific clinical or research question being addressed. The following diagram illustrates the logical relationships and primary outputs of each technique.



[Click to download full resolution via product page](#)

Need Custom Synthesis?

BenchChem offers custom synthesis for rare earth carbides and specific isotopic labeling.

Email: info@benchchem.com or [Request Quote Online](#).

References

- 1. The role of hyperpolarized ¹²⁹Xe in MR imaging of pulmonary function - PMC [pmc.ncbi.nlm.nih.gov]
- 2. publications.ersnet.org [publications.ersnet.org]
- 3. Pulmonary Scintigraphy | Radiology Key [radiologykey.com]
- 4. emjreviews.com [emjreviews.com]
- 5. SPECT-CT in routine clinical practice: increase in patient radiation dose compared with SPECT alone - PubMed [pubmed.ncbi.nlm.nih.gov]
- 6. SPECT-CT Scan - InsideRadiology [insideradiology.com.au]
- 7. researchgate.net [researchgate.net]
- 8. Hyperpolarised xenon-129 diffusion-weighted magnetic resonance imaging for assessing lung microstructure in idiopathic pulmonary fibrosis | European Respiratory Society [publications.ersnet.org]
- 9. eprints.whiterose.ac.uk [eprints.whiterose.ac.uk]
- 10. auntminnie.com [auntminnie.com]
- 11. openmedscience.com [openmedscience.com]
- 12. mdpi.com [mdpi.com]
- 13. Carebox Connect [connect.careboxhealth.com]
- 14. Hyperpolarized ¹²⁹Xe MRI, ^{99m}Tc scintigraphy, and SPECT in lung ventilation imaging: a quantitative comparison - PubMed [pubmed.ncbi.nlm.nih.gov]
- 15. researchgate.net [researchgate.net]
- To cite this document: BenchChem. [A Comparative Guide to Xenon-Based Pulmonary Imaging: Cross-Validation with Established Modalities]. BenchChem, [2025]. [Online PDF]. Available at: [https://www.benchchem.com/product/b1250047#cross-validation-of-xenon-131-imaging-with-other-modalities]

Disclaimer & Data Validity:

The information provided in this document is for Research Use Only (RUO) and is strictly not intended for diagnostic or therapeutic procedures. While BenchChem strives to provide accurate protocols, we make no warranties, express or implied, regarding the fitness of this product for every specific experimental setup.

Technical Support: The protocols provided are for reference purposes. Unsure if this reagent suits your experiment? [[Contact our Ph.D. Support Team for a compatibility check](#)]

Need Industrial/Bulk Grade? [Request Custom Synthesis Quote](#)

BenchChem

Our mission is to be the trusted global source of essential and advanced chemicals, empowering scientists and researchers to drive progress in science and industry.

Contact

Address: 3281 E Guasti Rd
Ontario, CA 91761, United States
Phone: (601) 213-4426
Email: info@benchchem.com