

Navigating ^{18}F -FES PET Imaging: A Technical Support Guide

Author: BenchChem Technical Support Team. **Date:** December 2025

Compound of Interest

Compound Name: Fluoroestradiol F-18

Cat. No.: B1248494

[Get Quote](#)

For Researchers, Scientists, and Drug Development Professionals

This technical support center provides troubleshooting guidance and answers to frequently asked questions regarding protocol deviations in ^{18}F -FES PET studies. Adherence to standardized protocols is critical for ensuring the accuracy and reproducibility of study outcomes. This guide addresses common issues encountered during ^{18}F -FES experiments, offering solutions and detailed methodologies to mitigate the impact of these deviations.

Frequently Asked Questions (FAQs)

Q1: What is the recommended patient preparation for an ^{18}F -FES PET scan?

While no specific patient preparation was initially deemed necessary unless a contrast-enhanced CT is performed concurrently, recent studies suggest that dietary choices can influence image quality.[1] Meticulous patient preparation, including dietary restrictions, is crucial for obtaining high-quality images essential for accurate interpretation.[2] For ^{18}F -FES PET, patient preparation is generally less stringent than for ^{18}F -FDG PET; for instance, physical activity does not need to be avoided before injection.[3]

Q2: How does food intake affect ^{18}F -FES uptake and image quality?

Food intake can significantly impact physiological ^{18}F -FES uptake, particularly in the abdomen. ^{18}F -FES is metabolized in the liver and excreted through the gallbladder and bile ducts into the gastrointestinal tract, which can create high background activity.[1] One study found that a fatty

meal, such as a chocolate bar, consumed after tracer injection can decrease ^{18}F -FES uptake in the gallbladder and stomach, potentially improving the visualization of abdominal metastases. [1][4] Conversely, fasting can lead to higher tracer uptake in these organs.[1]

Q3: What are the common causes of high background signal in ^{18}F -FES PET images?

High physiological uptake in the liver, gallbladder, bile ducts, and gastrointestinal tract is a known limitation of ^{18}F -FES PET imaging.[1][5][6] This can obscure or mimic tumor lesions in the abdominal region.[4] Additionally, patient-specific factors like Sex Hormone-Binding Globulin (SHBG) levels can influence tracer uptake and availability.[7][8][9]

Q4: Can recent or ongoing treatments interfere with ^{18}F -FES study outcomes?

Yes. Patients who have recently used ER antagonists may show significantly lower ^{18}F -FES uptake in tumors.[10] It is recommended that ER antagonists be discontinued for more than five weeks before imaging.[1]

Q5: What is the recommended dose and administration procedure for ^{18}F -FES?

The recommended intravenous dose of ^{18}F -FES is 222 MBq (6 mCi), with an acceptable range of 111–222 MBq (3–6 mCi).[3] The injection should be administered over 1-2 minutes, followed by a saline flush.[3] It is preferable to inject the tracer in the arm contralateral to the primary tumor site.[3]

Q6: How can variability in ^{18}F -FES uptake between patients be addressed?

Patient factors such as Body Mass Index (BMI) and plasma levels of Sex Hormone-Binding Globulin (SHBG) can influence ^{18}F -FES uptake.[7][8] Higher BMI has been associated with greater FES uptake, though this effect may be mitigated by correcting the Standardized Uptake Value (SUV) for lean body mass (LBM).[7][8] Higher SHBG levels are inversely associated with FES SUV.[7][8][9] Measuring SHBG levels can help in the interpretation of FES uptake.[8]

Troubleshooting Guide

Issue	Potential Cause	Troubleshooting Steps
High background uptake in the abdomen obscuring lesions	Physiological excretion of ^{18}F -FES via the hepatobiliary system.	<ul style="list-style-type: none">- Consider a dietary intervention, such as administering a fatty meal (e.g., a chocolate bar) after tracer injection to promote gallbladder emptying.[1]- Increase the time interval between tracer injection and the start of the scan to allow for further clearance of background activity.[1][4]
Low tumor ^{18}F -FES uptake in a known ER-positive patient	<ul style="list-style-type: none">- Recent use of ER antagonists.- High plasma SHBG levels.	<ul style="list-style-type: none">- Confirm that the patient has discontinued ER antagonist therapy for at least 5 weeks.[1]- Measure plasma SHBG levels, as higher levels can be associated with lower FES uptake.[7][8]
Unexpected ^{18}F -FES uptake in non-tumor tissues	<ul style="list-style-type: none">- Physiological uptake in organs of metabolism and excretion (liver, gallbladder, intestines).- Radiation-induced inflammation or fibrosis.[11]	<ul style="list-style-type: none">- Correlate PET findings with anatomical imaging (CT or MRI) to differentiate physiological uptake from pathology.- Review the patient's prior treatment history, particularly radiation therapy to the thoracic area, which can lead to enhanced lung uptake.[11]
Variable ^{18}F -FES uptake across different metastatic sites	True biological heterogeneity of ER expression in metastases.	This may not be a protocol deviation but a reflection of the disease biology. ^{18}F -FES PET is valuable for identifying such heterogeneity. [5] [10]

Quantitative Data Summary

Table 1: Impact of Patient Preparation on Physiological ^{18}F -FES Uptake (SUVmean)

Organ	Chocolate Diet Group (Median SUVmean)	Fasting Group (Median SUVmean)	Control Group (No Restrictions) (Median SUVmean)	p-value
Gallbladder	2.8	6.1	4.3	0.015
Stomach Lumen	1.3	2.3	1.6	0.011

Data adapted from a study comparing different food intake protocols. The chocolate group consumed a 47g milk chocolate bar after tracer injection. The fasting group had no food intake for at least 4-6 hours prior to the scan. The control group had no dietary restrictions.[\[1\]](#)

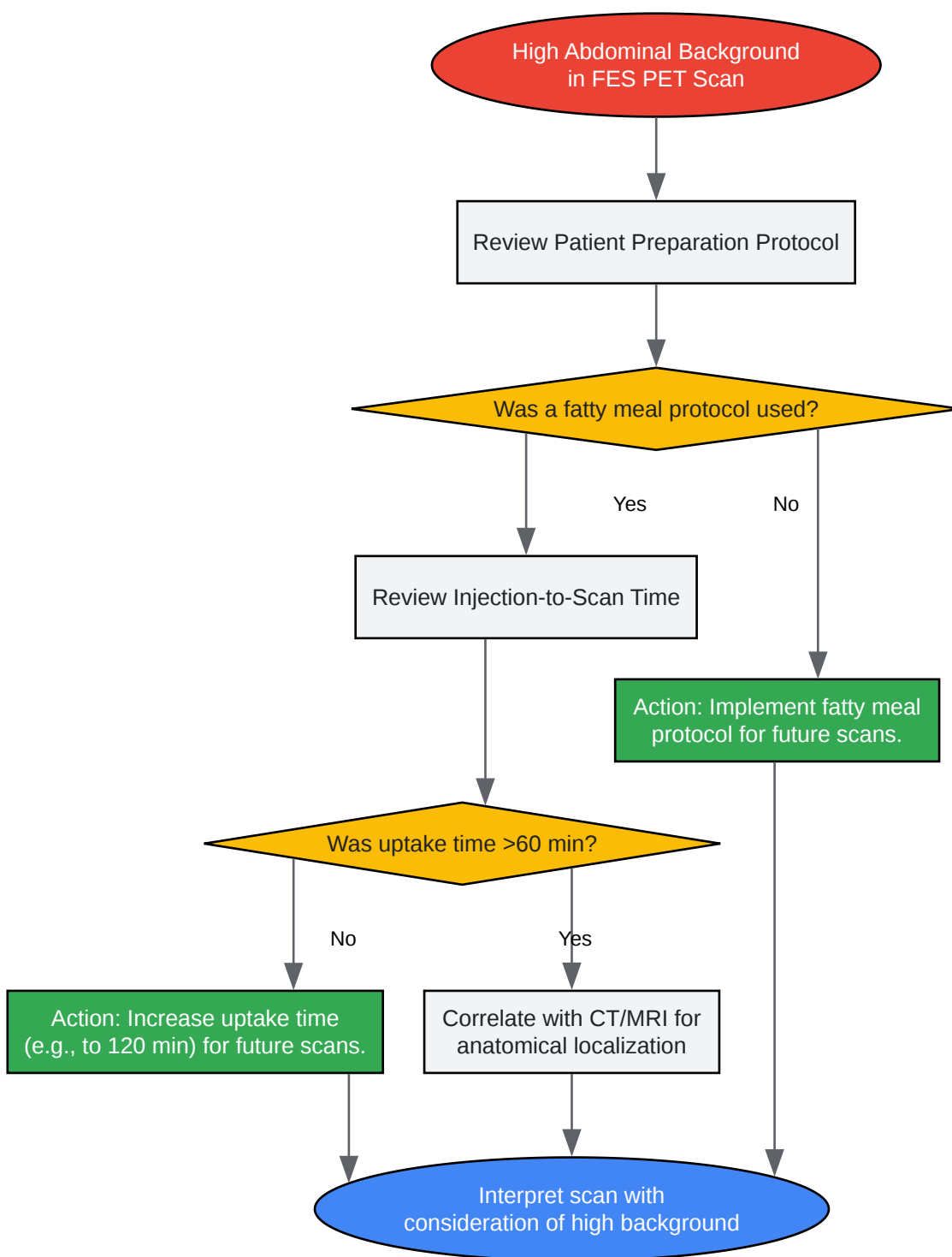
Detailed Experimental Protocols

Protocol: Fatty Meal Intervention to Reduce Abdominal Background

This protocol is designed to reduce the physiological ^{18}F -FES signal in the gallbladder and stomach, potentially improving the detection of metastases in the upper abdomen.

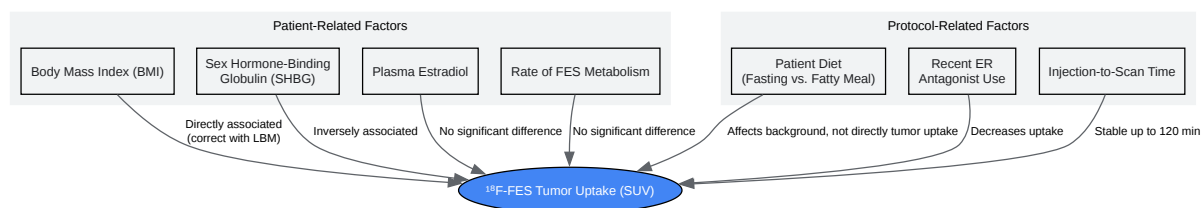
- Patient Preparation: No specific dietary restrictions are required before the tracer injection.
- Tracer Administration: Administer the standard dose of ^{18}F -FES intravenously.
- Fatty Meal Administration: Immediately following the ^{18}F -FES injection, provide the patient with a standardized fatty meal. A 47g milk chocolate bar (approximately 248 kcal, 14g of fat) has been shown to be effective.[\[1\]](#)
- Uptake Period: Allow for a standard uptake period of 60 minutes post-injection.
- Image Acquisition: Proceed with the standard PET/CT imaging protocol.

Visualizations



[Click to download full resolution via product page](#)

Caption: Troubleshooting workflow for high abdominal background in ^{18}F -FES PET.



[Click to download full resolution via product page](#)

Caption: Factors influencing ^{18}F -FES tumor uptake.

Need Custom Synthesis?

BenchChem offers custom synthesis for rare earth carbides and specific isotopic labeling.

Email: info@benchchem.com or [Request Quote Online](#).

References

1. Image Quality and Interpretation of $[^{18}\text{F}]$ -FES-PET: Is There any Effect of Food Intake? - PMC [pmc.ncbi.nlm.nih.gov]
2. ^{18}F -FDG PET and PET/CT patient preparation: a review of the literature - PubMed [pubmed.ncbi.nlm.nih.gov]
3. tech.snmjournals.org [tech.snmjournals.org]
4. pure.rug.nl [pure.rug.nl]
5. researchgate.net [researchgate.net]
6. Dynamic whole-body $[^{18}\text{F}]$ FES PET/CT increases lesion visibility in patients with metastatic breast cancer - PMC [pmc.ncbi.nlm.nih.gov]
7. Factors influencing the uptake of ^{18}F -Fluoroestradiol (FES) in patients with estrogen receptor positive (ER+) breast cancer - PMC [pmc.ncbi.nlm.nih.gov]
8. Factors influencing the uptake of ^{18}F -fluoroestradiol in patients with estrogen receptor positive breast cancer - PubMed [pubmed.ncbi.nlm.nih.gov]

- 9. researchgate.net [researchgate.net]
- 10. jnm.snmjournals.org [jnm.snmjournals.org]
- 11. Enhanced pulmonary uptake on 18F-FES-PET/CT scans after irradiation of the thoracic area: related to fibrosis? - PMC [pmc.ncbi.nlm.nih.gov]
- To cite this document: BenchChem. [Navigating ^{18}F -FES PET Imaging: A Technical Support Guide]. BenchChem, [2025]. [Online PDF]. Available at: [https://www.benchchem.com/product/b1248494#impact-of-protocol-deviations-on-f-fes-study-outcomes]

Disclaimer & Data Validity:

The information provided in this document is for Research Use Only (RUO) and is strictly not intended for diagnostic or therapeutic procedures. While BenchChem strives to provide accurate protocols, we make no warranties, express or implied, regarding the fitness of this product for every specific experimental setup.

Technical Support: The protocols provided are for reference purposes. Unsure if this reagent suits your experiment? [[Contact our Ph.D. Support Team for a compatibility check](#)]

Need Industrial/Bulk Grade? [Request Custom Synthesis Quote](#)

BenchChem

Our mission is to be the trusted global source of essential and advanced chemicals, empowering scientists and researchers to drive progress in science and industry.

Contact

Address: 3281 E Guasti Rd
Ontario, CA 91761, United States
Phone: (601) 213-4426
Email: info@benchchem.com