

Common artifacts in Rubidium-83 PET imaging and solutions

Author: BenchChem Technical Support Team. **Date:** April 2026

Compound of Interest

Compound Name: *Rubidium-83*

CAS No.: *17056-36-9*

Cat. No.: *B1235918*

[Get Quote](#)

Rubidium-82 PET Imaging Technical Support Center

Welcome to the technical support center for Rubidium-82 (Rb-82) PET imaging. This resource is designed for researchers, scientists, and drug development professionals to help identify and resolve common artifacts encountered during experimental procedures. Please note that the standard isotope for cardiac PET imaging is Rubidium-82, not **Rubidium-83**.

Frequently Asked Questions (FAQs)

Q1: What is the most common artifact in Rb-82 PET/CT imaging?

A1: The most prevalent artifact is misregistration between the PET emission data and the CT-based attenuation correction map.^{[1][2][3]} This misalignment can be caused by patient motion, including breathing and cardiac movement, which occurs between the fast CT scan and the longer PET acquisition.^{[4][5]}

Q2: How does patient motion affect the quantification of myocardial blood flow (MBF)?

A2: Patient motion is a significant source of error. Studies have shown that motion greater than 0.7 cm occurs in over 24% of dynamic Rb-82 PET scans and can lead to inaccuracies in MBF quantification exceeding 200%.^[6] This is primarily due to inconsistencies in the time-activity curves used for MBF calculation.^[6]

Q3: What are truncation artifacts and when do they occur?

A3: Truncation artifacts arise when the CT scanner's field of view (FOV), typically 50 cm, is smaller than the PET scanner's FOV, which is often 70 cm.^[7] This results in an incomplete attenuation map, leading to an underestimation of tracer activity in the regions outside the CT's FOV.^[7] This is more common in patients with a large body mass index.^[7]

Q4: Can the Rb-82 radiotracer itself cause artifacts?

A4: Yes, approximately 13% of rubidium decays are associated with prompt-gamma emissions that can be detected in coincidence with the annihilation photons.^[4] This can be a significant issue in 3D imaging, potentially creating artifactual defects if not properly corrected for in the reconstruction algorithm.^[4]

Q5: What is the "inferior wall overcorrection" artifact?

A5: This artifact is characterized by an artificially increased count density in the inferior wall of the left ventricle. It occurs when there is a mismatch between the diaphragm position on the CT and the averaged PET images, often seen when the lungs are hypoinflated on the CT scan.^[4]

Troubleshooting Guides

This section provides a systematic approach to identifying and resolving common artifacts in Rb-82 PET imaging.

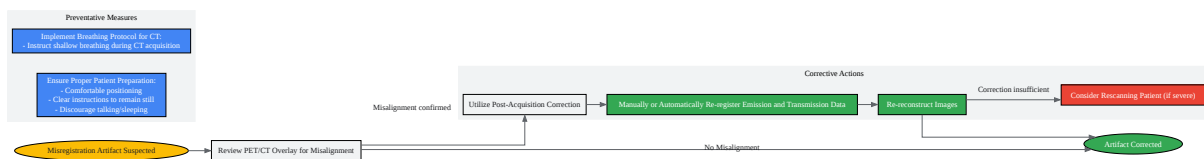
Guide 1: Misregistration Artifacts (Patient Motion & Breathing)

Symptoms:

- Apparent perfusion defects, often in a non-coronary distribution.

- Blurry images or abnormal shape of the left ventricle.[1]
- Visible misalignment when overlaying PET and CT images.

Troubleshooting Workflow:



[Click to download full resolution via product page](#)

Caption: Troubleshooting workflow for misregistration artifacts.

Detailed Steps:

- Prevention is Key:
 - Patient Comfort: Ensure the patient is in a comfortable position before starting the acquisition to minimize movement.
 - Clear Instructions: Instruct the patient to remain as still as possible and to avoid talking or sleeping during the scan.[1]

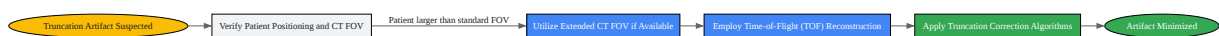- Breathing Instructions: For the CT portion, instruct the patient to perform shallow breathing to better match the averaged respiratory state of the PET scan.[1]
- Identification:
 - Carefully review the fused PET/CT images to identify any misalignment between the anatomical structures in the CT and the activity distribution in the PET scan.
- Correction:
 - Software Correction: Most modern imaging software allows for the manual or automatic re-registration of the emission (PET) and transmission (CT) data before image reconstruction.[1]
 - Re-reconstruction: After re-registration, the PET images should be reconstructed again using the corrected alignment.
 - Rescan: In cases of severe, uncorrectable motion, rescanning the patient may be the only option.[1]

Guide 2: Truncation Artifacts

Symptoms:

- Underestimation of tracer uptake in the periphery of the PET image.
- Often observed in larger patients where parts of the body extend beyond the CT field of view.

Troubleshooting Workflow:



[Click to download full resolution via product page](#)

Caption: Troubleshooting workflow for truncation artifacts.

Detailed Steps:

- Prevention and Acquisition:
 - Patient Positioning: Center the patient as accurately as possible within the scanner.
 - Extended FOV: If the scanner hardware and software support it, use an extended CT field of view for larger patients.[7]
- Reconstruction:
 - Time-of-Flight (TOF): TOF-based PET image reconstruction has been shown to be more robust and can reduce the impact of CT truncation.[7]
 - Correction Algorithms: Some imaging systems have specific software algorithms designed to correct for truncation artifacts.

Quantitative Data Summary

The following table summarizes the reported frequency and impact of common artifacts in Rb-82 PET imaging.

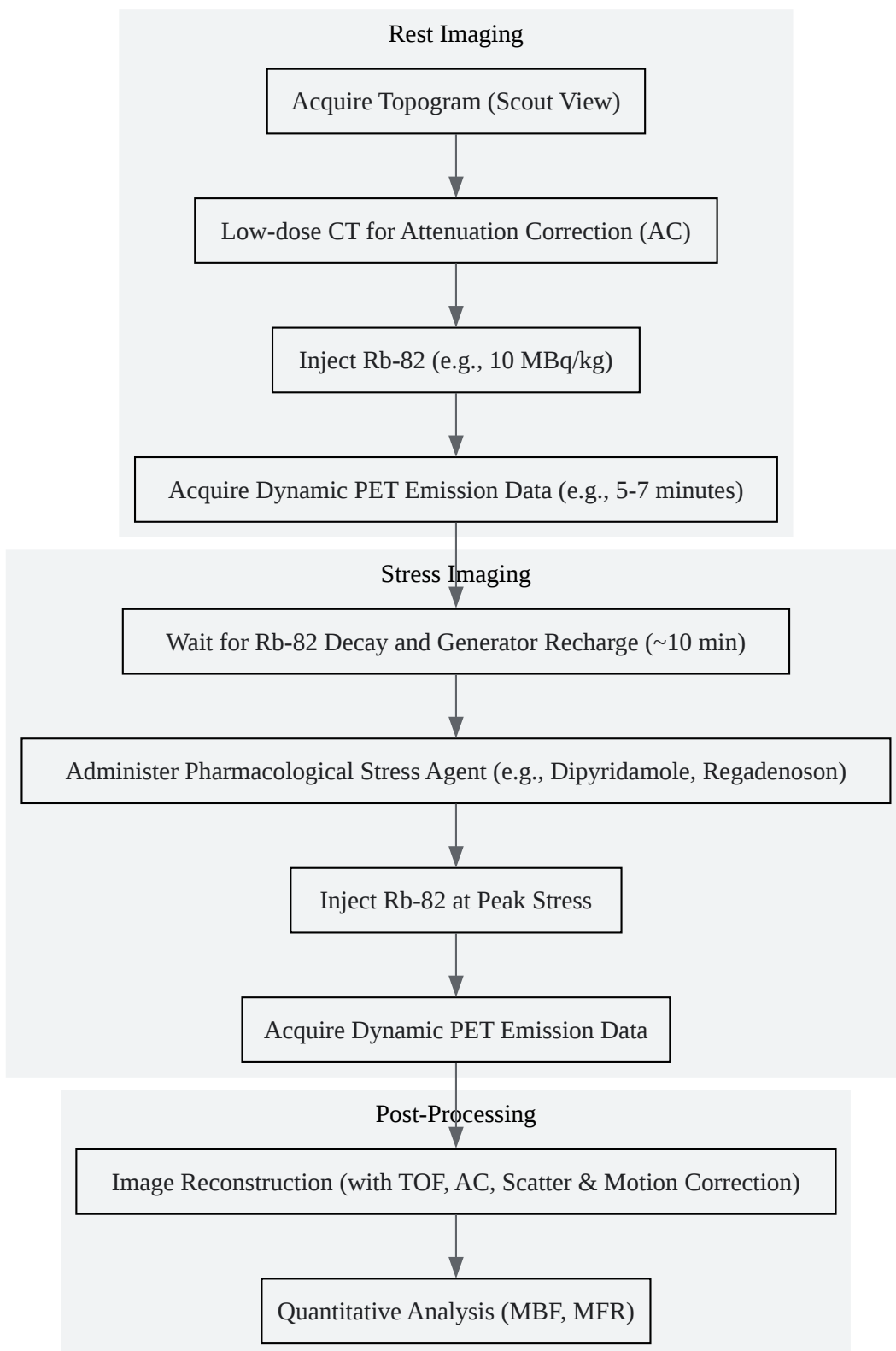
Artifact Type	Frequency / Impact	Reference
Attenuation-Emission Misregistration	21.4% of 1,177 studies showed artifactual defects.	[8]
Patient Body Motion (>0.7 cm)	Occurs in >24% of dynamic scans.	[6]
Impact of Motion on MBF	Can result in >200% error in Myocardial Blood Flow (MBF) quantification.	[6]
CTAC Misalignment Impact on MBF	CT misalignment alone can account for a 5% to 13% error in MBF measurements.	[6]
LV-Diaphragm Mismatch	Occurs in approximately 5% of cases.	[4]

Experimental Protocols

Standard Rb-82 PET/CT Myocardial Perfusion Imaging Protocol (Illustrative)

This is a generalized protocol; specific parameters may vary based on equipment and institutional guidelines.

Workflow Diagram:



[Click to download full resolution via product page](#)

Caption: Generalized workflow for a rest/stress Rb-82 PET/CT study.

Methodology:

- Patient Preparation: Patients are typically instructed to fast for 4-6 hours and abstain from caffeine for at least 12-24 hours prior to the scan.
- Rest Imaging:
 - A scout view (topogram) is acquired to determine the imaging field.
 - A low-dose CT scan is performed for attenuation correction.
 - The first dose of Rb-82 is administered intravenously.
 - Dynamic PET imaging begins 60-90 seconds after injection and continues for 5-7 minutes.
[7][8]
- Stress Imaging:
 - There is a waiting period of approximately 10 minutes to allow for the decay of the initial Rb-82 dose and for the Sr-82/Rb-82 generator to regenerate.
 - A pharmacological stress agent is administered.
 - At peak stress, a second dose of Rb-82 is injected.
 - A second dynamic PET acquisition is performed, similar to the rest scan.
- Image Reconstruction and Analysis:
 - Images are reconstructed using iterative algorithms (e.g., OSEM), incorporating corrections for attenuation, scatter, random coincidences, and detector dead time.[9] Time-of-flight (TOF) information is typically included to improve image quality.[9]
 - The reconstructed images are then used for qualitative assessment of perfusion and quantitative analysis of myocardial blood flow (MBF) and myocardial flow reserve (MFR).

Need Custom Synthesis?

BenchChem offers custom synthesis for rare earth carbides and specific isotopic labeling.

Email: info@benchchem.com or [Request Quote Online](#).

References

- [1. asnc.org \[asnc.org\]](https://www.asnc.org)
- [2. researchgate.net \[researchgate.net\]](https://www.researchgate.net)
- [3. Recognizing and preventing artifacts with SPECT and PET imaging | Radiology Key \[radiologykey.com\]](#)
- [4. Cardiac PET and PET/CT: Artifacts and Tracers | Thoracic Key \[thoracickey.com\]](#)
- [5. Pitfalls on PET/CT due to artifacts and instrumentation - PMC \[pmc.ncbi.nlm.nih.gov\]](#)
- [6. jnm.snmjournals.org \[jnm.snmjournals.org\]](https://www.jnm.snmjournals.org)
- [7. repositorio.ipl.pt \[repositorio.ipl.pt\]](https://repositorio.ipl.pt)
- [8. jnm.snmjournals.org \[jnm.snmjournals.org\]](https://www.jnm.snmjournals.org)
- [9. Cardiac PET/CT with Rb-82: optimization of image acquisition and reconstruction parameters - PMC \[pmc.ncbi.nlm.nih.gov\]](#)
- To cite this document: BenchChem. [Common artifacts in Rubidium-83 PET imaging and solutions]. BenchChem, [2026]. [Online PDF]. Available at: [\[https://www.benchchem.com/product/b1235918/docs#common-artifacts-in-rubidium-83-pet-imaging-and-solutions\]](https://www.benchchem.com/product/b1235918/docs#common-artifacts-in-rubidium-83-pet-imaging-and-solutions)

Disclaimer & Data Validity:

The information provided in this document is for Research Use Only (RUO) and is strictly not intended for diagnostic or therapeutic procedures. While BenchChem strives to provide accurate protocols, we make no warranties, express or implied, regarding the fitness of this product for every specific experimental setup.

Technical Support: The protocols provided are for reference purposes. Unsure if this reagent suits your experiment?

Need Industrial/Bulk Grade? [Request Custom Synthesis Quote](#)

BenchChem

Our mission is to be the trusted global source of essential and advanced chemicals, empowering scientists and researchers to drive progress in science and industry.

Contact

Address: 3281 E Guasti Rd
Ontario, CA 91761, United States
Phone: (601) 213-4426
Email: info@benchchem.com

[Contact our Ph.D. Support Team for a compatibility check](#)