

A Comparative Guide: Thallium-201 SPECT versus PET for Myocardial Viability Assessment

Author: BenchChem Technical Support Team. **Date:** April 2026

Compound of Interest

Compound Name: *Thallium-200*

CAS No.: *15720-55-5*

Cat. No.: *B1235120*

[Get Quote](#)

For researchers, scientists, and drug development professionals, selecting the optimal imaging modality to assess myocardial viability is critical for both clinical decision-making and the evaluation of novel therapeutic interventions. This guide provides an objective comparison of two cornerstone nuclear imaging techniques: Thallium-201 Single-Photon Emission Computed Tomography (SPECT) and Positron Emission Tomography (PET), with a focus on their diagnostic performance and procedural methodologies.

Myocardial viability assessment aims to distinguish between irreversibly damaged myocardium (scar) and dysfunctional but still living (hibernating or stunned) myocardium. This differentiation is crucial as viable myocardium has the potential to recover function following revascularization. While both Thallium-201 SPECT and PET are established methods for this purpose, they differ in their underlying principles, diagnostic accuracy, and procedural complexities. It is important to note that the commonly used thallium isotope for this application is Thallium-201, not **Thallium-200**.

Quantitative Comparison of Diagnostic Accuracy

The diagnostic performance of an imaging modality is paramount. The following table summarizes the quantitative data from various studies and meta-analyses comparing Thallium-201 SPECT and PET in predicting the recovery of myocardial function after revascularization.

Imaging Modality	Sensitivity	Specificity	Positive Predictive Value (PPV)	Negative Predictive Value (NPV)
Thallium-201 SPECT	82% (pooled)[1][2]	88% (pooled)[1][2]	72%[3]	70%[3]
FDG PET	92% (pooled)[4][5]	63% (pooled)[4][5]	83%[3]	84%[3]

These data indicate that while both techniques are valuable, 18F-Fluorodeoxyglucose (FDG) PET generally demonstrates higher sensitivity in detecting viable myocardium compared to Thallium-201 SPECT[4][5][6]. Conversely, some meta-analyses suggest that SPECT may have a higher pooled specificity[1][2]. The high negative predictive value of FDG PET is particularly noteworthy, as it provides strong evidence for the absence of viable tissue if the test is negative[3].

Experimental Protocols

Detailed and standardized protocols are essential for reproducible and reliable results. Below are the typical methodologies for Thallium-201 SPECT and FDG PET in the context of myocardial viability assessment.

Thallium-201 SPECT Protocol for Myocardial Viability

The principle behind Thallium-201 SPECT for viability assessment lies in the cellular uptake of thallium, a potassium analog, which requires intact cell membrane function.

- Patient Preparation: Fasting is preferred but not always necessary[7].
- Radiotracer Injection: 3-4 mCi of Thallium-201 is injected intravenously at rest[7][8].

- Initial Imaging (Rest): SPECT images are acquired approximately 10-15 minutes after injection[7][8].
- Delayed Imaging (Redistribution): A second set of SPECT images is acquired 3 to 5 hours after the initial injection[8]. In some protocols, a 24-hour delayed image may be acquired to enhance the detection of viability, and a small "booster" dose of Thallium-201 may be administered prior to this late imaging[7][8][9].
- Image Interpretation: Myocardial segments that show reduced uptake on initial images but demonstrate increased uptake on delayed "redistribution" images are considered to contain viable, hibernating myocardium[10]. Persistent defects are typically interpreted as scar tissue.

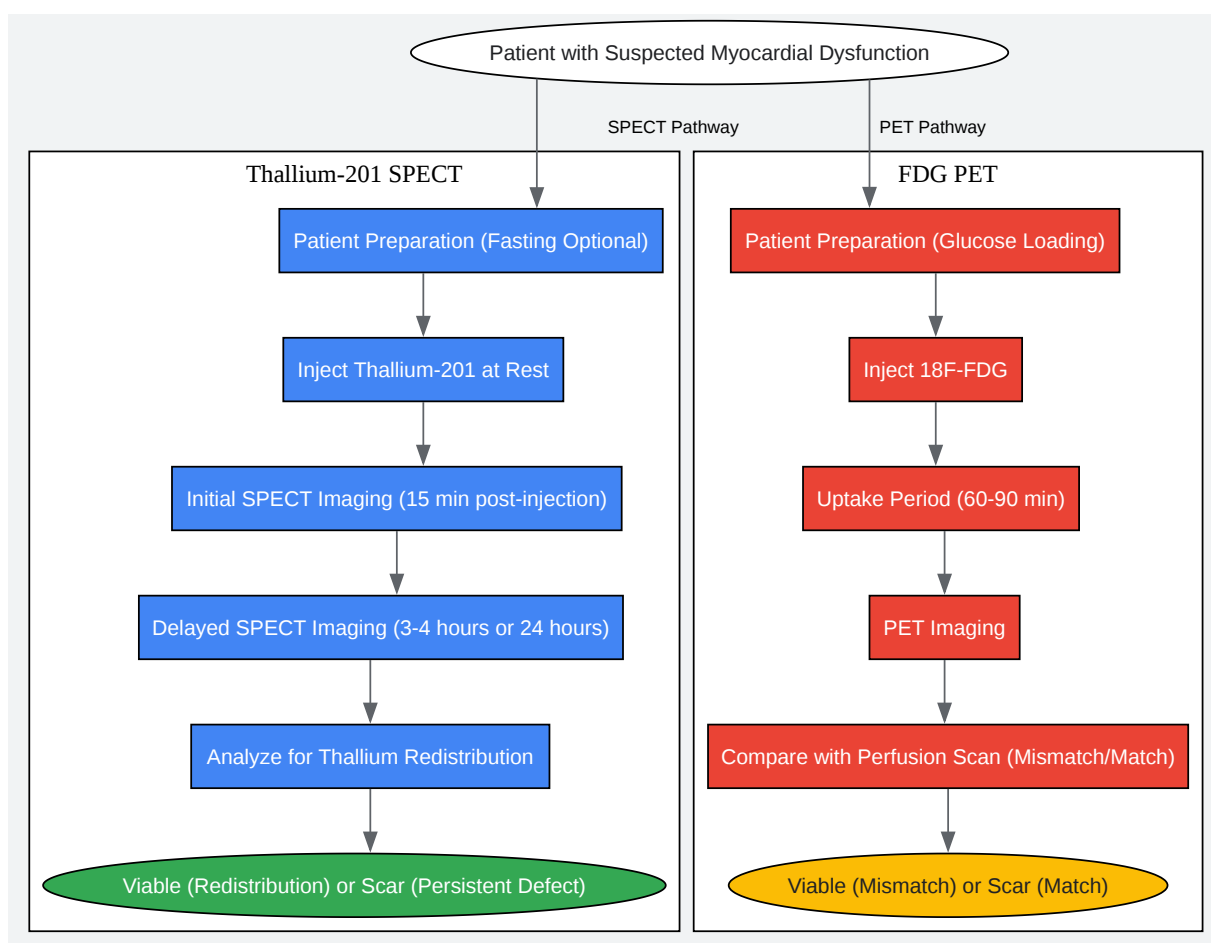
FDG PET Protocol for Myocardial Viability

FDG PET assesses myocardial viability by imaging glucose metabolism. Viable, ischemic myocardium preferentially utilizes glucose for energy.

- Patient Preparation: This is a critical step to ensure optimal FDG uptake by the myocardium. The patient is typically given a glucose load (e.g., 25-100g of oral glucose) to stimulate insulin secretion, which in turn promotes glucose uptake by myocardial cells[11][12][13]. In some cases, intravenous glucose and insulin may be administered[11][14].
- Radiotracer Injection: After adequate patient preparation and confirmation of appropriate blood glucose levels, 18F-FDG is injected intravenously.
- Uptake Period: There is a waiting period of 60-90 minutes to allow for the uptake of FDG by the myocardium[11].
- Imaging: PET scans are acquired to visualize the distribution of FDG in the heart.
- Image Interpretation: The FDG PET images are compared with myocardial perfusion images (often obtained from a preceding SPECT or PET perfusion scan). A "mismatch" pattern, where there is reduced perfusion but preserved or enhanced FDG uptake, is the hallmark of viable, hibernating myocardium[11][13]. A "match" pattern, with concordantly reduced perfusion and FDG uptake, suggests non-viable scar tissue[11].

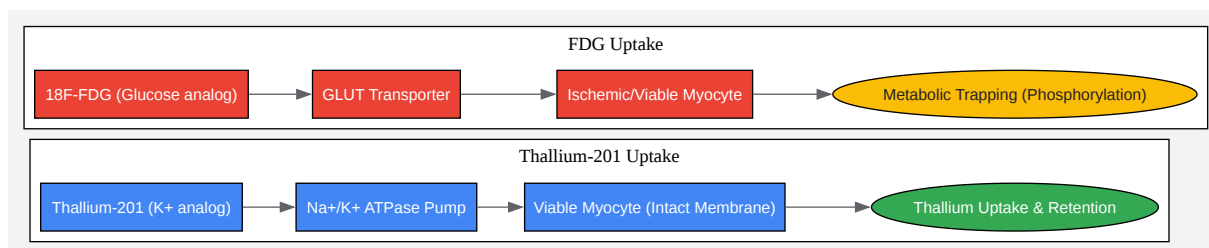
Workflow and Pathway Diagrams

To visualize the procedural flow and the underlying biological principles, the following diagrams are provided.



[Click to download full resolution via product page](#)

Caption: Workflow for myocardial viability assessment using Thallium-201 SPECT and FDG PET.



[Click to download full resolution via product page](#)

Caption: Cellular mechanisms of Thallium-201 and FDG uptake in viable myocytes.

Conclusion

Both Thallium-201 SPECT and FDG PET are well-validated and clinically useful techniques for the assessment of myocardial viability. FDG PET is generally considered the gold standard due to its higher sensitivity for detecting viable tissue, which is a critical factor in identifying patients who may benefit from revascularization[15]. However, Thallium-201 SPECT remains a widely available and valuable alternative[1][2]. The choice between these modalities may be influenced by factors such as local availability, cost, and the specific clinical question being addressed. For research and drug development purposes, the higher sensitivity and well-defined metabolic pathway of FDG PET may be advantageous for precisely quantifying changes in myocardial viability in response to therapeutic interventions.

Need Custom Synthesis?

BenchChem offers custom synthesis for rare earth carbides and specific isotopic labeling.

Email: info@benchchem.com or [Request Quote Online](#).

References

- 1. A meta-analysis comparing SPECT with PET for the assessment of myocardial viability in patients with coronary artery disease - PubMed [pubmed.ncbi.nlm.nih.gov]
- 2. [researchgate.net](https://www.researchgate.net) [[researchgate.net](https://www.researchgate.net)]
- 3. Role of thallium-201 and PET imaging in evaluation of myocardial viability and management of patients with coronary artery disease and left ventricular dysfunction - PubMed [pubmed.ncbi.nlm.nih.gov]
- 4. The importance of 18F-FDG cardiac PET/CT for the assessment of myocardial viability in ischaemic heart disease [[smw.ch](https://www.smw.ch)]
- 5. Diagnostic value of 18F-FDG PET in the assessment of myocardial viability in coronary artery disease: A comparative study with 99mTc SPECT and echocardiography - PMC [pubmed.ncbi.nlm.nih.gov]
- 6. Positron Emission Tomography for the Assessment of Myocardial Viability: An Evidence-Based Analysis - PMC [pubmed.ncbi.nlm.nih.gov]
- 7. Info - Thallium - Myocardial Viability Study [[info.radntx.com](https://www.info.radntx.com)]
- 8. [appliedradiology.com](https://www.appliedradiology.com) [[appliedradiology.com](https://www.appliedradiology.com)]
- 9. [ahajournals.org](https://www.ahajournals.org) [[ahajournals.org](https://www.ahajournals.org)]
- 10. [m.youtube.com](https://www.m.youtube.com) [[m.youtube.com](https://www.m.youtube.com)]
- 11. [jnm.snmjournals.org](https://www.jnm.snmjournals.org) [[jnm.snmjournals.org](https://www.jnm.snmjournals.org)]
- 12. [accesscardiology.mhmedical.com](https://www.accesscardiology.mhmedical.com) [[accesscardiology.mhmedical.com](https://www.accesscardiology.mhmedical.com)]
- 13. [asnc.org](https://www.asnc.org) [[asnc.org](https://www.asnc.org)]
- 14. 18F-FDG PET in Myocardial Viability Assessment: A Practical and Time-Efficient Protocol - PubMed [pubmed.ncbi.nlm.nih.gov]
- 15. Comparison of 18FDG PET with thallium SPECT in the assessment of myocardial viability. A segmental model analysis - PubMed [pubmed.ncbi.nlm.nih.gov]
- To cite this document: BenchChem. [A Comparative Guide: Thallium-201 SPECT versus PET for Myocardial Viability Assessment]. BenchChem, [2026]. [Online PDF]. Available at: [<https://www.benchchem.com/product/b1235120/docs#a-comparative-guide-thallium-201-spect-versus-pet-for-myocardial-viability-assessment>]

Disclaimer & Data Validity:

The information provided in this document is for Research Use Only (RUO) and is strictly not intended for diagnostic or therapeutic procedures. While BenchChem strives to provide accurate protocols, we make no warranties, express or implied, regarding the fitness of this product for every specific experimental setup.

Technical Support: The protocols provided are for reference purposes. Unsure if this reagent suits your experiment?

Need Industrial/Bulk Grade? [Request Custom Synthesis Quote](#)

BenchChem

Our mission is to be the trusted global source of essential and advanced chemicals, empowering scientists and researchers to drive progress in science and industry.

Contact

Address: 3281 E Guasti Rd
Ontario, CA 91761, United States
Phone: (601) 213-4426
Email: info@benchchem.com

[Contact our Ph.D. Support Team for a compatibility check](#)