

strategies to prevent and treat in-stent restenosis after PTCA

Author: BenchChem Technical Support Team. **Date:** December 2025

Compound of Interest

Compound Name: *Ptca*

Cat. No.: *B1218239*

[Get Quote](#)

Technical Support Center: In-Stent Restenosis (ISR) Research

Welcome to the technical support center for researchers, scientists, and drug development professionals engaged in the study of in-stent restenosis (ISR) following percutaneous transluminal coronary angioplasty (**PTCA**). This resource provides practical guidance, troubleshooting for common experimental issues, and answers to frequently asked questions to support your research and development efforts.

Section 1: Frequently Asked Questions (FAQs)

Q1: What is in-stent restenosis (ISR)?

A1: In-stent restenosis (ISR) is the re-narrowing of a blood vessel lumen within a previously implanted stent.^{[1][2]} It is fundamentally a healing response of the arterial wall to the mechanical injury caused by balloon angioplasty and stent implantation.^[3] While the introduction of stents dramatically reduced the rates of vessel remodeling and elastic recoil seen with balloon angioplasty alone, the presence of the stent itself triggers a process called neointimal hyperplasia.^{[1][4]} Angiographically, ISR is often defined as a luminal diameter reduction of 50% or more within the stented segment or at its edges.^{[5][6]}

Q2: What are the primary biological and mechanical mechanisms driving ISR?

A2: ISR is a multifactorial process involving both biological and mechanical factors.[6]

- **Biological Mechanisms:** The core biological driver is neointimal hyperplasia, which is the proliferation and migration of vascular smooth muscle cells (VSMCs) and the deposition of extracellular matrix.[1][5] This process is initiated by an inflammatory response to the vessel injury and stent implantation.[7][8] Over time, a new atherosclerotic process, termed neoatherosclerosis, can develop within the neointima and is a key factor in late ISR.[9][10]
- **Mechanical & Procedural Factors:** These are critical contributors to ISR. They include stent underexpansion (the stent is not fully expanded to the vessel wall), stent fracture, incomplete lesion coverage (geographic miss), and stent undersizing.[5][11][12] Intravascular imaging is often necessary to identify these underlying mechanical issues.[4][6]

Q3: How does ISR in Drug-Eluting Stents (DES) differ from that in Bare-Metal Stents (BMS)?

A3: While both stent types can develop ISR, the timing, underlying mechanisms, and angiographic patterns often differ.

- **BMS-ISR:** This is almost entirely due to aggressive neointimal hyperplasia and typically occurs within 6 to 12 months post-implantation.[9][11] It often presents as a diffuse pattern of narrowing throughout the stent.[11][13]
- **DES-ISR:** DES release antiproliferative drugs that significantly inhibit neointimal hyperplasia, drastically reducing ISR rates.[1][12] When DES-ISR does occur, it is often more focal (localized) and happens later.[13] The mechanisms are more complex and can include drug resistance, hypersensitivity reactions to the polymer or drug, stent fracture, and the development of neoatherosclerosis.[8][9][12]

Q4: What are the current leading strategies for preventing and treating ISR?

A4: Strategies are focused on both optimizing the initial procedure and treating ISR when it occurs.

- **Prevention:** The most effective prevention is the use of second-generation drug-eluting stents, which have significantly lowered ISR rates to <10%.[1][14] Optimal implantation techniques, guided by intravascular imaging (IVUS or OCT) to ensure proper stent expansion and apposition, are crucial to minimize mechanical causes of ISR.[9][15]

- Treatment: Treatment for ISR depends on the underlying cause.^[16] Options include implanting another DES (often with a different drug), using a drug-coated balloon (DCB) to deliver an antiproliferative agent without adding another metal layer, or performing atheroablative procedures like rotational atherectomy for significant tissue buildup.^{[1][11][17]} For recurrent ISR, intravascular brachytherapy (radiation) may be considered.^[17]

Q5: How is the severity of ISR quantified in a research setting?

A5: Several imaging and measurement techniques are used to quantify ISR.

- Quantitative Coronary Angiography (QCA): This is the traditional standard, measuring the minimum lumen diameter (MLD) and percent diameter stenosis to assess the degree of narrowing.^{[5][18]} Key metrics include Late Lumen Loss (LLL), which is the difference between the MLD immediately after the procedure and at follow-up.^[2]
- Intravascular Ultrasound (IVUS): Provides cross-sectional images of the vessel, allowing for precise measurement of stent area, lumen area, and neointimal hyperplasia area. It is invaluable for identifying stent underexpansion.^[9]
- Optical Coherence Tomography (OCT): Offers much higher resolution than IVUS, enabling detailed characterization of the neointima, assessment of stent strut coverage, and identification of neoatherosclerosis.^[19]
- Functional Assessment: Techniques like Fractional Flow Reserve (FFR) and Quantitative Flow Ratio (QFR) measure the physiological significance of the stenosis by assessing blood flow and pressure, which angiography alone cannot do.^{[20][21]}

Section 2: Troubleshooting Guides for Researchers

Problem 1: High variability in neointimal formation in our animal model.

- Possible Cause: Inconsistent arterial injury during stent implantation. The degree of initial injury is a primary determinant of the subsequent hyperplastic response.
- Troubleshooting Steps:

- Standardize Stent-to-Artery Ratio: Ensure a consistent balloon-to-artery ratio (typically 1.1-1.2:1) across all animals to normalize the degree of vessel stretch and injury.
- Verify Balloon Pressure & Inflation Time: Use a calibrated inflation device and maintain a consistent inflation pressure and duration for every procedure.
- Refine Surgical Technique: Minimize vessel handling and trauma outside of the target stented segment. Ensure the operator is highly proficient and follows a standardized protocol.
- Animal Selection: Use animals from a single supplier that are closely matched for age and weight to reduce biological variability. The rabbit iliac artery and porcine coronary artery are well-established models.[\[22\]](#)

Problem 2: Our novel antiproliferative drug is effective in vitro but shows no significant reduction of ISR in vivo.

- Possible Cause: Issues with drug delivery, bioavailability, or the chosen in vivo model.
- Troubleshooting Steps:
 - Analyze Drug Release Kinetics: Is the drug being released from the stent coating at the correct rate and for a sufficient duration? The peak of smooth muscle cell proliferation in animal models occurs around 7 days, with neointimal growth peaking by 28 days.[\[3\]](#)[\[23\]](#) Ensure your release profile matches this therapeutic window.
 - Assess Biocompatibility: The polymer or coating itself may be causing an excessive inflammatory reaction that counteracts the drug's effect. Perform histology on control (coating-only) stents to evaluate the baseline inflammatory response.
 - Evaluate Drug Concentration: The dose delivered to the tissue may be insufficient. Consider formulating different drug concentrations and testing them in parallel.
 - Consider the Animal Model: The healing response in animals is faster and more aggressive than in humans.[\[23\]](#) A drug that works in humans may be overwhelmed by the aggressive proliferation in a healthy porcine or rabbit model. Consider if the model is appropriate for the drug's mechanism of action.

Problem 3: Difficulty differentiating between neointimal hyperplasia and neoatherosclerosis in histological samples.

- Possible Cause: These are distinct but related processes that can be challenging to distinguish with basic staining. Neoatherosclerosis is characterized by the presence of lipid-laden foam cells (macrophages).^[10]
- Troubleshooting Steps:
 - Use Specific Immunohistochemical Stains:
 - Smooth Muscle Cells (SMCs): Use an antibody against alpha-smooth muscle actin (α -SMA) to identify the primary component of neointimal hyperplasia.
 - Macrophages/Foam Cells: Use a macrophage marker like CD68 or RAM-11 (in rabbits) to identify the lipid-filled cells characteristic of neoatherosclerosis.
 - Lipids: Oil Red O staining on frozen sections can be used to directly visualize lipid deposits.
 - Consider the Time Point: Neoatherosclerosis is a late-stage phenomenon.^[24] If your experimental endpoint is early (e.g., 28 days), you are likely observing primarily neointimal hyperplasia. In longer-term studies (>6 months), neoatherosclerosis becomes more prevalent.^[24]

Section 3: Data Presentation

Table 1: Comparison of Restenosis Outcomes by Stent Type

Feature	Bare-Metal Stent (BMS)	First-Generation DES (e.g., Sirolimus, Paclitaxel)	Second-Generation DES (e.g., Everolimus, Zotarolimus)
Angiographic Restenosis Rate	17% - 41% ^{[1][2]}	~13% - 16% (at 5 years) ^[14]	<10% ^{[1][2]}
Typical Time to ISR	3 - 12 months ^[9]	>12 months	>12 months, often very late
Primary ISR Mechanism	Neointimal Hyperplasia ^[11]	Late Catch-up, Neoatherosclerosis, Fracture ^{[12][13]}	Neoatherosclerosis, Mechanical/Procedural Issues ^[6]
Common Angiographic Pattern	Diffuse ^{[11][13]}	Focal ^[13]	Focal ^[13]

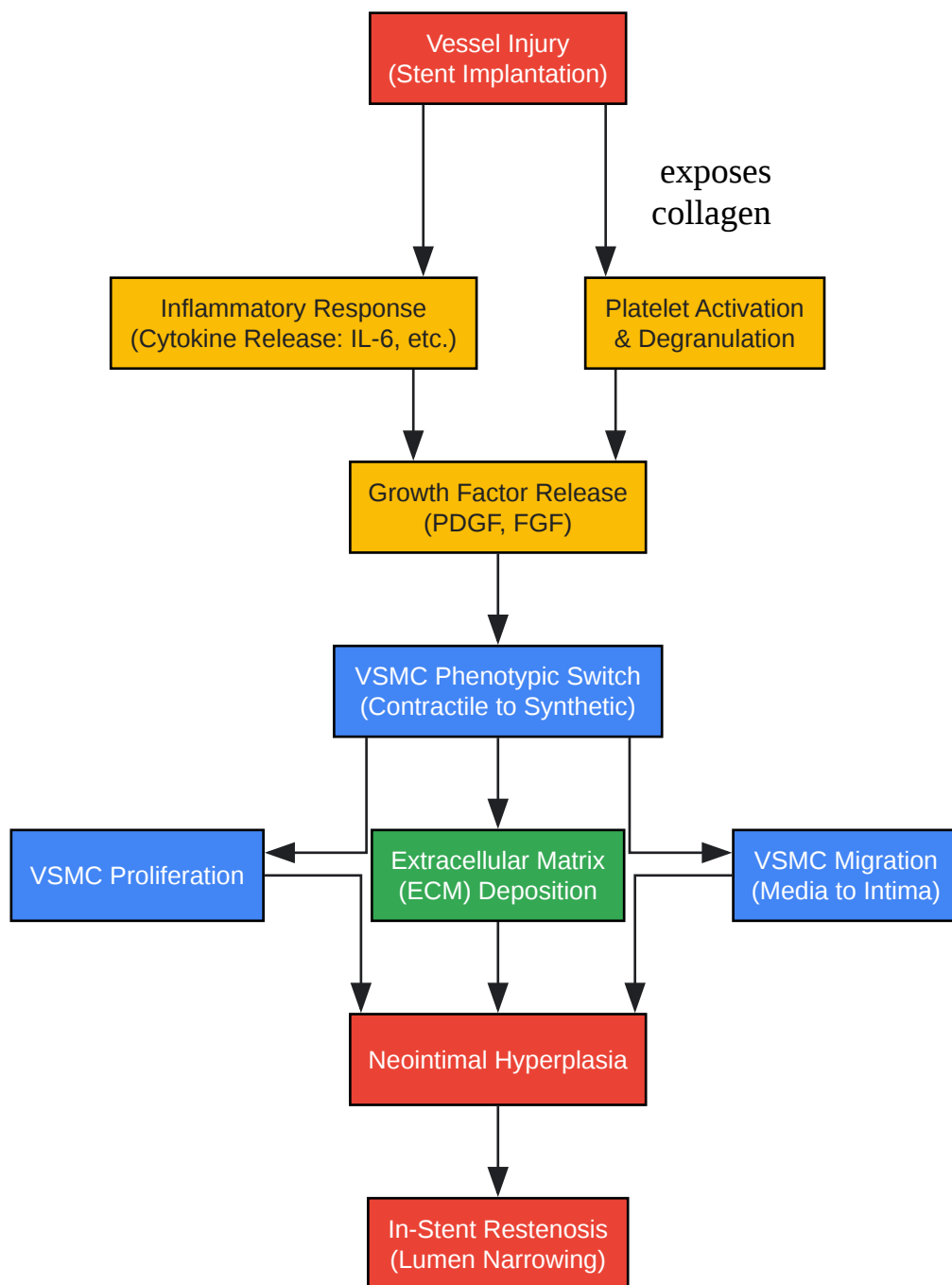
Table 2: Comparison of Key Imaging Modalities for ISR Research

Modality	Key Measurements	Axial Resolution	Advantages for ISR Research	Limitations
Quantitative Coronary Angiography (QCA)	Minimum Lumen Diameter (MLD), % Diameter Stenosis, Late Lumen Loss (LLL)[5]	~150-200 μm	Gold standard for luminal dimension, widely available. [18]	2D projection (lacks cross-sectional detail), underestimates plaque burden.
Intravascular Ultrasound (IVUS)	Stent/Lumen/Vessel Area, Plaque Burden, Neointimal Volume[9]	~150 μm [9]	Excellent for assessing stent expansion, apposition, and overall plaque/neointimal burden.[9]	Lower resolution than OCT, difficult to precisely define neointimal tissue interface.[9]
Optical Coherence Tomography (OCT)	Strut coverage, Neointimal thickness, Tissue characterization (e.g., lipid, thrombus)[19]	~10-20 μm	Unparalleled resolution for detailed neointimal assessment, identifying neoatherosclerosis, and evaluating stent apposition.	Requires blood clearance, limited penetration depth, may overestimate lumen due to blood speckle.

Section 4: Experimental Protocols & Visualizations

Key Signaling Pathway in ISR

The process of neointimal hyperplasia is driven by a cascade of signaling events following stent-induced injury. Inflammation is a key initiator, where cytokines stimulate growth factors that, in turn, cause vascular smooth muscle cells (VSMCs) to switch from a quiescent to a proliferative state, migrating into the intima to form the neointima.[7]

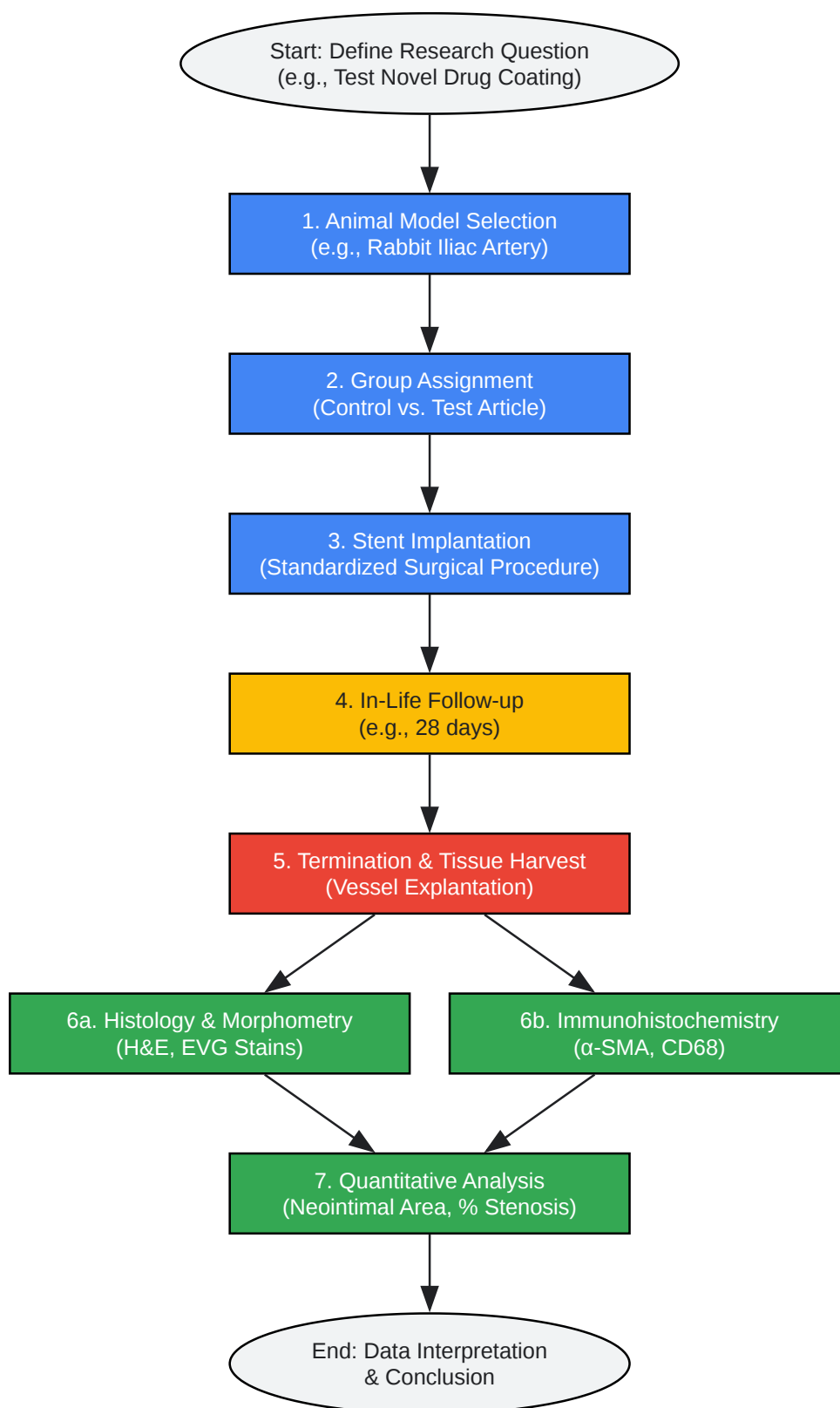


[Click to download full resolution via product page](#)

Core signaling cascade leading to neointimal hyperplasia and ISR.

Experimental Workflow for Preclinical ISR Studies

A typical preclinical study to evaluate a novel anti-restenotic therapy involves several key stages, from model selection and intervention to final analysis. This workflow ensures a systematic evaluation of the device or drug's efficacy and safety.



[Click to download full resolution via product page](#)

Standard workflow for a preclinical in-vivo study of ISR.

Protocol: Induction of In-Stent Restenosis in a Rabbit Iliac Artery Model

This protocol describes a widely used method for inducing and evaluating ISR in a preclinical setting.^[22]

1. Objective: To create a consistent model of neointimal hyperplasia following stent implantation in the rabbit iliac artery for the evaluation of anti-restenotic therapies.

2. Materials:

- New Zealand White rabbits (male, 3.0-3.5 kg)
- Anesthesia: Ketamine/Xylazine cocktail
- Surgical instruments for cutdown procedure
- Introducer sheath (e.g., 4-5 Fr)
- Guidewire (0.014")
- Angiography system (C-arm)
- Test and control stents (e.g., 3.0 mm diameter) mounted on appropriate balloon catheters
- Heparin, contrast agent
- Perfusion fixation solutions (Saline, 10% Neutral Buffered Formalin)

3. Methodology:

- Anesthesia and Preparation: Anesthetize the rabbit and place it on the surgical table in a supine position. Shave and sterilize the neck region for the carotid artery cutdown.
- Surgical Access: Perform a surgical cutdown to expose the common carotid artery. Make a small arteriotomy and insert the introducer sheath. Administer systemic heparin to achieve a target Activated Clotting Time (ACT) of >250 seconds.

- **Baseline Angiography:** Advance a guidewire through the sheath, down the aorta, and into the target iliac artery under fluoroscopic guidance. Perform a baseline angiogram using a contrast injection to visualize the vessel and measure its reference diameter.
- **Stent Deployment:** Advance the stent delivery system over the guidewire to the target location in the iliac artery. Deploy the stent by inflating the balloon to a nominal pressure, ensuring a stent-to-artery overstretch ratio of approximately 1.1:1 to 1.2:1. Maintain inflation for 30 seconds.
- **Post-Implantation Angiography:** Deflate the balloon and withdraw the delivery system. Perform a final angiogram to confirm successful stent deployment and patency.
- **Closure and Recovery:** Remove the introducer sheath and ligate the carotid artery. Close the surgical site in layers. Monitor the animal during recovery from anesthesia.
- **Follow-up Period:** Allow the animal to recover for a pre-determined period, typically 28 days, which corresponds to the peak neointimal response in this model.[\[23\]](#)
- **Termination and Tissue Collection:** At the endpoint, re-anesthetize the animal and perform a final angiogram. Euthanize the animal and perform perfusion fixation via the abdominal aorta, first with heparinized saline to clear blood, followed by 10% neutral buffered formalin.
- **Explantation:** Carefully dissect and explant the stented iliac arteries and preserve them in formalin for histological processing.

4. Analysis:

- **Histomorphometry:** Process the stented vessels into plastic or paraffin blocks. Cut cross-sections and stain with Hematoxylin and Eosin (H&E) and Verhoeff-Van Gieson (VVG) to visualize cell nuclei, cytoplasm, and elastic laminae.
- **Quantitative Measurements:** Using calibrated imaging software, measure the following on each cross-section: Lumen Area, Stent Area, Internal Elastic Lamina (IEL) Area, and External Elastic Lamina (EEL) Area.
- **Calculated Parameters:**

- Neointimal Area = IEL Area - Lumen Area
- Percent Area Stenosis = (Neointimal Area / IEL Area) * 100

Need Custom Synthesis?

BenchChem offers custom synthesis for rare earth carbides and specific isotopic labeling.

Email: info@benchchem.com or [Request Quote Online](#).

References

- 1. Understanding and managing in-stent restenosis: a review of clinical data, from pathogenesis to treatment - Buccheri - Journal of Thoracic Disease [jtd.amegroups.org]
- 2. Understanding and managing in-stent restenosis: a review of clinical data, from pathogenesis to treatment - PMC [pmc.ncbi.nlm.nih.gov]
- 3. ahajournals.org [ahajournals.org]
- 4. jacc.org [jacc.org]
- 5. eurointervention.pcronline.com [eurointervention.pcronline.com]
- 6. ahajournals.org [ahajournals.org]
- 7. academic.oup.com [academic.oup.com]
- 8. In-stent restenosis after percutaneous coronary intervention: emerging knowledge on biological pathways - PubMed [pubmed.ncbi.nlm.nih.gov]
- 9. Diagnosis and management challenges of in-stent restenosis in coronary arteries - PMC [pmc.ncbi.nlm.nih.gov]
- 10. youtube.com [youtube.com]
- 11. scai.org [scai.org]
- 12. In-Stent Restenosis in Drug-Eluting Stents: Issues and Therapeutic Approach - MedCrave online [medcraveonline.com]
- 13. ahajournals.org [ahajournals.org]
- 14. youtube.com [youtube.com]
- 15. jacc.org [jacc.org]
- 16. semanticscholar.org [semanticscholar.org]

- 17. researchgate.net [researchgate.net]
- 18. Quantitative measurements of in-stent restenosis: A comparison between quantitative coronary ultrasound and quantitative coronary angiography - PubMed [pubmed.ncbi.nlm.nih.gov]
- 19. Qualitative and Quantitative Assessment of Stent Restenosis by Optical Coherence Tomography [jstage.jst.go.jp]
- 20. Quantitative flow ratio for functional evaluation of in-stent restenosis: In-stent restenosis functional assessment with QFR - PMC [pmc.ncbi.nlm.nih.gov]
- 21. eurointervention.pcronline.com [eurointervention.pcronline.com]
- 22. A preclinical animal model for evaluating the sealing capacity of covered stent grafts in acute vessel perforation - PMC [pmc.ncbi.nlm.nih.gov]
- 23. Drug eluting stents: are human and animal studies comparable? - PMC [pmc.ncbi.nlm.nih.gov]
- 24. google.com [google.com]
- To cite this document: BenchChem. [strategies to prevent and treat in-stent restenosis after PTCA]. BenchChem, [2025]. [Online PDF]. Available at: [https://www.benchchem.com/product/b1218239#strategies-to-prevent-and-treat-in-stent-restenosis-after-ptca]

Disclaimer & Data Validity:

The information provided in this document is for Research Use Only (RUO) and is strictly not intended for diagnostic or therapeutic procedures. While BenchChem strives to provide accurate protocols, we make no warranties, express or implied, regarding the fitness of this product for every specific experimental setup.

Technical Support: The protocols provided are for reference purposes. Unsure if this reagent suits your experiment? [[Contact our Ph.D. Support Team for a compatibility check](#)]

Need Industrial/Bulk Grade? [Request Custom Synthesis Quote](#)

BenchChem

Our mission is to be the trusted global source of essential and advanced chemicals, empowering scientists and researchers to drive progress in science and industry.

Contact

Address: 3281 E Guasti Rd

Ontario, CA 91761, United States

Phone: (601) 213-4426

Email: info@benchchem.com