

Application Notes and Protocols: Advanced Imaging for PTCA Guidance

Author: BenchChem Technical Support Team. **Date:** December 2025

Compound of Interest

Compound Name: *Ptca*

Cat. No.: *B1218239*

[Get Quote](#)

For Researchers, Scientists, and Drug Development Professionals

These application notes provide a detailed overview of advanced imaging techniques for Percutaneous Transluminal Coronary Angioplasty (**PTCA**) guidance and assessment. The content is structured to provide actionable protocols and comparative data for researchers and professionals in drug development and cardiovascular science.

Intravascular Ultrasound (IVUS)

Intravascular Ultrasound (IVUS) is an invasive imaging modality that provides a 360-degree cross-sectional view of the coronary arteries. It utilizes a miniaturized ultrasound transducer mounted on a catheter to generate real-time images of the vessel lumen and wall, overcoming many of the limitations of traditional angiography.^[1]

Principles and Applications

IVUS is instrumental in characterizing lesion morphology, quantifying plaque burden, guiding stent sizing, assessing stent expansion, and identifying procedural complications.^[1] It provides a more accurate assessment of vessel size and lesion severity compared to coronary angiography, which often underestimates these parameters.^[2] IVUS is particularly valuable in complex PCI cases, such as those involving left main, bifurcation, or chronic total occlusion (CTO) lesions, and has been shown to improve clinical outcomes and reduce mortality.^{[3][4]}

Experimental Protocol: IVUS-Guided PTCA

Materials:

- IVUS catheter (e.g., solid-state or rotational transducer)
- IVUS imaging console and pullback device
- Standard **PTCA** equipment (guiding catheter, guidewire, balloons, stents)
- Heparin and intracoronary nitroglycerin

Procedure:

- Catheter Introduction and Preparation:
 - After coronary cannulation with a guiding catheter, administer heparin and intracoronary nitroglycerin.[\[5\]](#)[\[6\]](#)
 - Introduce a standard 0.014-inch guidewire across the target lesion.
 - Advance the IVUS catheter over the guidewire and position it distal to the lesion.[\[6\]](#)
- Pre-Intervention Imaging (Lesion Assessment):
 - Perform an automated or manual pullback of the IVUS catheter through the lesion to the proximal vessel.[\[5\]](#) A motorized pullback is recommended for accurate length measurements.[\[5\]](#)[\[6\]](#)
 - Record images continuously for later analysis.[\[5\]](#)[\[6\]](#)
 - Measurements and Assessment:
 - Lumen, Plaque, and Vessel Dimensions: Measure the minimum lumen area (MLA), plaque burden, and external elastic membrane (EEM) area.
 - Plaque Morphology: Characterize the plaque as calcified, fibrotic, or lipid-rich.[\[1\]](#)
 - Stent Sizing:

- Diameter: Select the stent diameter based on the distal reference EEM diameter (rounding down to the nearest available size) or the distal reference lumen diameter (rounding up).
- Length: Determine the stent length to ensure coverage of the entire lesion with landing zones in healthy vessel segments (plaque burden <50%).
- Stent Implantation and Post-Dilation:
 - Based on the IVUS assessment, perform lesion preparation (e.g., pre-dilation, atherectomy) if necessary.
 - Deploy the selected stent.
 - Perform post-dilation with a non-compliant balloon sized according to the IVUS measurements.
- Post-Intervention Imaging (Stent Assessment):
 - Perform a final IVUS pullback through the stented segment.
 - Assess for:
 - Stent Expansion: The minimum stent area (MSA) should be >80-90% of the average of the proximal and distal reference lumen areas. For left main lesions, an MSA >8 mm² is often targeted.[\[3\]](#)
 - Stent Apposition: Ensure the stent struts are in complete contact with the vessel wall.
 - Edge Dissections: Identify and assess the severity of any dissections at the stent edges. A major dissection (>60° arc and >3mm in length) may require an additional stent.[\[3\]](#)
 - Complications: Look for evidence of thrombus or intramural hematoma.

Quantitative Data Summary

Parameter	IVUS-Guided PCI	Angiography-Guided PCI	Reference
Stent Sizing			
Stent Diameter	Based on EEM or lumen measurements	Based on 2D lumenogram	[7]
Stent Length	Covers entire plaque burden	Visual estimation of lesion length	[3]
Post-PCI Outcomes			
Minimum Stent Area (MSA)	Larger	Smaller	[8]
Stent Underexpansion	Less frequent	More frequent	[9]
Major Adverse Cardiac Events (MACE)	Significantly lower	Higher	[3][4]
Target Lesion Failure	Reduced by ~33%	Higher	[10]
Cardiac Death	Reduced by ~46%	Higher	[10]
Stent Thrombosis	Reduced by ~52%	Higher	[10]

Optical Coherence Tomography (OCT)

Optical Coherence Tomography (OCT) is a light-based intravascular imaging modality that provides extremely high-resolution images (10-20 μm), approximately 10 times higher than IVUS.[11] This allows for detailed visualization of the coronary artery microstructure.

Principles and Applications

OCT excels at detailed plaque characterization, including the identification of fibrous, calcified, and lipid-rich plaques, as well as thin-cap fibroatheromas.[11] It is superior to IVUS for detecting stent-related issues such as malapposition, edge dissections, and tissue protrusion. [12][13] However, its penetration depth is less than IVUS, and it requires a blood-free field for imaging, necessitating the use of a contrast flush.[1][11]

Experimental Protocol: OCT-Guided PTCA

Materials:

- OCT catheter and imaging console
- Contrast medium and power injector or manual syringe
- Standard **PTCA** equipment

Procedure:

- Catheter Introduction and Preparation:
 - Engage the coronary artery with a guiding catheter (≥ 6 Fr is recommended).[11]
 - Administer heparin.
 - Advance a 0.014-inch guidewire across the lesion.
 - Position the OCT catheter distal to the region of interest.[14]
- Pre-Intervention Imaging:
 - Perform an automated pullback of the OCT catheter while injecting contrast to clear blood from the field of view.[1][14]
 - Assessment:
 - Plaque Morphology: Characterize plaque as fibrous, lipid-rich, or calcified to guide lesion preparation. Calcified lesions may require atherectomy or lithotripsy.[15]
 - Stent Sizing:
 - Diameter: Typically based on the average of the proximal and distal reference lumen diameters.
 - Length: Determined by identifying healthy landing zones with minimal plaque.

- Stent Implantation and Post-Dilation:
 - Perform lesion preparation as indicated by the OCT findings.
 - Deploy the appropriately sized stent.
 - Perform post-dilation as needed.
- Post-Intervention Imaging:
 - Perform a final OCT pullback.
 - Assess for:
 - Stent Expansion: Aim for >80% expansion relative to the reference lumen area, with >90% being optimal.[16]
 - Stent Apposition: The software can automatically detect malapposed struts.
 - Edge Dissections: Identify and classify dissections. Medial dissections >1 quadrant may require further intervention.[16]
 - Tissue Protrusion and Thrombus: Evaluate for any prolapse of tissue through the stent struts or the presence of thrombus.

Quantitative Data Summary

Parameter	OCT-Guided PCI	IVUS-Guided PCI	Angiography-Guided PCI	Reference
Resolution	10-20 μm	100-150 μm	N/A	[11]
Penetration Depth	1-2 mm	4-8 mm	N/A	[11]
Post-PCI Minimum Stent Area (mm^2)	5.72	5.89	5.36	[8]
Detection of Stent Malapposition	High	Moderate	Low	[13]
Detection of Edge Dissection	High	Moderate	Low	[13]
Target Vessel Failure (2 years)	7.4%	N/A	8.2%	[8]

Fractional Flow Reserve (FFR)

Fractional Flow Reserve (FFR) is a physiological measurement used to determine the hemodynamic significance of a coronary stenosis. It is defined as the ratio of the maximum blood flow distal to a stenosis to the maximum blood flow in the same vessel if it were normal. [17] In practice, it is calculated as the ratio of the pressure distal to the stenosis (P_d) to the pressure proximal to the stenosis (P_a) during maximal hyperemia.[18]

Principles and Applications

FFR provides a functional assessment of a lesion's severity, complementing the anatomical information from angiography, IVUS, or OCT. It is particularly useful for intermediate lesions (40-70% stenosis on angiography) to determine if revascularization is warranted.[12] An FFR value of ≤ 0.80 is generally considered indicative of a hemodynamically significant stenosis that would benefit from intervention.[18][19]

Experimental Protocol: FFR Measurement

Materials:

- FFR pressure wire
- FFR console
- Guiding catheter (without side holes is preferred)
- Hyperemic agent (e.g., adenosine)

Procedure:

- System Setup and Calibration:
 - Place the patient in a supine position.[\[3\]](#)
 - Connect the pressure wire to the console and flush the system.
 - Zero the pressure wire to atmospheric pressure.
- Pressure Equalization:
 - Advance the pressure wire through the guiding catheter so that the pressure sensor is at the tip of the guiding catheter, proximal to the lesion.
 - Equalize the pressure wire reading with the aortic pressure measured through the guiding catheter. The ratio should be 1.0.[\[3\]](#)
- Lesion Assessment:
 - Advance the pressure wire so that the sensor is distal to the stenosis.[\[3\]](#)
 - Induce maximal hyperemia. This is typically achieved with an intravenous infusion of adenosine (140 µg/kg/min) or an intracoronary bolus.[\[3\]](#)
 - Record the lowest stable Pd/Pa ratio during hyperemia. This is the FFR value.
- Interpretation and Decision Making:

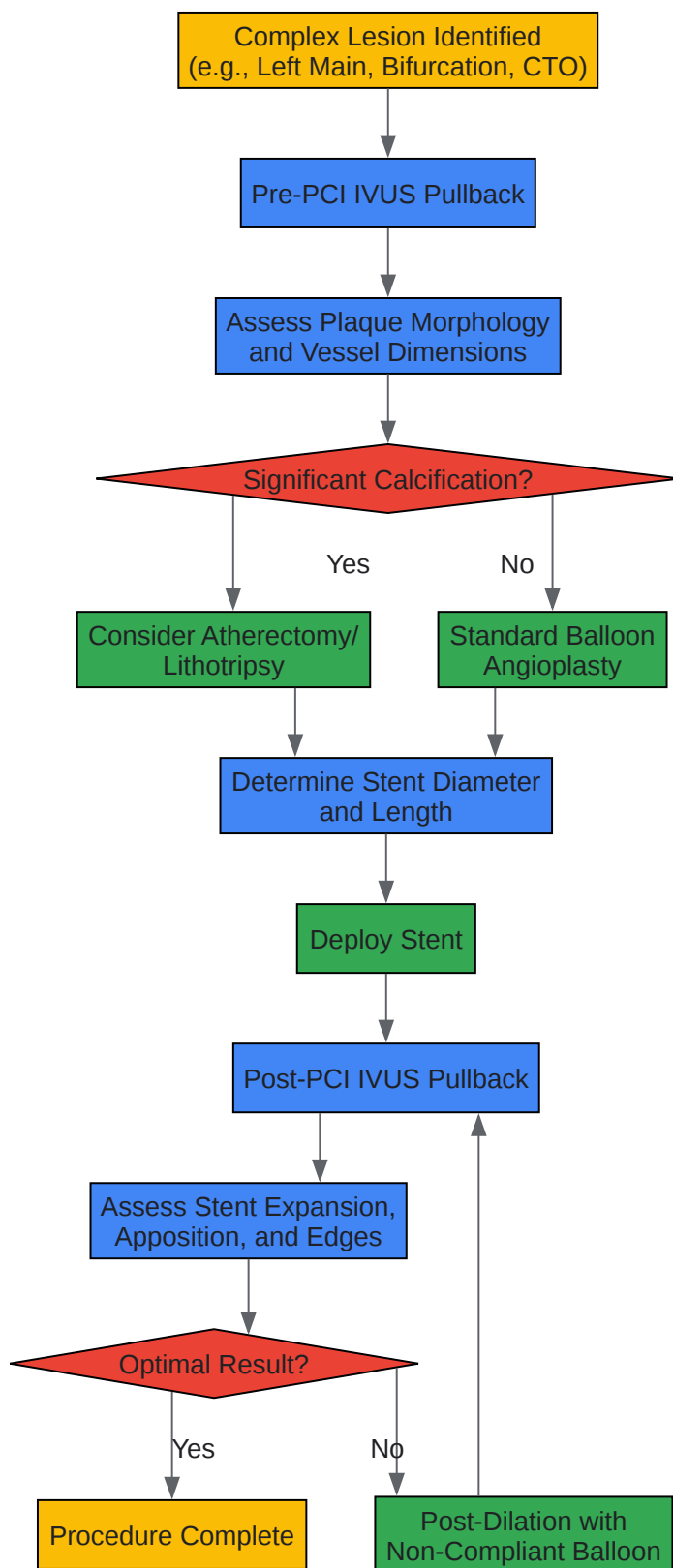
- $\text{FFR} > 0.80$: The stenosis is not hemodynamically significant, and revascularization can likely be deferred.[18]
- $\text{FFR} \leq 0.80$: The stenosis is hemodynamically significant, and revascularization is indicated.[18]
- 0.75 - 0.80: This is a "grey zone," and the decision to intervene should be based on the overall clinical context.[3][18]
- Post-Intervention Assessment (Optional):
 - After stenting, an FFR measurement can be repeated to confirm the restoration of normal blood flow. A post-PCI FFR of >0.90 is associated with better outcomes.[20]

Quantitative Data Summary

FFR Value	Interpretation	Clinical Recommendation	Reference
> 0.80	Not hemodynamically significant	Defer PCI, continue medical therapy	[18][19]
0.75 - 0.80	"Grey Zone"	Consider PCI based on clinical context	[3][18]
≤ 0.75	Hemodynamically significant	Proceed with PCI	[3]
Post-PCI > 0.90	Optimal result	Associated with lower MACE	[20]

Visualizations: Workflows and Pathways

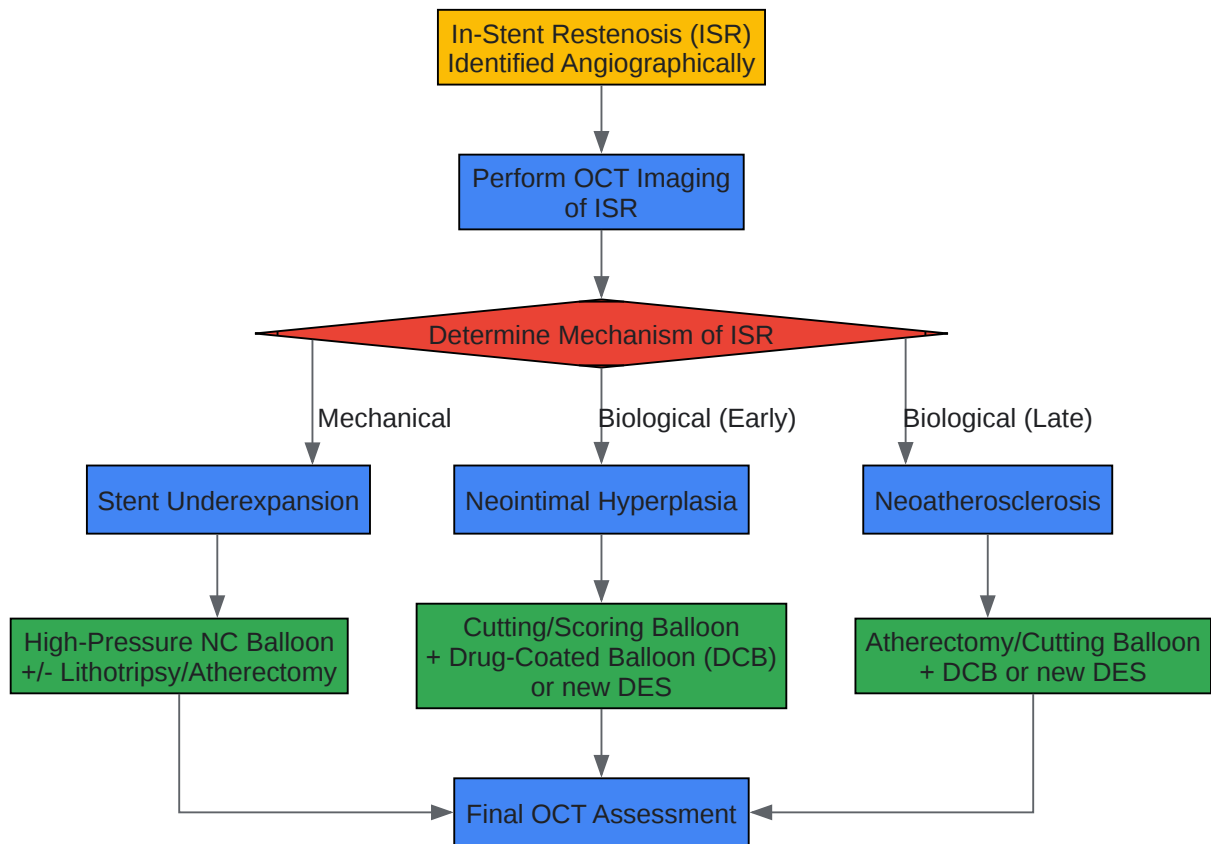
IVUS-Guided Decision Making for Complex Lesions



[Click to download full resolution via product page](#)

Caption: IVUS-guided decision-making workflow for complex coronary lesions.

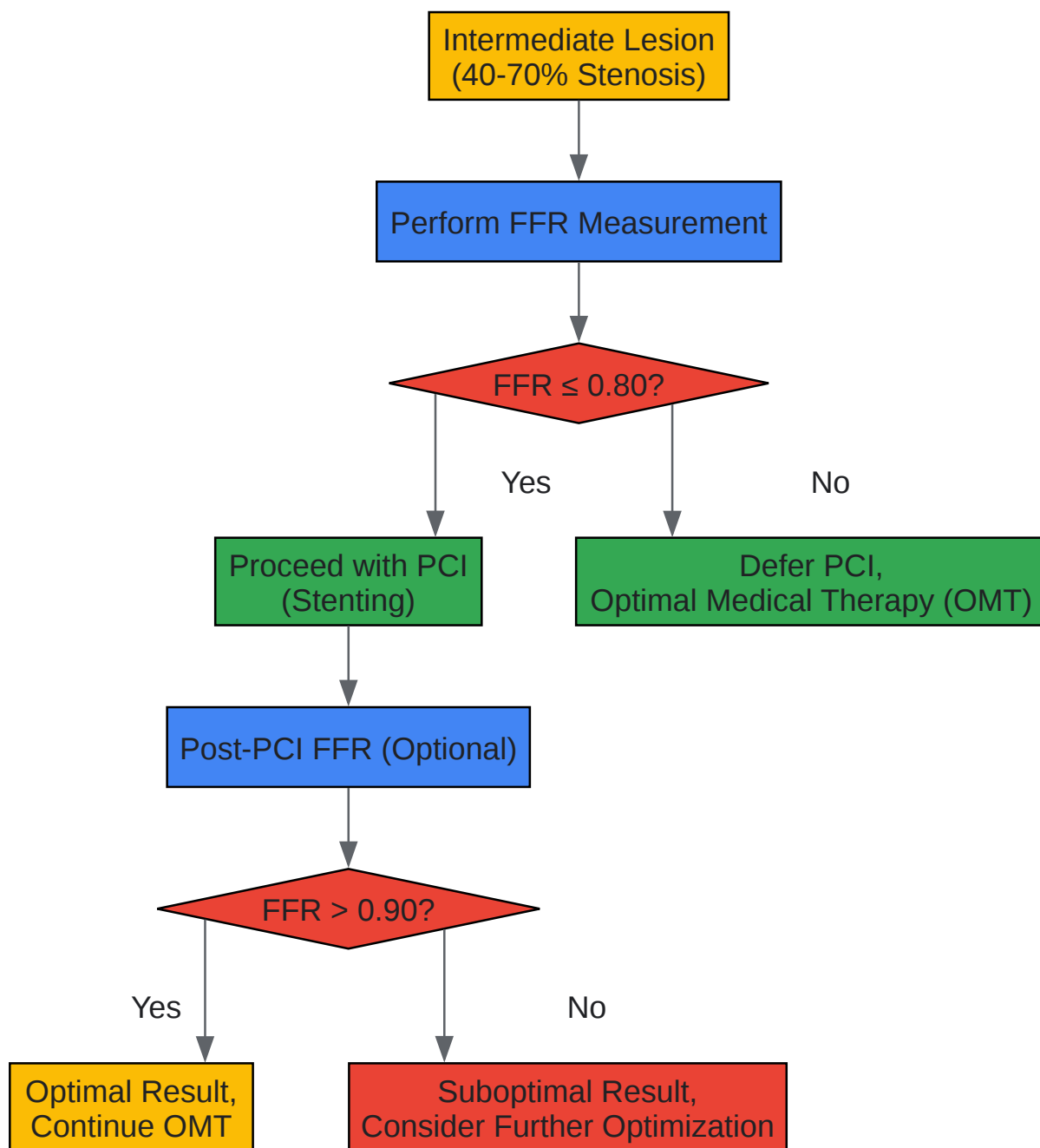
OCT Assessment of In-Stent Restenosis (ISR)



[Click to download full resolution via product page](#)

Caption: OCT-based assessment and treatment pathway for in-stent restenosis.

FFR-Guided Treatment of Intermediate Lesions



[Click to download full resolution via product page](#)

Need Custom Synthesis?

BenchChem offers custom synthesis for rare earth carbides and specific isotopic labeling.

Email: info@benchchem.com or [Request Quote Online](#).

References

- 1. nice.org.uk [nice.org.uk]
- 2. ksc2021.or.kr [ksc2021.or.kr]
- 3. Fractional Flow Reserve (FFR) Measurement Technique: Approach Considerations, Specific Approaches to FFR Measurement, Complications [emedicine.medscape.com]
- 4. Intravascular Ultrasound Guiding Percutaneous Coronary Interventions in Complex Higher Risk-Indicated Patients (CHIPs): Insight from Clinical Evidence - PMC [pmc.ncbi.nlm.nih.gov]
- 5. youtube.com [youtube.com]
- 6. youtube.com [youtube.com]
- 7. Comparison of coronary vessel sizing using coronary angiography versus intravascular ultrasound in Egyptian patients (@cardiometry) - SciUp.org [sciup.org]
- 8. jwatch.org [jwatch.org]
- 9. youtube.com [youtube.com]
- 10. m.youtube.com [m.youtube.com]
- 11. The Role of Optical Coherence Tomography in Coronary Intervention - PMC [pmc.ncbi.nlm.nih.gov]
- 12. When to use intravascular ultrasound or optical coherence tomography during percutaneous coronary intervention? - PMC [pmc.ncbi.nlm.nih.gov]
- 13. OCT Guidance in Bifurcation Percutaneous Coronary Intervention - PMC [pmc.ncbi.nlm.nih.gov]
- 14. acc.org [acc.org]
- 15. eurointervention.pcronline.com [eurointervention.pcronline.com]
- 16. youtube.com [youtube.com]
- 17. pubs.rsna.org [pubs.rsna.org]
- 18. Performing and Interpreting Fractional Flow Reserve Measurements in Clinical Practice: An Expert Consensus Document | ICR Journal [icrjournal.com]
- 19. youtube.com [youtube.com]
- 20. youtube.com [youtube.com]
- To cite this document: BenchChem. [Application Notes and Protocols: Advanced Imaging for PTCA Guidance]. BenchChem, [2025]. [Online PDF]. Available at:

[<https://www.benchchem.com/product/b1218239#advanced-imaging-techniques-for-ptca-guidance-and-assessment>]

Disclaimer & Data Validity:

The information provided in this document is for Research Use Only (RUO) and is strictly not intended for diagnostic or therapeutic procedures. While BenchChem strives to provide accurate protocols, we make no warranties, express or implied, regarding the fitness of this product for every specific experimental setup.

Technical Support: The protocols provided are for reference purposes. Unsure if this reagent suits your experiment? [[Contact our Ph.D. Support Team for a compatibility check](#)]

Need Industrial/Bulk Grade? [Request Custom Synthesis Quote](#)

BenchChem

Our mission is to be the trusted global source of essential and advanced chemicals, empowering scientists and researchers to drive progress in science and industry.

Contact

Address: 3281 E Guasti Rd
Ontario, CA 91761, United States
Phone: (601) 213-4426
Email: info@benchchem.com