

# Addressing image artifacts in Fluorocholine chloride PET/CT scans

**Author:** BenchChem Technical Support Team. **Date:** December 2025

## Compound of Interest

Compound Name: Fluorocholine chloride

Cat. No.: B1215755

[Get Quote](#)

## Technical Support Center: Fluorocholine Chloride PET/CT Imaging

This technical support center provides troubleshooting guidance and answers to frequently asked questions regarding image artifacts in Fluorocholine ( $^{18}\text{F}$ -Choline) chloride PET/CT scans. The information is tailored for researchers, scientists, and drug development professionals to help ensure the acquisition of high-quality, quantifiable data for experimental and clinical applications.

## Frequently Asked Questions (FAQs)

Q1: What are the most common categories of artifacts in PET/CT imaging?

A1: Artifacts in PET/CT can be broadly categorized into three groups: patient-related, instrument-related, and radiotracer-related.[1] Patient-related artifacts, such as motion and the presence of metallic implants, are the most frequently encountered.[2] Instrument-related issues can include detector malfunctions or errors in attenuation correction, while radiotracer-related artifacts might involve issues like extravasation of the injected dose.[1]

Q2: Are there any artifacts or interpretation challenges specific to Fluorocholine?

A2: Yes, due to its biodistribution, Fluorocholine presents unique challenges. High physiological uptake is normally observed in the liver, spleen, pancreas, kidneys, bone marrow, and salivary

glands.[3][4][5] This intense activity, particularly in the liver and urinary bladder, can sometimes mask underlying pathology or create artifacts that mimic disease.[6] For instance, intense bladder activity can obscure the evaluation of the adjacent prostate bed.[6] Additionally, benign conditions like inflammatory processes and certain benign tumors can also show Fluorocholine uptake, leading to potential false-positive findings.[4][7]

Q3: Why is reviewing non-attenuation-corrected (NAC) images important?

A3: Reviewing NAC images is a critical troubleshooting step. While not quantitatively accurate, NAC images are not affected by artifacts originating from the CT-based attenuation correction map.[3] If an area of high uptake is visible on the attenuation-corrected (AC) images but not on the NAC images, it strongly suggests that the finding is an artifact, often caused by high-density materials like metal implants or contrast agents.[3]

Q4: How can patient preparation impact image quality with Fluorocholine?

A4: Patient preparation is crucial for minimizing artifacts from physiological tracer uptake. While fasting has not been shown to significantly reduce gastrointestinal uptake of Fluorocholine, proper hydration and encouraging the patient to void immediately before the scan can help reduce intense activity in the urinary bladder.[2][3] In some protocols, an early scan of the pelvis is performed immediately after tracer injection, before significant urinary excretion occurs, to get a clearer view of the prostatic fossa.[8][9]

## Troubleshooting Guides for Specific Artifacts

### Patient Motion Artifacts

Q: My fused PET/CT images show a misalignment between the PET signal and the anatomical structures on the CT. What causes this and how can I fix it?

A: This is a classic motion artifact, often called misregistration. It occurs because the CT and PET scans are acquired sequentially.[1] Any patient movement between or during these acquisitions can lead to a spatial mismatch of the functional (PET) and anatomical (CT) data.  
[10]

- Causes:

- Voluntary patient movement (e.g., shifting position, moving limbs).[10]
- Involuntary physiological motion (e.g., breathing, cardiac pulsation, peristalsis).[2]
- Patient discomfort during the scan.[11]
- Troubleshooting & Correction:
  - Visual Inspection: Carefully review the separate PET and CT images, as well as the fused images, to confirm misregistration. The misalignment is often most evident near the diaphragm or in the extremities.[10]
  - Image Re-registration: Most modern imaging software includes tools for manual or automated re-registration of the PET and CT datasets. This can often correct for minor to moderate patient movements.[11]
  - Data Re-processing: For respiratory motion, if the data was acquired in a list-mode or 4D-gated fashion, it can be reprocessed to select data from specific phases of the respiratory cycle, which can reduce blurring and improve alignment.[12]
  - Repeat Acquisition: In cases of severe motion artifact that cannot be corrected with software, the scan may need to be repeated.[10]
- Prevention:
  - Patient Communication: Clearly explain the importance of remaining still throughout the entire scan duration.[2]
  - Patient Comfort: Ensure the patient is in a comfortable and stable position before starting the acquisition. Use immobilization devices like straps or cushions when necessary.[11]
  - Respiratory Gating: For thoracic and upper abdominal imaging, use respiratory gating techniques to synchronize data acquisition with the patient's breathing cycle.[12]

## Metallic Implant Artifacts

Q: I am observing bright and dark streaks on my CT scan near a patient's metallic implant, and the corresponding PET image shows areas of artificially high and low uptake. How do I address

this?

A: These are metal artifacts. High-density materials like dental fillings, hip prostheses, or surgical clips severely attenuate the X-rays used for the CT scan. This leads to "photon starvation" and results in streak artifacts on the reconstructed CT image.<sup>[13]</sup> When this erroneous CT data is used for PET attenuation correction, it causes significant over- and underestimation of tracer activity in the surrounding tissues.<sup>[4]</sup>

- Causes:
  - Beam hardening (lower energy X-rays are absorbed more readily by the metal).
  - Photon scattering and noise.<sup>[14]</sup>
  - The CT reconstruction algorithm's inability to handle the incomplete projection data.
- Troubleshooting & Correction:
  - Utilize Metal Artifact Reduction (MAR) Algorithms: Most modern PET/CT scanners are equipped with MAR software. These algorithms identify the metal in the CT image and use various techniques, such as interpolation, to correct the corrupted data before it is used for PET attenuation correction.<sup>[3][14]</sup> Activating this feature during CT reconstruction is the most effective solution.
  - Review Non-Attenuation-Corrected (NAC) Images: As mentioned in the FAQs, the NAC images can help confirm if an area of high uptake is a true finding or a result of the CT artifact.<sup>[3]</sup>
  - Modify CT Acquisition Parameters: In some instances, using a higher tube voltage (kVp) for the CT scan can help reduce the severity of metal artifacts, though this may increase the radiation dose.
- Prevention:
  - Patient Screening: Always inquire about metallic implants during the pre-scan screening process.

- Protocol Optimization: For patients with known metallic implants in the field of view, ensure that a CT protocol incorporating a MAR algorithm is selected prior to the scan.

## Physiological Uptake Artifacts (Bladder, Bowel, Salivary Glands)

Q: There is intense Fluorocholine activity in the patient's bladder, which is making it difficult to evaluate the adjacent tissues. What can be done to mitigate this?

A: Intense urinary excretion of Fluorocholine is a known challenge that can obscure nearby structures like the prostate or lymph nodes.[\[6\]](#)

- Causes:
  - Fluorocholine and its metabolites are excreted via the urinary tract.[\[9\]](#)
- Troubleshooting & Mitigation:
  - Patient Hydration and Voiding: Ensure the patient is well-hydrated before the scan and instruct them to void immediately before the PET acquisition begins. This helps to dilute the tracer concentration in the bladder and reduce overall activity.[\[15\]](#)
  - Early Pelvic Imaging: Acquire a short, static PET scan of the pelvis immediately after tracer injection (e.g., 1-4 minutes post-injection). At this early time point, there is minimal tracer accumulation in the bladder, providing a clearer view of the prostate bed.[\[8\]](#)[\[15\]](#)
  - Delayed Imaging: In some cases, acquiring additional delayed images of the pelvis after the patient has voided again can be helpful.
  - Pharmacological Intervention: The use of a diuretic agent like furosemide can help increase the clearance of the tracer from the urinary system, although this must be done according to a validated protocol.[\[7\]](#)

Q: I see variable and sometimes intense Fluorocholine uptake in the bowel and salivary glands. How can I differentiate this from pathological uptake?

A: Physiological uptake in the bowel and salivary glands is normal for Fluorocholine.[5] The key is to distinguish this from malignant lesions.

- Bowel Uptake:
  - Appearance: Often diffuse or segmental and follows the anatomical course of the intestines. It can be variable due to peristalsis.
  - Mitigation: While fasting has not been proven to eliminate gut activity, ensuring the patient has not eaten a large meal immediately before the scan may be beneficial.[3] Careful correlation with the CT scan is essential to distinguish luminal activity from lymph node uptake.
- Salivary Gland Uptake:
  - Appearance: Typically symmetric and intense uptake in the parotid and submandibular glands is expected.[5]
  - Troubleshooting: Asymmetry or focal uptake within a gland that corresponds to a palpable nodule or a suspicious lesion on CT should be investigated further. However, benign salivary gland tumors can also show increased uptake.[16] A thorough clinical history and correlation with other imaging modalities are crucial.

## Quantitative Data Summaries

The following tables summarize the quantitative impact of artifact correction techniques. Note that much of the published data is for  $^{18}\text{F}$ -FDG or  $^{68}\text{Ga}$ -PSMA; while the principles are applicable to  $^{18}\text{F}$ -Choline, the exact quantitative impact may vary.

Table 1: Impact of Metal Artifact Reduction (iMAR) on PET Quantification

Parameter	Condition	SUV Change	Confidence in Interpretation	Reference
<sup>18</sup> F-FDG Concentration	Phantom with hip prosthesis, cold artifact	30% deficit restored	N/A	<a href="#">[13]</a>
Lesion SUVmean	Patient scans ( <sup>18</sup> F-FDG & <sup>68</sup> Ga-PSMA)	Mean absolute difference of 3.5% ± 3.3%	Average improvement of 28% ± 20%	<a href="#">[13]</a>

Table 2: Impact of Respiratory Motion on SUVmax

Lesion Location	Motion Correction Method	Average Increase in SUVmax	Reference
Lung (Lower Region)	Deep-Inspiration Breath-Hold vs. Free-Breathing	Up to 51.8%	<a href="#">[17]</a>
Thoracic Tumors	Amplitude Gating vs. Ungated	27%	<a href="#">[13]</a>
Phantom (1-mL lesion)	Gating for average respiratory motion	30% recovery	<a href="#">[18]</a>
Phantom (1-mL lesion)	Gating for maximal respiratory motion	48% recovery	<a href="#">[18]</a>

## Detailed Experimental Protocols

### Protocol 1: Patient Preparation for Minimizing Bladder and Bowel Artifacts

- **Patient Communication:** Inform the patient about the entire procedure, including the importance of hydration and voiding.
- **Dietary Instructions:** While extended fasting is not definitively required, instruct the patient to avoid foods high in choline for 12-24 hours before the scan and to fast for at least 4-6 hours

prior to the tracer injection.[9]

- Hydration: Encourage the patient to drink approximately 1 liter of water, starting 1-2 hours before the scheduled injection time.
- Pre-Injection Voiding: Ask the patient to empty their bladder completely just before the Fluorocholine injection.
- Tracer Administration: Administer the  $^{18}\text{F}$ -Choline dose via intravenous injection.
- Uptake Period: The standard uptake period is typically 40-60 minutes. During this time, the patient should rest comfortably and avoid significant movement.
- Pre-Scan Voiding: Instruct the patient to void their bladder again immediately before being positioned on the scanner bed.[15] This is the most critical step for reducing bladder activity on the primary whole-body scan.

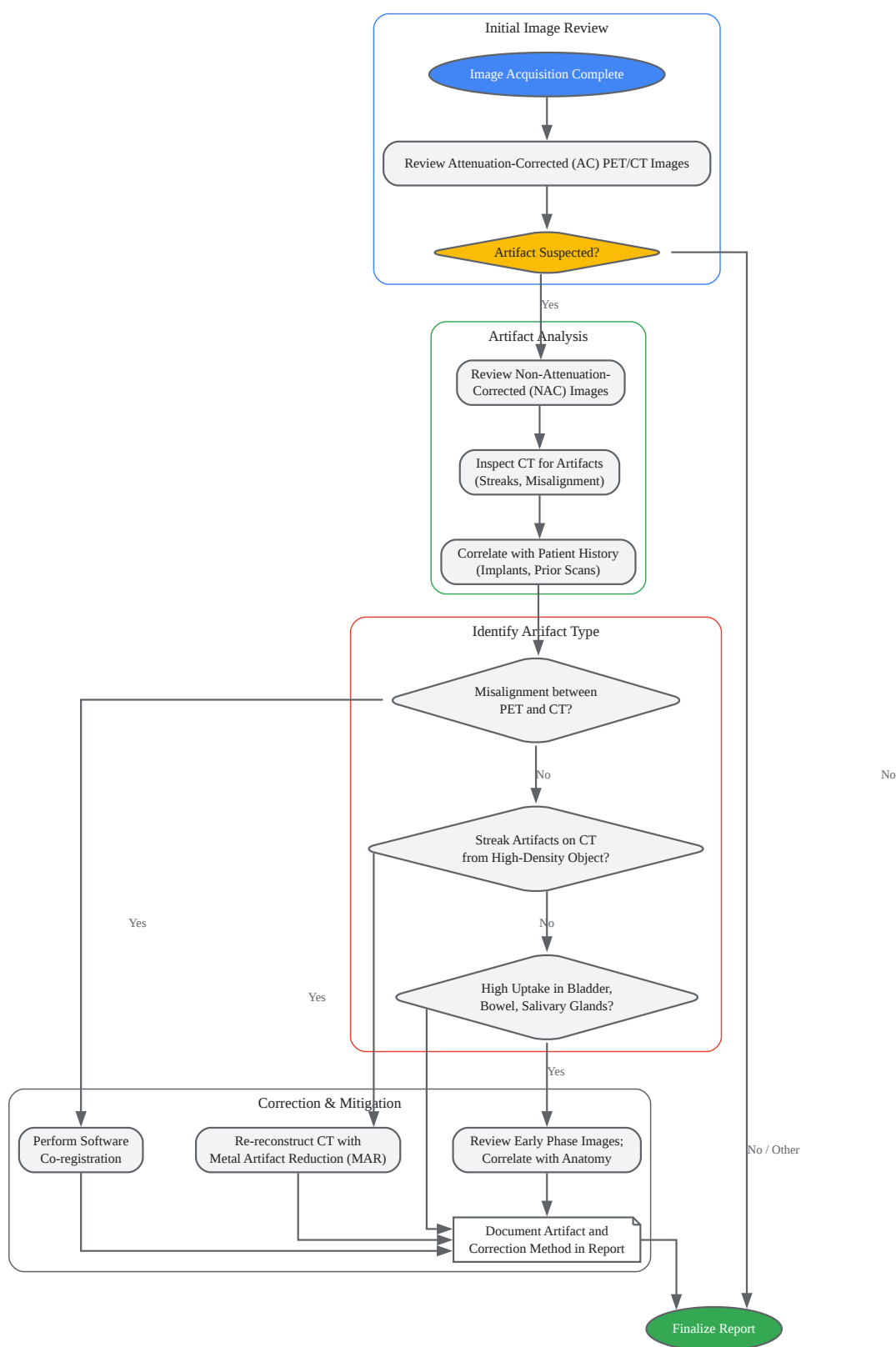## Protocol 2: Respiratory Gating Workflow for Thoracic/Upper Abdominal Scans

- Patient Setup: Position the patient comfortably on the PET/CT scanner bed. Place the respiratory tracking device (e.g., a pressure-sensitive belt or an infrared camera with a marker block) on the patient's abdomen or chest.
- Monitor Breathing: Observe the patient's breathing pattern on the monitoring console to ensure it is stable and regular.
- Acquire Gated CT: Perform a low-dose helical CT scan for attenuation correction. The respiratory tracking system records the breathing waveform simultaneously.
- Acquire Gated PET: Start the PET acquisition in list mode, which records each detected event with its precise timing and location information. The respiratory tracking system continues to record the breathing waveform and sends trigger signals to the PET scanner.
- Data Binning: Post-acquisition, the software uses the respiratory waveform to sort the PET list-mode data into a number of "bins" or "gates," each corresponding to a specific phase of the respiratory cycle (e.g., end-inspiration, end-expiration).[12]



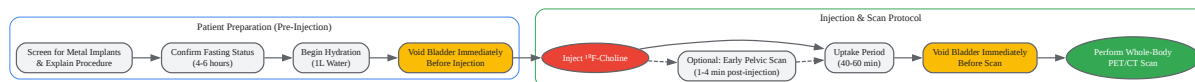
- **Image Reconstruction:** Reconstruct the PET images for each gate separately. This creates a 4D PET dataset. A single, motion-corrected 3D image can be generated by selecting a specific gate (e.g., the end-expiration phase, where motion is minimal) or by using algorithms that re-align and sum the data from multiple gates.

## Visualizations: Workflows and Logical Relationships



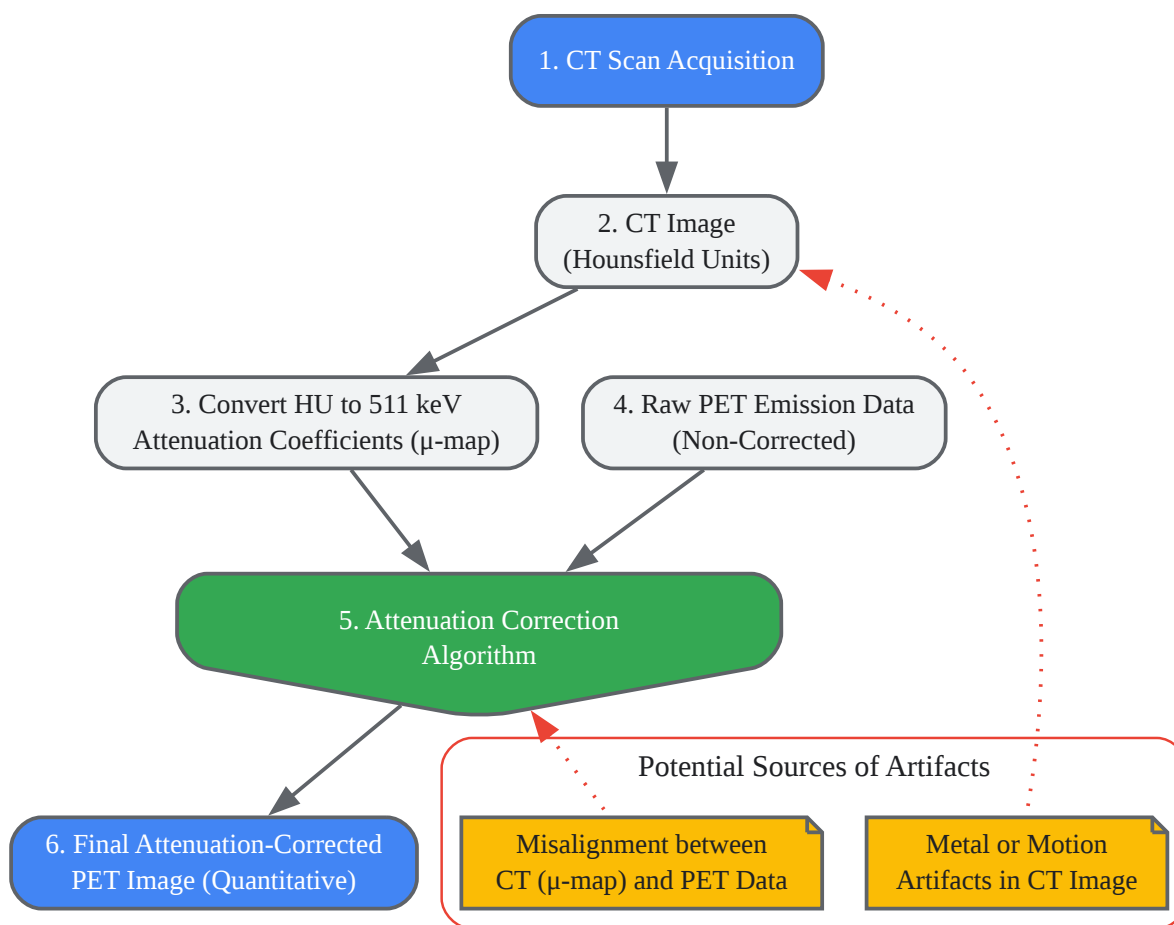
[Click to download full resolution via product page](#)

Caption: A decision-making workflow for identifying and addressing common image artifacts.



[Click to download full resolution via product page](#)

Caption: Optimized patient workflow to minimize physiological uptake artifacts.



[Click to download full resolution via product page](#)

Caption: Principle of CT-based attenuation correction and sources of error.

**Need Custom Synthesis?**

BenchChem offers custom synthesis for rare earth carbides and specific isotopic labeling.

Email: [info@benchchem.com](mailto:info@benchchem.com) or [Request Quote Online](#).

## References

- 1. hug.ch [hug.ch]
- 2. Guidelines for quality control of PET/CT scans in a multicenter clinical study - PMC [pmc.ncbi.nlm.nih.gov]
- 3. Impact of fasting on 18F-fluorocholine gastrointestinal uptake and detection of lymph node metastases in patients with prostate cancer - PMC [pmc.ncbi.nlm.nih.gov]
- 4. youtube.com [youtube.com]
- 5. Impact of time-of-flight PET on quantification accuracy and lesion detection in simultaneous 18F-choline PET/MRI for prostate cancer - PubMed [pubmed.ncbi.nlm.nih.gov]
- 6. Respiratory Gating and the Performance of PET/CT in Pulmonary Lesions - PMC [pmc.ncbi.nlm.nih.gov]
- 7. Frontiers | Normal Variants, Pitfalls, and Artifacts in Ga-68 Prostate Specific Membrane Antigen (PSMA) PET/CT Imaging [frontiersin.org]
- 8. jnm.snmjournals.org [jnm.snmjournals.org]
- 9. art.torvergata.it [art.torvergata.it]
- 10. Quality Control in SPECT and PET Imaging | Thoracic Key [thoracickey.com]
- 11. Imaging of prostate cancer with PET/CT using 18F-Fluorocholine - PMC [pmc.ncbi.nlm.nih.gov]
- 12. DOT Language | Graphviz [graphviz.org]
- 13. Implementation of an Automated Respiratory Amplitude Gating Technique for PET/CT: Clinical Evaluation - PMC [pmc.ncbi.nlm.nih.gov]
- 14. jnm.snmjournals.org [jnm.snmjournals.org]
- 15. New Acquisition Protocol of 18F-Choline PET/CT in Prostate Cancer Patients: Review of the Literature about Methodology and Proposal of Standardization - PMC [pmc.ncbi.nlm.nih.gov]

- 16. Imaging of prostate cancer with PET/CT using (18)F-Fluorocholine - PubMed [pubmed.ncbi.nlm.nih.gov]
- 17. The impact of respiratory motion on tumor quantification and delineation in static PET/CT imaging - PMC [pmc.ncbi.nlm.nih.gov]
- 18. mdpi.com [mdpi.com]
- To cite this document: BenchChem. [Addressing image artifacts in Fluorocholine chloride PET/CT scans]. BenchChem, [2025]. [Online PDF]. Available at: [https://www.benchchem.com/product/b1215755#addressing-image-artifacts-in-fluorocholine-chloride-pet-ct-scans]

---

### Disclaimer & Data Validity:

The information provided in this document is for Research Use Only (RUO) and is strictly not intended for diagnostic or therapeutic procedures. While BenchChem strives to provide accurate protocols, we make no warranties, express or implied, regarding the fitness of this product for every specific experimental setup.

**Technical Support:** The protocols provided are for reference purposes. Unsure if this reagent suits your experiment? [[Contact our Ph.D. Support Team for a compatibility check](#)]

**Need Industrial/Bulk Grade?** [Request Custom Synthesis Quote](#)

## BenchChem

Our mission is to be the trusted global source of essential and advanced chemicals, empowering scientists and researchers to drive progress in science and industry.

### Contact

Address: 3281 E Guasti Rd  
Ontario, CA 91761, United States  
Phone: (601) 213-4426  
Email: [info@benchchem.com](mailto:info@benchchem.com)